This is a digital copy of a book that was preserved for generations on library shelves before it was carefully scanned by Google as part of a project to make the world's books discoverable online.

It has survived long enough for the copyright to expire and the book to enter the public domain. A public domain book is one that was never subject to copyright or whose legal copyright term has expired. Whether a book is in the public domain may vary country to country. Public domain books are our gateways to the past, representing a wealth of history, culture and knowledge that's often difficult to discover.

Marks, notations and other marginalia present in the original volume will appear in this file - a reminder of this book's long journey from the publisher to a library and finally to you.

Usage guidelines

Google is proud to partner with libraries to digitize public domain materials and make them widely accessible. Public domain books belong to the public and we are merely their custodians. Nevertheless, this work is expensive, so in order to keep providing this resource, we have taken steps to prevent abuse by commercial parties, including placing technical restrictions on automated querying.

We also ask that you:

+ *Make non-commercial use of the files* We designed Google Book Search for use by individuals, and we request that you use these files for personal, non-commercial purposes.
+ *Refrain from automated querying* Do not send automated queries of any sort to Google's system: If you are conducting research on machine translation, optical character recognition or other areas where access to a large amount of text is helpful, please contact us. We encourage the use of public domain materials for these purposes and may be able to help.
+ *Maintain attribution* The Google "watermark" you see on each file is essential for informing people about this project and helping them find additional materials through Google Book Search. Please do not remove it.
+ *Keep it legal* Whatever your use, remember that you are responsible for ensuring that what you are doing is legal. Do not assume that just because we believe a book is in the public domain for users in the United States, that the work is also in the public domain for users in other countries. Whether a book is still in copyright varies from country to country, and we can't offer guidance on whether any specific use of any specific book is allowed. Please do not assume that a book's appearance in Google Book Search means it can be used in any manner anywhere in the world. Copyright infringement liability can be quite severe.

About Google Book Search

Google's mission is to organize the world's information and to make it universally accessible and useful. Google Book Search helps readers discover the world's books while helping authors and publishers reach new audiences. You can search through the full text of this book on the web at `http://books.google.com/`

PROPERTY OF THE
PUBLIC LIBRARY OF THE
CITY OF BOSTON,
DEPOSITED IN THE
BOSTON MEDICAL LIBRARY

PROPERTY OF THE
PUBLIC LIBRARY OF THE
CITY OF BOSTON,
DEPOSITED IN THE
BOSTON MEDICAL LIBRARY

THE FRANCIS A. COUNTWAY LIBRARY OF MEDICINE
HARVARD MEDICAL LIBRARY-BOSTON MEDICAL LIBRARY

TRANSACTIONS

OF THE

PATHOLOGICAL SOCIETY OF LONDON.

VOLUME THE FORTY-SEVENTH.

THE FRANCIS A. COUNTWAY
LIBRARY OF MEDICINE
BOSTON, MA

NOV 04 2003

COMPRISING THE REPORT OF THE PROCEEDINGS FOR THE SESSION 1895–96.

LONDON:
SMITH, ELDER & CO., 15, WATERLOO PLACE.
1896.

September 3. 1897.
6
1 Cent.

Y 7716.3
OM.47

THE present publication, being the Forty-seventh Volume of Transactions, constitutes the Fiftieth published Annual Report of the Pathological Society's Proceedings.

The COUNCIL think it right to repeat that the exhibitors are alone responsible for the descriptions given of the Specimens exhibited by them, the only change made in the Reports furnished by the authors being such verbal alterations as were absolutely necessary.

20, HANOVER SQUARE, W.;
December, 1896.

PUBLIC LIBRARY
OF THE
CITY OF BOSTON

TABLE OF CONTENTS

OF VOLUME XLVII.

	PAGE
List of Presidents of the Society	iv
List of Officers and Members for 1896–97	v
Annual Report of Council for 1895–96	xxix
List of Specimens Exhibited during the Session 1895–96	xxxiii
List of Specimens Reported on by the Committee on Morbid Growths	xlii
List of Plates	xliii
List of Figures in the Text	xliv
Diseases etc., of the Nervous System	1
Diseases, etc., of the Organs of Respiration	5
Diseases, etc., of the Organs of Circulation	14
Diseases, etc., of the Organs of Digestion	34
Diseases of the Genito-urinary Organs	113
Diseases, etc., of the Organs of Locomotion	174
Diseases, etc., of the Ductless Glands	228
Diseases, etc., of the Skin	240
Morbid Growths	246
Miscellaneous Communications	312
Index	412

Presidents of the Society.

ELECTED

1846 CHARLES J. B. WILLIAMS, M.D., F.R.S.
1848 CHARLES ASTON KEY.
1850 PETER MERE LATHAM, M.D.
1852 CÆSAR H. HAWKINS, F.R.S.
1853 BENJAMIN GUY BABINGTON, M.D., F.R.S.
1855 JAMES MONCRIEFF ARNOTT, F.R.S.
1857 SIR THOMAS WATSON, BART., M.D., F.R.S.
1859 SIR WILLIAM FERGUSSON, BART., F.R.S.
1861 JAMES COPLAND, M.D., F.R.S.
1863 SIR PRESCOTT G. HEWETT, BART., F.R.S.
1865 THOMAS BEVILL PEACOCK, M.D.
1867 SIR JOHN SIMON, K.C.B., D.C.L., F.R.S.
1869 SIR RICHARD QUAIN, BART., M.D., LL.D., F.R.S.
1871 JOHN HILTON, F.R.S.
1873 SIR WILLIAM JENNER, BART., M.D., K.C.B., D.C.L., F.R.S.
1875 GEORGE D. POLLOCK.
1877 CHARLES MURCHISON, M.D., LL.D., F.R.S.
1879 JONATHAN HUTCHINSON, F.R.S.
1881 SAMUEL WILKS, M.D., F.R.S.
1883 JOHN WHITAKER HULKE, F.R.S.
1885 JOHN SYER BRISTOWE, M.D., F.R.S.
1887 SIR JAMES PAGET, BART., D.C.L., LL.D., F.R.S.
1889 WILLIAM HOWSHIP DICKINSON, M.D.
1891 SIR GEORGE MURRAY HUMPHRY, M.D., LL.D., F.R.S.
1893 FREDERICK WILLIAM PAVY, M.D., LL.D., F.R.S.
1895 HENRY TRENTHAM BUTLIN, D.C.L.

OFFICERS AND COUNCIL

OF THE

Pathological Society of London,

ELECTED AT

THE GENERAL MEETING, MAY 19TH, 1896,

FOR THE SESSION 1896–97.

President.

HENRY TRENTHAM BUTLIN, D.C.L., F.R.C.S.

Vice-Presidents.

WILLIAM RICHARD GOWERS, M.D.
NORMAN MOORE, M.D.
SEYMOUR SHARKEY, M.D.
SAMUEL WEST, M.D.
ARTHUR E. J. BARKER.
FREDERIC S. EVE.
SAMUEL G. SHATTOCK.
FREDERICK TREVES.

Treasurer.

SIDNEY COUPLAND, M.D.

Council.

JULIUS DRESCHFELD, M.D.
W. P. HERRINGHAM, M.D.
A. A. KANTHACK, M.D.
HECTOR MACKENZIE, M.D.
H. MONTAGUE MURRAY, M.D.
G. NEWTON PITT, M.D.
H. D. ROLLESTON, M.D.
C. S. SHERRINGTON, M.D.
F. CHARLEWOOD TURNER, M.D.
A. F. VOELCKER, M.D.
GILBERT BARLING, M.B.
JAMES BERRY, M.B.
ANTHONY BOWLBY.
E. HURRY FENWICK.
C. E. LEOPOLD B. HUDSON.
RAYMOND JOHNSON.
STEPHEN PAGET.
BILTON POLLARD, M.B.
H. BETHAM ROBINSON, M.S.
W. G. SPENCER, M.S.

Honorary Secretaries.

J. H. TARGETT, M.S. | RICHARD G. HEBB, M.D.

Trustees.

SIR RICHARD QUAIN, BART., M.D., F.R.S.
SAMUEL WILKS, M.D., F.R.S.

Members of the Morbid Growths Committee.

RICHARD G. HEBB, M.D.
A. A. KANTHACK, M.D.
NORMAN MOORE, M.D.
GEORGE NEWTON PITT, M.D.
HUMPHRY D. ROLLESTON, M.D.
HOWARD HENRY TOOTH, M.D.
ANTHONY A. BOWLBY.
W. WATSON CHEYNE.
SAMUEL G. SHATTOCK.
W. G. SPENCER, M.S.
JAMES HENRY TARGETT, M.S.

*** *Members are requested to inform the Secretaries of any corrections which may be necessary.*

LIST OF MEMBERS OF THE SOCIETY.

Honorary Members.

BOUCHARD, C., M.D., Professor of General Pathology, Paris.

CHAUVEAU, A., M.D., Professor of Physiology at the Medical School of Lyons.

JENNER, SIR WILLIAM, Bart., M.D., K.G.C.B., D.C.L., LL.D., F.R.S., Greenwood, Bishop's Waltham, Hants.

KOCH, R., M.D., Director of Institute for Infective Diseases, Berlin.

METCHNIKOFF, E., M.D., Directeur de l'Institut Pasteur, Paris.

RINDFLEISCH, EDOUARD, M.D., Professor of Pathological Anatomy in the University of Bonn.

SIMON, SIR JOHN, K.C.B., D.C.L., LL.D., F.R.S., 40, Kensington-square, W.

VIRCHOW, RUDOLF, M.D., Professor of Pathological Anatomy in the University of Berlin.

WELCH, W. H., M.D., Professor of Pathology, Johns Hopkins University.

ZIEGLER, E., M.D. Professor of Pathological Anatomy, Freiburg.

EXPLANATION OF ABBREVIATIONS.

O.M.—Original Member.
Pres.—President.
T.—Treasurer.
V.-P.—Vice-President.
S.—Secretary.
C.—Member of Council.

The surnames of Members who have compounded for their subscriptions are printed in this type (TYPE). The surnames of Members who have paid the Composition Fee for the 'Transactions' are printed in this type (**Type**).

GENERAL LIST OF MEMBERS.

Elected

1891 ABBOTT, FRANCIS CHARLES, M.D. St. Thomas's Hospital Medical School, S.E.

1879 ABERCROMBIE, JOHN, M.D., 23, Upper Wimpole-street, W.

1885 ABRAHAM, PHINEAS S., M.A., M.D., 2, Henrietta Street, W.

1896 ABRAHAMS, BERTRAM LOUIS, B.Sc., M.B., 14, Welbeck-street, W.

1858 ACLAND, Sir HENRY WENTWORTH, Bart., K.C.B., M.D., F.R.S., Broad-street, Oxford.

1883 ACLAND, THEODORE DYKE, M.D., 74, Brook-street, W. (C. 1892-4.)

1891 ADAMI, J. GEORGE, M.A., M.D., Montreal, Canada.

1890 ADAMS, JAMES, 4, Chiswick-place, Eastbourne.

O.M. ADAMS, WILLIAM, 7, Loudoun-road, St. John's Wood, N.W. (C. 1851-4. V.-P. 1867-9.)

1848 AIKIN, CHARLES A., 12, Ladbroke-terrace, W. (C. 1864-6.)

1872 AIKIN, CHARLES EDMUND, 12, Ladbroke-terrace, W.

1882 ALLCHIN, WILLIAM HENRY, M.D., 5, Chandos-street, W.

1884 ANDERSON, ALEXANDER RICHARD, 5, East Circus-street, Nottingham.

1871 ANDERSON, WILLIAM, 2, Harley-street, W. (C. 1888-90.)

1863 ANDREW, JAMES, M.D., Branksome-avenue, West Bournemouth, Hants. (C. 1868-70. V.-P. 1889-90.)

1887 ARKLE, CHARLES, M.D., 66, Wimpole-street, W.

1883 ASHBY, HENRY, M.D., 13, St. John-street, Manchester.

1863 BAGSHAWE, FREDERICK, M.A., M.D., 35, Warrior-square, St. Leonard's-on-Sea.

1856 Balding, DANIEL BARLEY, Royston, Herts.

1881 BALLANCE, CHARLES A., M.S., 106, Harley-street, W. (C. 1890-2.)

1875 BARKER, ARTHUR E. J., 87, Harley-street, W. (C. 1884-6. V.P. 1896—.)

1885 BARLING, GILBERT, M.B., 85, Edmund-street, Birmingham. (C. 1894—.)

1874 BARLOW, THOMAS, M.D., B.S., 10, Wimpole-street, W. (C. 1879-81. V.-P. 1894-6.)

1877 BARROW, A. BOYCE, 37, Wimpole-street, W.

1881 BARRS, ALFRED GEORGE, M.D., 22, Park-place, Leeds.

1853 BARWELL, RICHARD, 55, Wimpole-street, W. (C. 1862-4. V.-P. 1889-90.)

1861 BASTIAN, H. CHARLTON, M.A., M.D., F.R.S., 8A, Manchester-square, W. (C. 1869-71. V.-P. 1885-7.)

1877 BATEMAN, ARTHUR W., B.A., Tenterfield, New South Wales.

Elected

1895 BATTEN, FREDERICK E., M.D., 124, Harley-street, W.

1876 **BATTESON**, JOHN, 157, Goldhawk-road, W.

1882 BATTLE, WILLIAM HENRY, 2, Mansfield-street, W.

1870 BÄUMLER, CHRISTIAN G. H., M.D., University of Erlangen.

1874 BEACH, FLETCHER, M.B., 64, Welbeck-street, W., and Winchester House, Kingston Hill, Surrey.

1892 BEADLES, CECIL F., Colney Hatch Lunatic Asylum, N.

1879 BEALE, EDWIN CLIFFORD, M.B., 23, Upper Berkeley-street, W.

1852 **BEALE**, LIONEL S., M.B., F.R.S., 61, Grosvenor-street, W. (C. 1858-9. V.-P. 1874-5.)

1856 BEALEY, ADAM, M.D., M.A., Felsham Lodge, Hollington-park, St. Leonard's-on-Sea.

1865 BEEBY, WALTER, M.D., Bromley, Kent.

1880 **BEEVOR**, CHARLES EDWARD, M.D., 33, Harley-street, W. (C. 1888-90.)

1886 BENNETT, FREDERICK JOSEPH, 24, George-street, Hanover-square, W.

1877 BENNETT, WILLIAM HENRY, 1, Chesterfield-street, W. (C. 1891-93.)

1889 BENTLEY, ARTHUR, J. M., M.D., Mena House, Pyramids, Cairo, Egypt.

1878 BERNARD, FRANCIS R., M.D., 45, Warwick-street, Worthing.

1882 BERRIDGE, WILLIAM ALFRED, Redhill, Surrey.

1886 BERRY, JAMES, 60, Welbeck-street, W. (C. 1895—.)

1891 BEVILLE, FREDERICK WELLS, The Firs, Palace-road, East Molesey.

1856 **Bickersteth**, EDWARD R., 2, Rodney-street, Liverpool.

1882 BINDLEY, PHILIP HENRY, M.B., Branksome-road, St. Leonard's-on-Sea.

1890 BINDLEY, ROBERT ALFRED, M.B., Westbury House, Harlesden, N.W.

1878 BINDON, WILLIAM JOHN VEREKER, M.D., 18, St. Ann's-street, Manchester.

1850 **BIRKETT**, EDMUND LLOYD, M.D., Westbourne Rectory, Emsworth, Hampshire. (C. 1856-7.)

1881 BISS, CECIL YATES, M.D., 135, Harley-street, W.

1865 BISSHOPP, JAMES, Mount Pleasant, Tunbridge Wells.

1889 BLACK, ROBERT, M.D., 6, Pavilion Parade, Brighton.

1850 BLAGDEN, ROBERT, 15, Oxberry-avenue, Fulham.

1863 BLANCHET, JEAN B., M.D., M.S., Montreal, Quebec, Canada.

1879 BOILEAU, J. P. H., M.D., Brigade-Surgeon, Army.

1876 BOND, THOMAS, M.B., 7, Broad Sanctuary, Westminster, S.W.

1869 BOURNE, WALTER, M.D. (Travelling).

1861 BOWER, RICHARD NORRIS (Travelling).

1881 BOWLBY, ANTHONY A., 24, Manchester-square, W. (C. 1886-8, 1895—. S. 1893-4.)

1895 BOX, CHARLES R., M.D., St. Thomas's Hospital, S.E.

1892 BOYCE, RUBERT WILLIAM, M.B., University College, Liverpool.

1882 BOYD, STANLEY, M.B., 134, Harley-street, W. (C. 1893-6.)

1889 BRADFORD, JOHN ROSE, M.D., F.R.S., 52, Upper Berkeley-street, W.

1880 BRAMWELL, BYROM, M.D., 23, Drumsheugh-gardens West, Edinburgh.

1889 BREDIN, J. NOBLE, Linden Lodge, Potton, Beds.

1877 BRIDGES, ROBERT, M.B., M.A., Manor House, Yattendon, Berks.

Elected

1867 **Bridgewater**, THOMAS, LL.D. Glas., M.B. Lond., Harrow-on-the-Hill, Middlesex.

1873 BRIGGS, JACOB MYERS, M.D., Coeymans, New York, U.S.A.

1868 BRIGHT, GEORGE CHARLES, M.D., Cannes, Alpes Maritimes, France.

1857 BRISCOE, JOHN, 5, Broad-street, Oxford.

1885 BRISCOE, JOHN F., Westbrooke House, Alton, Hants.

1860 **BROADBENT**, Sir WILLIAM HENRY, Bart., M.D., 84, Brook-street, W. (C. 1871-3. V.P. 1882-4.)

1886 BROCKATT, ANDREW ALEXANDER, Hazeldean, Malvern.

1852 **BRODHURST**, BERNARD E., 21, Portland-place, W. (C. 1862-4.)

1884 BRODIE, CHARLES GORDON, Fernhill, Wootton Bridge, Isle of Wight.

1863 BRODIE, GEORGE BERNARD, M.D., 3, Chesterfield-street, Mayfair, W.

1865 **BROWN**, AUGUSTUS, M.D., Felsberg, Wilton Road, Shanklin, I.W.

1871 BROWN, FREDERICK GORDON, 17, Finsbury-circus, E.C.

1866 **BROWNE**, LENNOX, 15, Mansfield-street, W.

1877 BRUCE, J. MITCHELL, M.D., 23, Harley-street, W.

1890 BRUNTON, T. LAUDER, M.D., D.Sc., LL.D., F.R.S., 10, Stratford-place, W.

1855 **BRYANT**, THOMAS, 65, Grosvenor-street, W. (C. 1863-6. V.-P. 1877-9.)

1894 BUCHANAN, GEORGE SEATON, M.D., 27, Woburn-square, W.C.

1890 BUCKLAND, FRANCIS O., M.A., M.B., C.M., 6, Lower Sloane-street, S.W.

1891 BURGHARD, FREDERIC FRANÇOIS, M.D., M.S., 46, Weymouth-street, W.

1880 BURTON, SAMUEL HERBERT, M.B., Norfolk and Norwich Hospital, Norwich.

1887 BUTLER-SMYTHE, ALBERT CHARLES, 76, Brook-street, W.

1872 BUTLIN, HENRY TRENTHAM, D.C.L. (PRESIDENT), 82, Harley-street, W. (C. 1876-8, 1887-9. S. 1884-6. V.-P. 1891-2. P. 1895—.)

1883 **BUXTON**, DUDLEY W., M.D., 82, Mortimer-street, W.

1856 **BUZZARD**, THOMAS, M.D., 74, Grosvenor-street, W. (C. 1869-70. V.-P. 1881-3.)

1893 CADDY, DUNCAN JAMES, M.D., 4, Earl's Court-gardens, S.W. (Travelling.)

1885 CAHILL, JOHN, 12, Seville-street, Lowndes-square, S.W.

1893 CALEY, HENRY ALBERT, M.D., 24, Upper Berkeley-street, W.

1897 CALVERT, JAMES, M.D., 36, Queen Anne-street, W.

1892 CAMPBELL, HENRY JOHNSTONE, M.D., 36, Manningham-lane, Bradford.

1891 CARLESS, ALBERT, M.S., 10, Welbeck-street, W.

1891 CARR, JOHN WALTER, M.D., 19, Cavendish-place, W.

1876 CARTER, ROBERT BRUDENELL, 31, Harley-street, W.

1877 CASSON, JOHN HORNSEY, Teheran, Persia.

1868 **CAVAFY**, JOHN, M.D., 2, Upper Berkeley-street, W. (C. 1881-3.)

1864 CAY, CHARLES VIDLER, Deputy Surgeon-General, 25, Newton-place, Glasgow.

1863 CAYLEY, WILLIAM, M.D., 27, Wimpole-street, W. (C. 1870-1, 1875-8. S. 1872-4. V.-P. 1884-6. T. 1888-93.)

Elected

1869 CHAFFERS, EDWARD, Keighley, Yorkshire.

1884 CHAFFEY, WAYLAND CHARLES, M.D., 13, Montpellier-road, Brighton.

1891 CHAPLIN, ARNOLD, M.D., 24, Finsbury-circus, E.C.

1884 CHAVASSE, THOMAS FREDERICK, M.D., C.M., 22, Temple-row, Birmingham.

1879 CHEYNE, WILLIAM WATSON, M.B., C.M., F.R.S., 75, Harley-street, W. (C. 1885-7. V.-P. 1892-3.)

1858 CHILD, GILBERT W., Cowley House, Oxford.

1873 CHISHOLM, EDWIN, M.D., Abergeldie, Ashfield, near Sydney, New South Wales [care of Messrs. Dawson, 121, Cannon-street, E.C.].

1865 CHURCH, WILLIAM SELBY, M.D., 130, Harley-street, W. (C. 1871-3. V.-P. 1894-6.)

1868 CHURCHILL, FREDERICK, M.D., 4, Cranley-gardens, Queen's-gate, S.W.

1861 CLAPTON, EDWARD, M.D., 22, St. Thomas's-street, Southwark, S.E.

1872 CLARK, ANDREW, 71, Harley-street, W.

1886 CLARK, FRANCIS WILLIAM, The Dispensary, Newcastle-on-Tyne.

1891 CLARKE, J. JACKSON, M.B., 9, Old Cavendish-street, W.

1885 CLARKE, JOHN MICHELL, M.D., 28, Pembroke-road, Clifton, Bristol.

1881 CLARKE, W. BRUCE, M.B., 51, Harley-street, W. (C. 1892-4.)

1875 CLUTTON, HENRY HUGH, M.A., 2, Portland-place, W. (C. 1884-6. V.-P. 1892-3.)

1865 Coates, CHARLES, M.D., 10, Circus, Bath.

1885 COATS, JOSEPH, M.D., 31, Lynedoch-street, Glasgow.

1856 COCKLE, JOHN, M.D., M.A., The Lodge, West Molesey.

1892 COLE, ROBERT HENRY, M.D., Moorcroft, Hillingdon, Uxbridge.

1886 COLLIER, WILLIAM, M.D., 62, High-street, Oxford.

1891 COLLINS, EDWARD TREACHER, 84, Wimpole-street, W.

1888 COLLINS, WILLIAM JOB, M.D., M.S., 1, Albert-terrace, Regent's-park, N.W.

1878 COLLYNS, R. T. POOLE, 20, Lingfield-road, Wimbledon.

1888 COLMAN, WALTER STACY, M.B., 22, Wimpole-street, W.

1862 COLQUHOUN, DANIEL, M.D., Dunedin, New Zealand.

1896 CONNELL, W. T., M.D., Kingston, Canada.

1891 COOK, HERBERT G. GRAHAM, M.D., University College, Cardiff.

1858 COOKE, R. T. E. BARRINGTON, 15, St. Nicholas-cliff, Scarborough, Yorkshire.

1871 COOKE, THOMAS, 40, Brunswick-square, W.C.

1866 COOMBS, ROWLAND HILL, Mill-street, Bedford.

1892 COOPER, C. DUDLEY, London County Lunatic Asylum, Claybury, Woodford, Essex.

1892 COTTERELL, EDWARD, 5, West Halkin-street, S.W.

1876 COTTLE, WYNDHAM, M.D., 39, Hertford-street, W.

1861 COUPER, JOHN, 80, Grosvenor-street, W. (C. 1870-2.)

Elected

1873 COUPLAND, SIDNEY, M.D. (TREASURER), 16, Queen Anne-street, W. (C. 1878-81, 1889-91. S. 1886-8. V.-P. 1892-3. T. 1894—.)

1884 CRICHTON, GEORGE, M.D., 3, Cambridge-villas, Twickenham.

1873 CRIPPS, WILLIAM HARRISON, 2, Stratford-place, W. (C. 1883-5. V.-P. 1893-4.)

1877 CROCKER, HENRY RADCLIFFE, M.D., 121, Harley-street, W. (C. 1887-9.)

1856 CROFT, JOHN, 6, Mansfield-street, W. (C. 1870-2. V.-P. 1882-4.)

1879 CROOKE, GEORGE FREDERICK, M.D., 2, Edmund-street, Birmingham.

1886 CROOKSHANK, EDGAR, M.B., Saint Hill, near East Grinstead, Sussex. (C. 1890-3.)

1875 CROSS, FRANCIS RICHARDSON, 5, The Mall, Clifton, Bristol.

1890 CROWLE, THOMAS H. RICKARD, 56, Harley-street, Cavendish-square, W.

1889 CUFF, ROBERT, M.B., 1, The Crescent, Scarborough.

1885 CULLINGWORTH, CHARLES JAMES, M.D., 14, Manchester-square, W.

1871 CUMBERBATCH, A. ELKIN, 80, Portland-place, W.

1873 CURNOW, JOHN, M.D., 11, Wimpole-street, Cavendish-square, W. (C. 1882-4.)

1893 CURTIS, HENRY JONES, M.D., 111, Gower-street, W.C.

1884 DAKIN, W. RADFORD, M.D., B.S., 18, Grosvenor-street, Grosvenor-square, W.

1883 DALTON, NORMAN, M.D., 4, Mansfield-street, W.

1873 DAVIDSON, ALEXANDER, M.D., 2, Gambier-terrace, Liverpool.

1869 DAVIES-COLLEY, J. NEVILLE C., M.C., 36, Harley-street, W. (C. 1880-2. V.-P. 1890-1.)

1883 DAVIS, EDWIN HARRY, West Hartlepool.

1859 Davis, FRANCIS WILLIAM, R.N.

1879 DAVY, HENRY, M.D., 29, Southernhay, Exeter.

1894 DAWSON, BERTRAND, M.D., 46, Finsbury-pavement, E.C.

1889 DEAN, HENRY PERCY, M.B., M.S., 84, Wimpole-street, W.

1887 DELÉPINE, SHERIDAN, M.B., C.M., 258, Oxford-road, Manchester.

1880 DENT, CLINTON T., 61, Brook-street, W.

1871 DICKINSON, EDWARD HARRIMAN, M.A., M.D., 162, Bedford-street, Liverpool.

1858 DICKINSON, WILLIAM HOWSHIP, M.D., 9, Chesterfield-street, W. (C. 1866-8. S. 1869-71. V.-P. 1872-4. P. 1889-90.)

1890 DICKINSON, WILLIAM LEE, M.D., 9, Chesterfield-street, W.

1872 DIVER, EBENEZER, M.D., Kenley, Caterham-valley, Surrey.

1872 DORAN, ALBAN HENRY GRIFFITHS, 9, Granville-place, W. (C. 1882-4. V.-P. 1894-6.)

1866 DOUGLAS-POWELL, Sir RICHARD, Bart., M.D., 62, Wimpole-street, W. (C. 1873-5, 1881-3. S. 1877-9. V.-P. 1887-8.)

1893 DOWSON, WALTER, M.D., 9, Great George-street, Bristol.

1877 DRAKE-BROCKMAN, E. F., Madras Medical Service [care of Mr. Lewis, Gower-street, W.C.].

Elected

1880 DRESCHFELD, JULIUS, M.D., 325, Oxford-road, Manchester. (C. 1896—.)
1896 DREW, DOUGLAS, 60, Gower-street, W.C.
1879 DREWITT, F. G. DAWTREY, M.D., 2, Manchester-square, W. (C. 1890-2.)
1893 DRYSDALE, JOHN HANNAH, M.B., 25, Welbeck-street, W.
1865 DUCKWORTH, Sir DYCE, M.D., LL.D., 11, Grafton-street, Bond-street, W. (C. 1877.)
1847 DUDGEON, ROBERT E., M.D., 53, Montagu-square, W.
1871 DUKES, CLEMENT, M.D., B.S., Sunnyside, Rugby.
1877 DUNBAR, J. J. MACWHIRTER, M.D., Hedingham House, Clapham-common, S.W.
1877 DUNCAN, ANDREW, M.D., 8, Henrietta-street, Covent-garden, W.C.
1889 DUNCAN, JOHN, M.D., St. Petersburg.
1884 DUNN, LOUIS ALBERT, M.B., M.S., The College, Guy's Hospital, S.E.
1879 DURHAM, FREDERIC, M.B., 82, Brook-street, W.

1893 ECCLES, WILLIAM MCADAM, 124, Harley-street, W.
1892 EDDOWES, ALFRED, M.D., 25, Old Burlington-street, W.
1880 EDMUNDS, WALTER, M.C., 75, Lambeth Palace-road, S.E. (C. 1892-4.)
1882 EDWARDS, F. SWINFORD, 55, Harley-street, W.
1889 ELAM, WILLIAM HENRY, New Barnet, Herts.
1883 ELDER, GEORGE, M.D., 17, Regent-street, Nottingham.
1867 ELLIS, JAMES, M.D., Coburg-street, Fratton, Portsmouth, and California.
1873 ENGELMANN, GEORGE JULIUS, M.D., A.M., 336, Beacon-street, Boston, Mass., U.S.A.
1875 EVANS, JULIAN AUGUSTUS, A.M., M.D., 123, Finborough-road, Redcliffe-square, S.W.
1894 EVANS, WILLMOTT H., 13, Taviton-street, Gordon-square, W.C.
1879 EVE, FREDERIC S., 125, Harley-street, W. (C. 1885-7. V.-P. 1895—.)
1876 EWART, JAMES COSSAR, M.B., C.M., F.R.S., School of Medicine, Edinburgh.
1881 EWART, Sir JOSEPH, M.D., Montpellier Terrace, Brighton.
1877 EWART, WILLIAM, M.D., 33, Curzon-street, W. (C. 1889-91.)
1859 Ewens, JOHN, The Elms, Cotham-hill, Bristol.
1887 EYLES, CHARLES HENRY, Gold Coast Colony.

1889 FAIRBANK, FREDERICK ROYSTON, M.D., Hillside, Westcott, Dorking.
1894 FAWCETT, JOHN, M.D., 24, St. Thomas's-street, S.E.
1872 FAYRER, Sir JOSEPH, K.C.S.I., M.D., LL.D., F.R.S., 16, Devonshire-street, W. (C. 1880-2. V.-P. 1890-1.)
1872 FENN, EDWARD L., M.D., Grey Friars, Colchester.
1883 FENWICK, E. HURRY, 14, Savile-row, W. (C. 1894—.)
1872 FENWICK, JOHN C. J., M.D., 25, North-road, Durham.
1863 FENWICK, SAMUEL, M.D., 29, Harley-street, W.
1892 FENWICK, W. SOLTAU, M.D., 10, Devonshire-street, W.

Elected

1885 **Féré**, Charles, M.D., Médecin de Bicêtre; Boulevard St. Michel, 37, Paris.

1859 Fisher, Alexander, M.D., 2, Bruntsfield Gardens, Edinburgh.

1897 Fisher, Theodore, M.D., 25, Pembroke-road, Clifton, Bristol.

1882 Fleming, George, C.B., LL.D., Higher Leigh, Combe Martin, North Devon.

1893 Fletcher, H. Morley, M.A., M.D., B.C., 98, Harley-street, W.

1872 Forbes, Daniel Mackay, Shoreditch Infirmary, 204, Hoxton-street, N.

1866 **Foster**, Sir Balthazar Walter, M.D., M.P., 11, George-street, Hanover-square, W.

1872 Fotherby, Henry I., M.D., Woodthorpe Cote, Reigate.

1891 Foulerton, Alexander Grant Russell, 23, Carlisle Mansions, Victoria-street, S.W.

1880 Fowler, James Kingston, M.A., M.D., 35, Clarges-street, W. (C. 1887-8.)

1878 Fox, Thomas Colcott, M.B., B.A., 14, Harley-street, W. (C. 1892-4.)

1858 Francis, Charles Richard, M.B., Bengal Medical Establishment, Indian Army.

1886 Freeman, Henry William, 24, Circus, Bath.

1896 Freyberger, Ludwig, M.D., 41, Regent's-park-road, N.W.

1891 Fripp, Alfred Downing, M.S., 65, Harley-street, W.

1864 Frodsham, John Mill, M.D., Streatham, S.W.

1894 Furnivall, Percy, 34, Adelaide-road, N.W.

1893 Fyffe, William Kington, M.B., 1, Boullcott-street, Wellington, New Zealand.

1880 Gabbett, Henry Singer, M.D., 20, Burlington-place, Eastbourne.

1858 **Gairdner**, William Tennant, M.D., LL.D.Edin., F.R.S., 225, St. Vincent-street, Glasgow. (V.-P. 1891-2.)

1890 Galloway, James, M.A., M.D., 21, Queen Anne-street, W.

1870 Galton, John H., M.D., Sylvan-road, Upper Norwood, S.E.

1846 **GARROD**, Sir Alfred Baring, M.D., F.R.S., 10, Harley-street, W. (C. 1851. V.-P. 1863-5.)

1892 Garrod, Archibald Edward, M.D., 9, Chandos-street, Cavendish-square, W.

1879 Garstang, Thomas Walter Harropp, Headingley House, Knutsford, Cheshire.

1872 Garton, William, M.D., Inglewood, Aughton, near Ormskirk, Lancashire.

1891 Gaster, Aughel, M.D., 224, Belsize-road, N.W.

1880 Gibbes, Heneage, M.B., University of Michigan, Ann Arbor, Michigan, U.S.A.

1853 **GIBBON**, Septimus, M.D., 39, Oxford-terrace, Hyde-park, W.

1878 Gibbons, R. A., M.D., 29, Cadogan-place, S.W.

1893 Gibbs, Charles, Charing-cross Hospital, W.C.

1872 Gilbart-Smith, Thomas, M.D., 68, Harley-street, W.

Elected

1876 GILL, JOHN, M.D., 31, Apsley-road, Clifton, Bristol.

1881 GLYNN, THOMAS ROBINSON, M.D., 62, Rodney-street, Liverpool.

1873 GODLEE, RICKMAN JOHN, M.B., M.S., 19, Wimpole-street, W. (C. 1877-80. 1891-2. S. 1887-9. V.-P. 1893-4.)

1878 GOLDING-BIRD, CUTHBERT H., M.B., B.S., 12, Queen Anne-street, W. (C. 1885-7. V.-P. 1894-6.)

1890 GOODALL, E. WILBERFORCE, M.D., The Eastern Hospital, Homerton, N.E.

1871 GOODHART, JAMES FREDERIC, M.D., 25, Portland-place, W. (C. 1876-8. 1886-8. S. 1883-5. V.-P. 1892-3.)

1894 GOSSAGE, ALFRED MILNE, M.B., B.Ch., 54, Upper Berkeley-street, W.

1875 GOULD, ALFRED PEARCE, M.S., 10, Queen Anne-street, W. (C. 1883-5.)

1870 GOWERS, WILLIAM RICHARD, M.D., F.R.S., 50, Queen Anne-street, W. (C. 1878-9. V.P. 1896—.)

1888 GRANT, J. DUNDAS, M.A., M.D., C.M., 8, Upper Wimpole-street, W.

1867 GREEN, T. HENRY, M.D., 74, Wimpole-street, W. (C. 1871-3, 1878-9. S. 1875-6. V.-P. 1886-8.)

1895 GREEN, CHARLES DAVID, M.D., Addison House, Upper Edmonton.

1873 GREENFIELD, WILLIAM SMITH, M.D., B.S., 7, Heriot-row, Edinburgh. (C. 1877-80. V.-P. 1893-4.)

1886 GREVES, EDWIN HYLA, M.D., Rodney House, Suffolk-road, Bournemouth.

1892 GRIFFITH, WILLIAM STOKES, M.B., B.C., 4, Bramham-gardens, S.W.

1887 GRIFFITHS, JOSEPH, M.B., C.M., 16, Panton-street, Cambridge.

1876 GRIFFITHS, THOMAS D., M.D., Hearne Lodge, Swansea.

1887 HABERSHON, SAMUEL HERBERT, M.D., 70, Brook-street, W.

1851 HACON, E. DENNIS, 269, Mare-street, Hackney, N.E. (C. 1872.)

1892 HADLEY, WILFRED JAMES, M.D., 11, Wimpole-street, W.

1882 HAIG, A., M.D., 7, Brook-street, W.

1894 HALLIDIE, ANDREW HALLIDIE SMITH, M.B., 36, Gloucester-street, S.W.

1877 HALLOWES, FREDERICK BLACKWOOD, Redhill, Surrey.

1886 HAMILTON, DAVID JAMES, M.B., 1, Albyn-place, Aberdeen.

1890 HANDFIELD-JONES, MONTAGU, M.D., 35, Cavendish-square, W.

1886 HANDFORD, HENRY, M.D., 14, Regent-street, Nottingham.

1891 HANKIN, E. H., St. John's College, Cambridge. [India.]

1882 HARBINSON, ALEXANDER, M.D., County Lunatic Asylum, Lancaster.

1848 HARE, CHARLES JOHN, M.D., Berkeley House, 15, Manchester-square, W. (C. 1852-4. V.-P. 1874-7.)

1893 HARLEY, VAUGHAN, M.D., 25, Harley-street, W.

1872 HARRIS, HENRY, M.D., Trengweath-place, Redruth, Cornwall.

1879 HARRIS, VINCENT DORMER, M.D., 31, Wimpole-street, W.

1858 HART, ERNEST, 38, Wimpole-street, W. (C. 1867-8.)

1891 HASLAM, WILLIAM F., 33, Paradise-street, Birmingham.

Elected

1870 HAWARD, JOHN WARRINGTON, 16, Savile-row, W. (C. 1879-81. V.-P. 1890-1.)

1886 HAWKINS, FRANCIS HENRY, M.B., 26, Portland-place, Reading.

1890 HAWKINS, HERBERT PENNELL, M.D., 109, Harley-street, W.

1856 HEATH, CHRISTOPHER, 36, Cavendish-square, W. (C. 1866-7. V.-P. 1879-81.)

1892 HEATON, GEORGE, M.B., B.Ch., 33, Temple-row, Birmingham.

1881 HEBB, RICHARD G., M.D. (HON. SECRETARY), 9, Suffolk-street, S.W. (C. 1891-3. S. 1896—.)

1884 HEBBERT, CHARLES ALFRED. (Travelling.)

1878 HELLIER, JOHN B., M.D., Headingley, Leeds.

1879 HENDERSON, GEORGE COURTENAY, M.D., Kingston, Jamaica, West Indies.

1869 HENSLEY, PHILIP J., M.D., 4, Henrietta-street, W.

1884 HERRINGHAM, WILMOT PARKER, M.D., 13, Upper Wimpole-street, W. (C. 1894—.)

1892 HEWLETT, RICHARD TANNER, M.D., 101, Gt. Russell-street, W.C.

1864 HICKMAN, WILLIAM, M.B., 5, Harley-street, W. (C. 1890-2.)

1880 HOBSON, JOHN MORRISON, M.D., Glendalough, Morland-road, Croydon.

1854 HOLMES, TIMOTHY, 6, Sussex-place, Hyde-park, W. (C. 1862-3. S. 1864-7. C. 1868. V.-P. 1869-71.)

O.M. HOLTHOUSE, CARSTEN, Bath-terrace, Richmond. (C. 1852-4, V.-P. 1874-5.)

1878 HOOD, DONALD WILLIAM CHARLES, M.D., 43, Green-street, Park-lane, W.

1864 HOOD, WHARTON P., M.D., 11, Seymour-street, W.

1895 HOPKINS, F. G., M.B., Guy's Hospital, S.E.

1882 HOPKINS, JOHN, Central London Sick Asylum, Cleveland-street, W.

1879 HORROCKS, PETER, M.D., Brook-street, W.

1883 HORSLEY, VICTOR, M.B., B.S., F.R.S., 25, Cavendish-square, W. (C. 1888-9.)

1896 HORTON-SMITH, PERCIVAL, M.D., B.C., 15, Upper Brook-street, W.

1880 HOVELL, T. MARK, 105, Harley-street, W.

1893 HOWARD, ROBERT JAMES BLISS, M.D., 31, Queen Anne-street, W.

1875 HOWSE, HENRY GREENWAY, M.S., 59, Brook-street, W. (C. 1878-81.)

1884 HUDSON, CHARLES ELLIOTT LEOPOLD BARTON, 16, Harley-street, W. (C. 1896—.)

1856 HUDSON, JOHN, M.D., 11, Cork-street, W.

1874 HUMPHREYS, HENRY, M.D., Victoria-road, Fleet, Hants.

1888 HUNTER, WILLIAM, M.D., 54, Harley-street, W.

1852 HUTCHINSON, JONATHAN, F.R.S., 15, Cavendish-square, W. (C. 1856-9. V.-P. 1872-3, 1881-3. P. 1879-80.)

1882 HUTCHINSON, JONATHAN, jun., 15, Cavendish-square, W. (C. 1889-91.)

1884 HUTTON, HENRY RICHMOND, M.B., 8A, St. John-street, Manchester.

1889 HYSLOP, THEOPHILUS BULKELEY, M.D., C.M., Bethlem Convalescent Hospital, Witley, Surrey.

1880 INGRAM, ERNEST FORTESCUE, Newcastle, Natal, S. Africa.

Elected

1886 JACKSON, ARTHUR MOLYNEUX, M.D., Kent County Asylum, Barming Heath, Maidstone.

1865 JACKSON, J. HUGHLINGS, M.D., F.R.S., 3, Manchester-square, W. (C. 1872-3. V.-P. 1888-9.)

1886 JACKSON, PHILIP J., 216, Great Dover-street, S.E.

1875 JALLAND, WILLIAM HAMERTON, St. Leonard's House, Museum-street, York.

1888 JAMES, JAMES THOMAS, M.D., 30, Harley-street, W.

1853 Jardine, JOHN LEE, Capel, near Dorking, Surrey.

1881 JENNINGS, WILLIAM OSCAR, M.D., Rue Marbœuf, Avenue des Champs-Elysées, Paris.

1879 JESSOP, CHARLES MOORE, Clare Lodge, Redhill.

1866 JESSOP, THOMAS RICHARD, 31, Park-square, Leeds.

1878 JOHNSON, ARTHUR JUKES, Yorkville, Ontario, Canada.

1876 JOHNSON, CHARLES HENRY, Winton House, Basingstoke, Hants.

1888 JOHNSON, RAYMOND, M.B., B.S., 20, Weymouth-street, Portland-place, W. (C. 1896—.)

1881 JOHNSTON, JOSEPH, M.D., 24, St. John's Wood-park, N.W.

1854 JOHNSTONE, ATHOL A. W., St. Moritz House, 61, Dyke-road, Brighton.

1853 JONES, SYDNEY, M.B., 18, Wimpole-street, W. (C. 1864-6. V.-P. 1886-7.)

1888 JONES, TALFOURD, M.B., Eastbourne.

1862 JONES, THOMAS RIDGE, M.D., 4, Chesham-place, S.W. (C. 1882-4.)

1886 JULER, HENRY EDWARD, 23, Cavendish-square, W.

1890 KANTHACK, A. A., M.D., B.S., St. Bartholomew's Hospital, E.C. (C. 1894—.)

1867 KELLY, CHARLES, M.D., Ellesmere, Gratwicke-road, Worthing, Sussex. (C. 1874.)

1846 KENT, THOMAS J., 89, Piccadilly, W.

1879 KESTEVEN, WILLIAM HENRY, Hillwood, Waverley-grove, Hendon, N.W.

1859 KIALLMARK, HENRY WALTER, 5, Pembridge-gardens, W. (C. 1875-6.)

1882 KIDD, PERCY, M.D., 60, Brook-street, W. (C. 1889-91.)

1867 KING, EDWIN HOLBOROW, Netley Court, Southampton.

1871 KING, ROBERT, M.B., Boyfield House, Moulton, Spalding, Lincolnshire.

1852 KINGDON, J. ABERNETHY, 2, Bank-buildings, Lothbury, E.C.

1888 KYNSEY, Sir WILLIAM RAYMOND, K.C.M.G., Colombo, Ceylon.

1878 LANCEREAUX, ETIENNE, M.D., 44, Rue de la Bienfaisance, Paris.

1882 LANE, WILLIAM ARBUTHNOT, M.B., M.S., 21, Cavendish-square, W. (C. 1891-3.)

1865 LANGTON, JOHN, 62, Harley-street, W. (C. 1882-4.)

1869 LARCHER, O., M.D.Par., 97, Rue de Passy, Paris. [M. Kliensieck, Libraire, Rue de Lille 11, Paris, per Messrs. Longmans.]

1884 LARDER, HERBERT, Whitechapel Infirmary, Baker's-row, N.E.

Elected

1873 LATHAM, PETER WALLWORK, M.D., 17, Trumpington-street, Cambridge.
1876 LAW, WILLIAM THOMAS, M.D., 9, Norfolk-crescent, W.
1853 LAWRENCE, HENRY JOHN HUGHES, Picton House, Llandowror, St. Clears. (C. 1873-5.)
1892 LAWRENCE, TURNER WILLIAM PELHAM, M.B., 46, Maida-vale, W.
1893 LAWSON, ARNOLD, M.D., 12, Harley-street, W.
1859 LAWSON, GEORGE, 12, Harley-street, W. (C. 1870-1. V.-P. 1884-5.)
1879 LAYCOCK, GEORGE LOCKWOOD, M.B., Melbourne, Victoria, Australia.
1891 LAZARUS-BARLOW, WALTER S., M.B. (Sydney), 17, Chesterton-road, Cambridge.
1875 LEDIARD, HENRY AMBROSE, M.D., 35, Lowther-street, Carlisle.
1852 LEE, HENRY, 61, Queensborough-terrace, Hyde-park, W. (C. 1860-2. V.-P. 1875-6.)
1879 LEECH, DANIEL JOHN, M.D., 96, Mosley-street, Manchester.
1877 LEES, DAVID B., M.D., 22, Weymouth-street, W. (C. 1890-2.)
1867 LEES, JOSEPH, M.D., 21, Brixton-road, S.W.
1877 LEESON, JOHN RUDD, M.D., C.M., 6, Clifden-road, Twickenham.
1868 LEGG, JOHN WICKHAM, M.D. (Travelling.) (C. 1874-5.)
1892 LEITH, ROBERT FRASER CALDIE, M.B., C.M., B.Sc., 20, Merchiston-terrace, Edinburgh.
1892 Leudet, ROBERT, 16, Rue du Contrat-Social, Rouen, France.
1861 LICHTENBERG, GEORGE, M.D., 47, Finsbury-square, E.C.
1877 LISTER, Lord, D.C.L., LL.D., F.R.S., 12, Park-crescent, W. (C. 1880-2. V.-P. 1887-8, 1891-2.)
1897 LISTER, THOMAS DAVID, 95, Wimpole-street, W.
1895 LITTLE, ERNEST GRAHAM GORDON, M.D., 39, Devonshire-street, Portland-place, W.
1889 LITTLE, JOHN FLETCHER, M.B., 32, Harley-street, W.
1862 LITTLE, LOUIS S., Shanghai, China.
1896 LITTLEWOOD, HARRY, 40, Park-square, Leeds.
1874 LIVEING, EDWARD, M.D., 52, Queen Anne-street, W.
1863 LIVEING, ROBERT, M.D., 11, Manchester-square, W. (C. 1876.)
1882 LOCKWOOD, C. B., 19, Upper Berkeley-street, W. (C. 1893-6.)
1876 LONGHURST, ARTHUR EDWIN TEMPLE, M.D., 4, Eaton Square, S.W. (C. 1885-7.)
1881 LUBBOCK, MONTAGU, M.D., 19, Grosvenor-street, W.
1873 LUCAS, R. CLEMENT, M.B., B.S., 50, Wimpole-street, W. (C. 1883-5.)
1880 LUND, EDWARD, 22, St. John-street, Manchester.
1879 LUNN, JOHN REUBEN, St. Marylebone Infirmary; Rackham-street, Ladbroke-grove-road, W.
1887 LYON, THOMAS GLOVER, M.D., 8, Finsbury-circus, E.C.

1871 MAC CORMAC, Sir WILLIAM, 13, Harley-street, W. (C. 1878-80.)
1893 MCFADYEAN, JOHN, Royal Veterinary College, Great College-street, N.W.
1896 MACFADYEN, ALLAN, M.D., B.Sc., 39, Ridgmount-gardens, W.C.

Elected

1882 MACKENZIE, FREDERIC MORELL, 29, Hans-place, S.W.

1885 MACKENZIE, HECTOR WILLIAM GAVIN, M.A., M.D., 59, Welbeck-street, W. (C. 1895—.)

1870 MACKENZIE, JOHN T., Bombay, India.

1878 MACKENZIE, STEPHEN, M.D., 18, Cavendish-square, W. (C. 1888-90.)

1879 MACLAGAN, THOMAS JOHN, M.D., 9, Cadogan-place, S.W.

1865 MACLAURIN, HENRY NORMAND, M.D., 187, Macquarie-street, Sydney, New South Wales.

1879 MACREADY, JONATHAN FORSTER, 132, Harley-street, W.

1896 MCWEENEY, EDMOND JOSEPH, M.D., M.Ch., 84, St. Stephen's-green, Dublin.

1885 MAGUIRE, ROBERT, M.D., 4, Seymour-street, W.

1877 MAKINS, GEORGE HENRY, 47, Charles-street, Berkeley-square, W. (C. 1889-91.)

1887 MALCOLM, JOHN DAVID, M.B., C.M., 13, Portman-street, W.

1892 MANN, HAROLD EDWARD, Alderney.

1890 MANSON, PATRICK, M.D., C.M., 21, Queen Anne-street, W.

1876 MAPLES, REGINALD, Kingsclere, near Newbury.

1868 MARSH, F. HOWARD, 30, Bruton-street, W. (C. 1876-7.) (V.-P. 1889-90.)

1887 MARTIN, SIDNEY, M.D., B.S., F.R.S., 10, Mansfield-street, W. (C. 1893-6.)

1889 MASON, DAVID JAMES, M.D., Rosemont, Maidenhead.

1867 MASON, PHILIP BROOKES, Burton-on-Trent.

1892 MASTERS, JOHN ALFRED, M.D., 57, Lexham-gardens, Kensington, W.

1884 MAUDSLEY, HENRY CARR, M.D., 11, Spring-street, Melbourne, Victoria.

1852 MAY, GEORGE, M.B., Reading.

1888 MAY, WILLIAM PAGE, M.D., B.Sc., 49, Welbeck-street, W.

1881 MAYLARD, ALFRED ERNEST, M.B., 4, Berkeley-terrace, Glasgow.

1874 MEREDITH, WILLIAM APPLETON, C.M., 21, Manchester-square, W.

1894 MICHELS, ERNST, M.D., 6, West-street, Finsbury-circus, E.C.

1866 MICKLEY, GEORGE, M.A., M.B., St. Luke's Hospital, Old-street, E.C.

1882 MONEY, ANGEL, M.D., Hunter-street, Sydney, New South Wales.

1879 MOORE, NORMAN, M.D., 94, Gloucester-place, Portman-square, W. (C. 1885-7. V.-P. 1895—.)

1875 MORGAN, JOHN H., 68, Grosvenor-street, W. (C. 1886-8.)

1874 MORISON, ALEXANDER, M.D., C.M., 14, Upper Berkeley-street, W.

1869 MORRIS, HENRY, M.A., 8, Cavendish-square, W. (C. 1877-9, 1884-6. S. 1881-3. V.-P. 1888-9.)

1879 MORRIS, MALCOLM ALEXANDER, 8, Harley-street, W.

1894 MORRICE, GEORGE GAVIN, M.D., Crown-chambers, Salisbury.

1891 MORTON, CHARLES A., 24, St. Paul's-road, Clifton, Bristol.

1875 MORTON, JOHN, M.B., Guildford.

1884 MOTT, FREDERICK WALKER, M.D., 84, Wimpole-street, W. (C. 1891-3.)

1879 MOULLIN, CHARLES W. MANSELL, 69, Wimpole-street, W.

Elected

1893 MUMMERY, JOHN HOWARD, 10, Cavendish-place, W.

1876 MUNRO, WILLIAM, M.D., C.M., Clarkefield, Fountain-street, Cheetham Hill, Manchester.

1885 MURRAY, HUBERT MONTAGUE, M.D., 27, Savile-row, W. (C. 1896—.)

1894 MURRAY, JOHN, M.B., B.Ch., 133, Harley-street, W.

1864 MYERS, ARTHUR B. R., 43, Gloucester-street, Warwick-square, S.W. (C. 1872-3.)

1887 NASON, EDWARD NOEL, M.B., 80, Abbey-street, Nuneaton.

1873 NETTLESHIP, EDWARD, 5, Wimpole-street, W. (C. 1882-4.)

1875 NEWBY, CHARLES HENRY, 15, Landport-terrace, Southsea, Hants.

1884 NEWLAND-PEDLEY, F., 32, Devonshire-place, Portland-place, W.

1865 NEWMAN, WILLIAM, M.D., Stamford, Lincolnshire.

1895 NIAS, J. BALDWIN, M.D., 5, Rosary-gardens, S. Kensington, S.W.

1868 NICHOLLS, JAMES, M.D., Trenarren, Newquay, Cornwall.

1876 NICHOLSON, JOHN FRANCIS, M.D., 29, Albion-street, Hull.

1864 NORTON, ARTHUR T., 101, Harley-street, W. (C. 1877-9.)

1883 NORVILL, FREDERIC HARVEY, M.B., Summerland, Yeovil, Somersetshire.

1856 NUNN, THOMAS WILLIAM, 8, Stratford-place, W. (C. 1864-6. V.-P. 1878-80.)

1880 O'CONNOR, BERNARD, M.D., 25, Hamilton-road, Ealing.

1873 O'FARRELL, GEORGE PLUNKETT, M.D., 19, Fitzwilliam-square, Dublin.

1880 OGILVIE, GEORGE, M.B., C.M., 22, Welbeck-street, W.

1880 OGILVIE, LESLIE, M.B., C.M., 46, Welbeck-street, W.

1894 OGLE, CYRIL, M.B., 96, Gloucester-place, W.

1850 OGLE, JOHN W., M.D., 96, Gloucester-place, Portman-square, W. (C. 1855-6. S. 1857-60. C. 1861-3. V.-P. 1865-8.)

1876 OLIVER, JOHN FERENS, M.D., 12, Old Elvet, Durham.

1888 OPENSHAW, THOMAS HORROCKS, M.S., 16, Wimpole-street, W.

1875 ORD, WILLIAM MILLER, M.D., 37, Upper Brook-street, W. (C. 1880-2. V.-P. 1893-4.)

1892 ORD, WILLIAM WALLIS, M.D., The Hall, Salisbury.

1879 ORMEROD, J. A., M.D., 25, Upper Wimpole-street, W. (C. 1887-9.)

1875 OSBORN, SAMUEL C., 10, Maddox-street, W., and Maisonnette, Datchet, Bucks.

1881 OWEN, ISAMBARD, M.D., 40, Curzon-street, W.

1865 OWLES, JAMES ALLDEN, M.D., Hill View, Woking, Surrey.

1870 PAGET, Sir JAMES, Bart., D.C.L., LL.D., F.R.S., 5, Park-square west, Regent's-park, W. (P. 1887-8.)

1884 PAGET, STEPHEN, 70, Harley-street, W. (C. 1894—.)

1895 PAKES, WALTER CHARLES, Guy's Hospital, S.E.

1897 PARVITT, CHARLES D., M.D., London, Canada.

Elected

1872 PARKER, ROBERT WILLIAM, 13, Welbeck-street, W. (C. 1881-3.)

1874 PARKER, RUSHTON, M.B., B.S., 59, Rodney-street, Liverpool.

1853 PARKINSON, GEORGE, 50, Brook-street, W.

1882 PASTEUR, WILLIAM, M.D., 4, Chandos-street, W. (C. 1893-6.)

1885 PAUL, FRANK THOMAS, 38, Rodney-street, Liverpool.

1865 PAVY, FREDERICK WILLIAM, M.D., LL.D., F.R.S., 35, Grosvenor-street, W. (C. 1872-4. V.-P. 1891-2. P. 1893-4.)

1868 PAYNE, JOSEPH FRANK, M.D., 78, Wimpole-street, W. (C. 1873-5, 1883-5. S. 1880-2. V.-P. 1888-9.)

1872 PEARCE, JOSEPH CHANING, M.D., C.M., Montague House, St. Lawrence-on-Sea, Kent.

1863 PEARSON, DAVID R., M.D., 23, Upper Phillimore-place, W.

1879 PEEL, ROBERT, 130, Collins-street East, Melbourne, Victoria.

1889 PENBERTHY, JOHN, Royal Veterinary College, Camden Town, N.W.

1887 PENROSE, FRANCIS GEORGE, M.D., 4, Harley-street, W.

1884 PEPPER, AUGUSTUS JOSEPH, M.B., C.M., 13, Wimpole-street, W.

1888 PERRY, EDWIN COOPER, M.D., Superintendent's House, Guy's Hospital, S.E.

1878 PHILIPPS, SUTHERLAND REES, M.D., St. Ann's-heath, Virginia Water, Chertsey.

1878 PHILLIPS, JOHN WALTER, 30, Stanley-street, West Melbourne, Victoria.

1863 PICK, THOMAS PICKERING, 18, Portman-street, W. (C. 1870-1. V.-P. 1885-7.)

1896 PIGG, T. STRANGEWAYS, St. Bartholomew's Hospital, E.C.

1893 PINKERTON, ROBERT A., M.A., M.D., 71, Craven-park, Harlesden, N.W.

1884 PITT, GEORGE NEWTON, M.D., 15, Portland-place, W. (S. 1894-6. C. 1890-2, 1896—.)

1876 PITTS, BERNARD, M.A., M.C., 109, Harley-street, W. (C. 1888-90.)

1883 POLAND, JOHN, 4, St. Thomas's-street, Southwark, S.E.

1882 POLLARD, BILTON, M.B., B.S., 24, Harley-street, W. (C. 1895—.)

1850 POLLOCK, JAMES EDWARD, M.D., 52, Upper Brook-street, W. (C. 1862-4. V.-P. 1879-81.)

1870 POORE, GEORGE VIVIAN, M.D., 30, Wimpole-street, W. (C. 1883-5).

1876 PORT, HEINRICH, M.D., 48, Finsbury-square, E.C.

1879 POTTER, HENRY PERCY, St. Mary Abbotts' Infirmary, Marloes-road, Kensington, W.

1884 POWER, D'ARCY, M.A., M.B., 10A, Chandos-street, W. (C. 1891-3.)

1865 POWER, HENRY, 37A, Great Cumberland-place, W. (C. 1876-7.)

1887 PRATT, WILLIAM SUTTON, Weedon, Northamptonshire.

1884 PRICE, J. A. P., M.D., 41, Castle-street, Reading.

1856 PRIESTLEY, Sir WILLIAM OVEREND, M.D., M.P., 17, Hertford-street, W.

1888 PRIMROSE, ALEXANDER, M.B., C.M. 196, Simcoe-street, Toronto, Canada.

1882 PRINGLE, J. J., M.B., C.M., 23, Lower Seymour-street, W.

1848 PURNELL, JOHN JAMES, Woodlands, Streatham-hill, S.W. (C. 1858-61.)

Elected

1895 PURVIS, WILLIAM PRIOR, M.D., Royal Hants Infirmary, Southampton.

1865 PYE-SMITH, PHILIP HENRY, M.D., F.R.S., 48, Brook-street, W. (C. 1874-7. V.-P. 1890-1.)

O.M. QUAIN, Sir RICHARD, Bart., M.D., LL.D., F.R.S. (TRUSTEE), 67, Harley-street, W. (C. 1846-51. S. 1852-6. T. 1857-68. *Pres.* 1869-70. V.-P. 1871-3.)

1890 Ransom, WILLIAM BRAMWELL, M.D., The Pavement, Nottingham.

1891 RATCLIFFE, JOSEPH RILEY, M.B., C.M., The General Hospital, Birmingham.

1887 RAVEN, THOMAS FRANCIS, Broadstairs, Kent.

1870 RAY, EDWARD REYNOLDS, Dulwich Village, S.E.

1875 REID, ROBERT WILLIAM, M.D., C.M., 8, Queen's-gardens, Aberdeen.

1881 RENNER, WILLIAM, Wilberforce-street, Free Town, Sierra Leone.

1893 RENNIE, GEORGE EDWARD, 16, College-street, Hyde-park, Sydney, N.S.W.

1895 RITCHIE, JAMES, M.D., 85, High-street, Oxford.

1866 RIVINGTON, WALTER, M.S., 95, Wimpole-street, W.

1865 Roberts, DAVID LLOYD, M.D., 11, St. John's-street, Manchester.

1871 ROBERTS, FREDERICK THOMAS, M.D., 102, Harley-street, W. (C. 1883-5.)

1878 ROBERTS, WILLIAM HOWLAND, M.D., Surgeon, Madras Army.

1888 ROBERTSON, ROBERT, M.D., The Bungalow, Ventnor, Isle of Wight.

1885 ROBINSON, ARTHUR HENRY, M.D., Mile End Infirmary, Bancroft-road, N.E.

1887 ROBINSON, HENRY BETHAM, M.S., 1, Upper Wimpole-street, W. (C. 1896—.)

1882 ROBINSON, TOM, M.D., 9, Princes-street, Cavendish-square, W.

1888 ROLLESTON, HUMPHRY DAVY, M.A., M.D., 112, Harley-street, (C. 1894—.)

1858 ROSE, HENRY COOPER, M.D., 16, Warwick-road, Maida-hill, N.W. (C. 1873-4.)

1876 ROSE, WILLIAM, M.B., B.S., 17, Harley-st., W.

1875 ROSSITER, GEORGE FREDERICK, Cairo Lodge, Weston-super-Mare.

1877 ROTH, BERNARD, 29, Queen Anne-street, W.

1888 ROUGHTON, EDMUND WILKINSON, 33, Westbourne-terrace, W.

1891 ROUILLARD, LAURENT ANTOINE JOHN, M.B., Durban, Natal.

1887 ROY, CHARLES SMART, F.R.S., M.A., M.D., University of Cambridge.

1891 RÜFFER, MARC ARMAND, M.D., Medical School, Cairo, Egypt.

1895 RUSSELL, JAMES SAMUEL RISIEN, M.D., 4, Queen Anne-street, W.

1891 RUSSELL, WILLIAM, M.D., 46, Albany-street, Edinburgh.

1869 RUTHERFORD, WILLIAM, M.D., F.R.S., 14, Douglas-crescent, Edinburgh.

1853 SALTER, S. JAMES A., M.B., F.R.S., Basingfield, near Basingstoke, Hants. (C. 1861-3. V.-P. 1880-2.)

1854 SANDERSON, JOHN BURDON, M.D., D.C.L.Durham, F.R.S., 64, Banbury-road, Oxford. (C. 1864-7. V.-P. 1873-4.)

Elected

1886 SAUNDBY, ROBERT, M.D., 83A, Edmund-street, Birmingham.

1871 SAUNDERS, CHARLES EDWARD, M.D., Sussex County Lunatic Asylum, Hayward's Heath.

1890 SAUNDERS, FREDERICK WILLIAM, M.B., B.C., Chieveley House, Newbury.

1873 SAVAGE, GEORGE HENRY, M.D., 8, Henrietta-street, Cavendish-square, W. (C. 1881-3.)

1882 SAVILL, THOMAS DIXON, M.D., 60, Upper Berkeley-street, W.

1891 SCHORSTEIN, GUSTAVE ISIDORE, M.B., B.S., 11, Portland-place, W.

1894 SCHOLEFIELD, ROBERT ERNEST, M.B., 1, Eastcombe Villas, Blackheath, S.E.

1877 SEMON, FELIX, M.D., 39, Wimpole-street, W. (C. 1885-7.)

1894 SEQUEIRA, JAMES HARRY, M.D., 6, West-street, Finsbury-circus, E.C.

1872 SERGEANT, EDWARD, D.P.H., Town Hall, Preston, Lancashire.

1876 SHARKEY, SEYMOUR J., M.D., 22, Harley-street, W. (C. 1884-6. V.-P. 1895—.)

1880 SHATTOCK, SAMUEL G., 4, Crescent-road, The Downs, Wimbledon, S.W. (C. 1885-7, 1893-6. S. 1890-2. V.P. 1896—.)

1885 SHAW, LAURISTON ELGIE, M.D., 10, St. Thomas's-street, S.E.

1886 SHERRINGTON, CHARLES SCOTT, M.D., F.R.S., Holt Prof. of Physiol., University College, Liverpool. (C. 1894—.)

1856 SHILLITOE, BUXTON, 2, Frederick's-place, E.C.

1875 SIDDALL, JOSEPH BOWER, M.D., C.M., Conybeare, Northam, Bideford.

1880 SILCOCK, A. QUARRY, M.D., B.S., 52, Harley-street, W. (C. 1888-90.)

1866 SIMS, FRANCIS MANLEY BOLDERO, 12, Hertford-street, W.

1892 SLATER, CHARLES, M.B., 81, St. Ermin's Mansions, Westminster, S.W.

1887 SMALLPEICE, WILLIAM DONALD, 42, Queen Anne's-gate, S.W.

1875 Smee, ALFRED HUTCHINSON, The Grange, Hackbridge, Carshalton, Surrey.

1879 SMITH, E. NOBLE, 24, Queen Anne-street, W.

1887 SMITH, FREDERICK JOHN, M.D., 4, Christopher-street, Finsbury-square, E.C.

1875 SMITH, GEORGE JOHN MALCOLM, M.D., Hurstpierpoint, Sussex.

1894 SMITH, GUY BELLINGHAM, M.B., B.S., 24, St. Thomas's-street, S.E.

1878 SMITH, HERBERT URMSON, M.B., Cape Colony.

1873 SMITH, RICHARD T., M.D., 117, Haverstock-hill, N.W.

1883 SMITH, ROBERT PERCY, M.D., Bethlem Royal Hospital, St. George's-road, S.E.

1869 SMITH, ROBERT SHINGLETON, M.D., Deepholm, Clifton Park, Bristol.

1892 SMITH, SOLOMON CHARLES, M.D., 1, Montague Mansions, Portman-square, W.

1856 SMITH, THOMAS, 5, Stratford-place, W. (C. 1867-9. V.-P. 1877-8.)

1866 SMITH, WILLIAM, Melbourne, Australia.

1870 SMITH, WILLIAM JOHNSON, Seamen's Hospital, Greenwich, S.E. (C. 1879-81.)

1894 SNOW, HERBERT, M.D., 6, Gloucester-place, Portman-square, W.

1870 SNOW, WILLIAM VICARY, M.D., Richmond Gardens, Bournemouth.

Elected

1888 SOLLY, ERNEST, M.B., Strathlea, Harrogate, Yorks.
1868 SOUTHEY, REGINALD, M.D., 32, Grosvenor-road, S.W. (C. 1882-4.)
1887 SPENCER, WALTER GEORGE, M.S., 35, Brook-street, W. (C. 1896—.)
1888 SPICER, ROBERT HENRY SCANES, M.D., 28, Welbeck-street, W.
1861 SQUIRE, ALEXANDER BALMANNO, 24, Weymouth-street, W.
1885 SQUIRE, JOHN EDWARD, M.D., 122, Harley-street, W.
1890 STABB, EWEN CARTHEW, St. Thomas's Hospital, Albert-embankment, S.E.
1895 STARLING, ERNEST HENRY, M.D., 8, Park-sq. West, Regent's-park, N.W.
1896 STEPHENS, J. W. W., 25, East Paul's Wharf, E.C.
1891 STILES, HAROLD JALLAND, M.B., C.M., 5, Castle-terrace, Edinburgh.
1879 STIRLING, EDWARD CHARLES, Adelaide, South Australia [care of Messrs. Elder & Co., 7, St. Helen's Place, E.C.].
1883 STOKER, GEORGE, 14, Hertford-street, W.
1884 STONHAM, CHARLES, 4, Harley-street, W. (C. 1893-6.)
1875 STURGE, W. A., M.D., 29, Boulevard Dubouchage, Nice.
1871 SUTHERLAND, HENRY, M.D., 21, New Cavendish-street, W.
1867 SWAIN, WILLIAM PAUL, 17, The Crescent, Plymouth.
1881 SYMONDS, CHARTERS JAMES, M.S., 26, Weymouth-street, Portland-place, W. (C. 1886-8.)

1870 TAIT, ROBERT LAWSON, 7, The Crescent, Birmingham.
1886 TARGETT, JAMES HENRY, M.B., M.S. (HON. SECRETARY), 6, St. Thomas's-street, S.E. (C. 1894-5. S. 1895—.)
1870 TAY, WARREN, 4, Finsbury-square, E.C. (C. 1881-2.)
1871 TAYLOR, FREDERICK, M.D., 20, Wimpole-street, W. (C. 1879-81.)
1885 TAYLOR, HENRY H., 10, Brunswick-place, Brighton.
1892 TAYLOR, JAMES, M.D.Edin., 49, Welbeck-street, W.
1879 THIN, GEORGE, M.D., 63, Harley-street, W. (C. 1889-90.)
1852 THOMPSON, Sir HENRY, 35, Wimpole-street, W. (S. 1859-63. C. 1865-7. V.-P. 1868-70.)
1891 THOMSON, HENRY ALEXIS, M.D., 32, Rutland-square, Edinburgh.
1884 THOMSON, JOHN, M.B., C.M., 18, Walker-street, Edinburgh.
1894 THOMSON, ST. CLAIR, M.D., 28, Queen Anne-street, W.
1892 Thorburn, WILLIAM, B.S., 2, St. Peter's-square, and Rusholme Lodge, Rusholme, Manchester.
1874 THORNTON, JOHN KNOWSLEY, M.B., 49, Montagu-square, W.
1872 THORNTON, WILLIAM PUGIN, 35, St. George's-road, Canterbury.
1880 TIBARD, NESTOR ISIDORE, M.D., 74, Harley-street, W.
1884 TIVY, WILLIAM JAMES, 8, Lansdowne-place, Clifton, Bristol.
1882 TOOTH, HOWARD HENRY, M.D., 34, Harley-street, W. (C. 1892-4.)
1886 TOTSUKA, KANKAI, Tokio.
1872 TOWNSEND, THOMAS SUTTON, 68, Queen's Gate, S.W.
1881 TREVES, FREDERICK, 6, Wimpole-street, W. (C. 1887-90. V.-P. 1895—.)
1851 TROTTER, JOHN W., Bossall Vicarage, York. (C. 1865-9.)

Elected

1895 TROUTBECK, HENRY, M.B., B.C., 148, Ashley-gardens, S.W.
1859 TRUMAN, EDWIN THOMAS, 23, Old Burlington-street, W.
1888 TUBBY, ALFRED HERBERT, M.S., 25, Weymouth-street, Portland-place, W.
1867 TUCKWELL, HENRY MATTHEWS, M.D., 64, High-street, Oxford.
1858 TUDOR, JOHN, Dorchester, Dorset.
1875 TURNER, FRANCIS CHARLEWOOD, M.D., 15, Finsbury-square, E.C. (C. 1884-6, 1895—. S. 1891-3.)
1882 TURNER, GEORGE ROBERTSON, 49, Green-street, W.
1863 TURNER, JAMES SMITH, 12, George-street, Hanover-square, W.
1890 TURNER, WILLIAM ALDREN, 13, Queen Anne-street, W.
1893 TURNEY, HORACE GEORGE, M.B., M.Ch., 68, Portland-place, W.
1858 TURTLE, FREDERICK, Clifton Lodge, Woodford, Essex.
1880 TYSON, WILLIAM JOSEPH, M.D., 10, Langhorne-gardens, Folkestone.

1867 VENNING, EDGCOMBE, 30, Cadogan-place, S.W.
1889 VOELCKER, ARTHUR FRANCIS, M.D., B.S., 31, Harley-street, W. (C. 1895—.)

1867 WAGSTAFFE, WILLIAM WARWICK, B.A., Purleigh, St. John's-hill, Sevenoaks. (C. 1874, 1878-80. S. 1875-7.)
1885 WAKLEY, THOMAS, jun., 5, Queen's-gate, S.W.
1893 WALKER, NORMAN PURVIS, M.D., 7, Manor-place, Edinburgh.
1881 WALLER, BRYAN CHARLES, M.D., Masongill House, Cowan-bridge, Kirkby-Lonsdale.
1890 WALLIS, FREDERICK CHARLES, M.B., B.C., 26, Welbeck-street, W.
1888 WALSHAM, HUGH, M.A., M.B., B.C., 114, Harley-street, W.
1873 WALSHAM, WILLIAM JOHNSON, M.B., C.M., 77, Harley-street, W. (C. 1881-3.)
1859 WALTERS, JOHN, M.B., Reigate, Surrey.
1892 WARD, ALLAN OGIER, M.D.Edin., Lansdowne House, Tottenham.
1892 WARING, HOLBURT JACOB, M.B., M.S., 9, Upper Wimpole-street, W.
1889 WASHBOURN, JOHN WYCHENFORD, M.D., 15, Trinity-square, S.E.
1891 WATERHOUSE, HERBERT FURNIVALL, M.D., C.M., 81, Wimpole-street, W.
1892 WEAVER, FREDERICK POYNTON, M.D., Cedar Lawn, Hampstead Heath, N.W.
1890 WEBB, CHARLES FRERE, M.D., New-street House, Basingstoke.
1894 WEBER, FREDERICK PARKES, M.D., 19, Harley-street, W.
1858 WEBER, HERMANN, M.D., 10, Grosvenor-street, W. (C. 1867-70. V.-P. 1878-80.)
1864 WELCH, THOMAS DAVIES, M.D., Fairmount, Frith-hill, Godalming, Surrey.
1894 WELLS, SYDNEY RUSSELL, M.B., 24, Somerset-street, Portman-square, W.
1892 WESBROOK, FRANK F., M.D. (Winnipeg), Cambridge.
1851 WEST, CHARLES, M.D., 4, Evelyn Mansions, Carlyle-place, Victoria-street, S.W. (C. 1856-7.)

Elected

1877 West, Samuel, M.D., 15, Wimpole-street, W. (C.1884-6, 1891-3. S. 1889-90. V.-P. 1896—.)

1888 Wetherred, Frank J., M.D., 83, Harley-street, W.

1891 Wheaton, Samuel Walton, M.D., 76, The Chase, Clapham Common, S.W.

1867 Whipham, Thomas Tillyer, M.D., 11, Grosvenor-street, W. (C. 1880-2.)

1869 Whipple, John H. C., M.D., Army Medical Staff.

1877 White, Charles Haydon, 20, Shakespeare-street, Nottingham.

1894 White, Charles Powell, 67, Queen-street, E.C.

1891 White, Gilbert B. Mower, M.B., B.S., 112, Harley-street, W.

1881 White, William Hale, M.D., 65, Harley-street, W. (C. 1888-90.)

1886 White, William Henry, M.D., 43, Weymouth-street, W.

1868 **Whitehead**, Walter, 24, St. Ann's-square, Manchester.

1897 Whitfield, Arthur, M.D., 12, Upper Berkeley-street, Portman-square, W.

1877 Whitmore, William Tickle, 7, Arlington-street, S.W.

1870 Wickstead, Francis William, Chester House, Weston-super-Mare.

1869 Wilkin, John F., M.D., M.C., Rose Ash House, South Molton, N. Devon.

1871 Wilkinson, J. Sebastian, New Zealand.

1855 **WILKS**, Samuel, M.D., F.R.S. (Trustee), 72, Grosvenor-street, W. (C. 1857-60. V.-P. 1869-72, 1883-5. P. 1881-2.)

1879 Willcocks, Frederick, M.D., 14, Mandeville-place, W.

1886 Willett, Edgar William, M.B., 25, Welbeck-street, W.

1869 Williams, Albert, M.D. (Travelling).

1858 **Williams**, Charles, 48, Prince of Wales-road, Norwich.

1866 Williams, Charles Theodore, M.D., 2, Upper Brook-street, W. (C. 1875-8.)

1881 Williams, Dawson, M.D., B.S., 101, Harley-street, W. (C.1893-6.)

1872 Williams, Sir John, Bart., M.D., 63, Brook-street, W. (C. 1878-80.)

1881 Williams, W. Roger, 28, Winckley-square, Preston.

1876 Williamson, James Mann, M.D., Ventnor, Isle of Wight.

1863 Willis, Francis, M.D., The Spa, Braceborough, Stamford.

1889 Wilson, Albert, Leytonstone, Essex.

1888 Wilson, Claude, M.D., C.M., 6, York-road, Tunbridge Wells.

1859 Wilson, Edward Thomas, M.B., Montpelier-terrace, Cheltenham.

1891 Wilson, Theodore Stacey, M.B., C.M., 65, Temple-row, Birmingham.

1861 **Windsor**, Thomas, Medical Library, Boston, Mass., U.S. [care of R. F. Stevens, 4, Trafalgar-square, W.].

1889 Wingrave, V. Harold Wyatt, 11, Devonshire-street, Portland-place, W.

1874 Wiseman, John Greaves, Dearden-street, Ossett, Yorkshire.

1865 Witherby, William H., M.D., Pitt-place, Coombe, Croydon.

1883 Woodcock, John Rostron, 155, Hagley-road, Birmingham.

Elected

1883 WOODHEAD, GERMAN SIMS, M.D., Beverley, 1, Nightingale-lane, Balham, S.W. (C. 1891-3.)

1879 WOODWARD, G. P. M., M.D., Deputy Surgeon-General; Sydney, New South Wales.

1884 WORTS, EDWIN, 6, Trinity Street, Colchester.

1869 WYMAN, WILLIAM S., M.D., Red Brae, 18, Putney-hill, S.W.

1890 WYNNE, EDWARD T., M.B., 7, Rochester-gardens, Hove, Brighton.

1884 WYNTER, WALTER ESSEX, M.D., 30, Upper Berkeley-street, W.

1872 YOUNG, HENRY, M.B., Monte Video, South America.

ANNUAL REPORT OF COUNCIL, 1895-96.

PRESENTED AT THE ANNUAL MEETING, MAY 19TH, 1896.

YOUR Council has to report the admission of twelve new members, and the election as honorary members of Dr. C. Bouchard, Dr. R. Koch, Dr. W. H. Welch, and Dr. E. Ziegler.

There have been six resignations.

The Society now numbers 708 ordinary members.

The Society have lost by death Prof. Pasteur, member of the Institute, Paris, one of its honorary members, Dr. J. S. Bristowe, Mr. Frank Vigers Bunch, Mr. T. C. Frere, Dr. William Wilberforce Smith, Sir John Tomes, and Dr. Archibald Weir.

Dr. John Syer Bristowe joined the Society in 1851, and held the offices of Secretary, Vice-President, and President. In former years he took an active part in the proceedings of the Society, and has made many valuable contributions to the 'Transactions.'

Mr. T. C. Frere was an original member of the Society.

During the past session two evenings were set apart for special subjects: one evening was devoted to the discussion of "Ankylosis of Joints without Suppuration," when a number of illustrative specimens from the various museums were brought together; and another to the "Anatomical Results of the Radical Cure of Hernia."

The present is the fiftieth session of the Society; it is proposed to celebrate the Jubilee of the Society at the commencement of next

session, when the President will review the history of the last fifty years, and a conversazione will be held.

The income for the current year was £467 17s. 11d., and the expenditure £508 9s. 1d., showing an excess of expenditure over income, deducting £5 5s. for a life composition fee, of £45 16s. 2d. This apparent deficit is mainly due to the large number of subscriptions which remain unpaid.

The amount of money invested in Consols is £1214 3s. 2d.

The present balance in hand is £99 7s.

HENRY T. BUTLIN.

THE PATHOLOGICAL SOCIETY OF LONDON.

Statement of Receipts and Payments for the Year ending 30th April, 1896.

SIDNEY COUPLAND, Esq., M.D., *Treasurer.*

RECEIPTS.

	£	s.	d.	£	s.	d.
Balance in hand on 1st May, 1895				139	18	2
347 Subscriptions at £1 1*s.*	364	7	0			
12 Admissions at £1 1*s.*	12	12	0			
3 Non-Resident Admissions at £3 3*s.*	9	9	0			
1 Life Composition Fee	5	5	0			
				391	13	0
Sale of Transactions:						
By Publisher	40	5	9			
By Adlard and Son	3	13	6			
				43	19	3
Dividends on Consols				32	5	8
				£607	16	1

PAYMENTS.

	£	s.	d.	£	s.	d.
Meetings:						
Expenses of Rooms to Christmas, 1895	105	0	0			
Refreshments, Attendance, &c.	26	15	0			
Microscopes	11	17	6			
Reporting Meeting of February 18th, 1896	3	14	4			
				147	6	10
Transactions:						
Printing, Binding, &c., of Vol. XLVI	173	7	8			
Illustrations	114	4	0			
				287	11	8
Secretariat and Treasury:						
Assistant Secretary	21	0	0			
Collection of Subscriptions	15	15	0			
Addressing Circulars, &c.	2	0	0			
Sundry Printing and Stationery	17	8	3			
Bank Charges	0	4	2			
Petty Cash—Hon. Sec. £6 2 6; Assist. Sec. 11 0 8	17	3	2			
				73	10	7
				508	9	1
Balance—						
At Bank	95	19	2			
Petty Cash in hand	3	7	10			
				99	7	0
				£607	16	1

Audited and found correct, 15th May, 1896.

H. MONTAGUE MURRAY, WALTER G. SPENCER, } *Auditors.*

SIDNEY COUPLAND, *Treasurer.* HENRY T. BUTLIN, *President.* G. NEWTON PITT, *Hon. Sec.*

LIST OF SPECIMENS AND REPORTS

BROUGHT BEFORE THE SOCIETY DURING THE SESSION 1895–6.

I. DISEASES, ETC., OF THE NERVOUS SYSTEM.

PAGE

1. Case of syphilitic gummata of the brain
By Cecil F. Beadles 1
2. Psammoma of the dura mater (Card specimen)
By J. H. Targett, M.S. 3

II. DISEASES, ETC., OF THE ORGANS OF RESPIRATION.

1. Traumatic rupture of the branch of the right bronchus leading to the upper lobe of the lung; pneumothorax and subcutaneous emphysema (Card specimen)
By Hector W. G. Mackenzie, M.D. 5
2. Polypoid growth of the trachea By Cyril Ogle, M.B. 6
3. A case of pneumonomycosis [With Plate I]
By C. J. Arkle, M.D., and F. Hinds, M.D.

III. DISEASES, ETC., OF THE ORGANS OF CIRCULATION.

1. Heart from a fatal case of angina pectoris, with thrombosis of the right coronary artery (Card specimen)
By F. Parkes Weber, M.D. 14

PAGE

2. Heart with obliteration of the commencement of the right coronary artery; no angina pectoris
By F. Parkes Weber, M.D. 16
3. The heart from a case of angina pectoris, showing stenosis of the coronary arteries; old partial thrombosis in the basilar artery; commencing lardaceous change in the various organs
By F. Parkes Weber, M.D. 18
4. Cardiac aneurysm (Card specimen)
By Cyril Ogle, M.B. 22
5. Aneurysm or gumma of heart (Card specimen)
By Cyril Ogle, M.B. 23
6. Embolic aneurysms of the heart, buttock, and axilla (Card specimen) By J. Jackson Clarke, M.B. 24
7. Stenosis of the pulmonary orifice of the heart (Card specimen) By Hugh Walsham, M.B. 25
8. Syphilitic disease (?) of the ascending aorta and sigmoid valves By P. H. Pye-Smith, M.D. 26
9. Atresia of the pulmonary artery (Card specimen)
By Cyril Ogle, M.B. 28
10. Embolism of the coronary artery (Card specimen)
By Cyril Ogle, M.B. 29
11. Aneurysm of the right inferior thyroid artery; abnormal distribution of vessels (Card specimen)
By John R. Lunn 30
12. Cured aneurysm of the external iliac artery (Card specimen) By Douglas Drew 32
13. Rupture of the inner coat of the abdominal aorta (Card specimen) By Arthur Voelcker, M.D. 33

IV. DISEASES, ETC., OF THE ORGANS OF DIGESTION.

1. Malignant disease of the tonsil (Card specimen)
By Lennox Browne 34
2. Congenital occlusion of the œsophagus (Card specimen)
By Bilton Pollard, B.S. 36

PAGE

3. Simple dilatation of the œsophagus
By H. D. Rolleston, M.D. 37
4. Diphtheria of the œsophagus (Card specimen)
By E. W. Goodall, M.D. 39
5. Sarcoma of the œsophagus By Cyril Ogle, M.B. 40
6. Extensive malignant ulceration of the œsophagus
By J. H. Targett, M.S. 41
7. Epithelioma of the œsophagus invading the trachea and left bronchus; extensive cystic degeneration of the secondary deposits in the liver and stomach (Card specimen) By Arthur F. Voelcker, M.D. 43
8. Epithelioma in an œsophageal pouch
By G. Newton Pitt, M.D. 44
9. Dilatation of the stomach (Card specimen)
By R. G. Hebb, M.D. 45
10. Multiple polypi of stomach and intestine
By William Collier, M.D. 46
11. Tuberculous ulceration of the ileum with perforation (Card specimen) By Hugh Walsham, M.B. 47
12. A diverticulum ilei of unusual length and position (Card specimen) By Bilton Pollard, B.S. 47
13. A diverticulum ilei attached to the mesentery (Card specimen) By Hugh Walsham, M.B. 48
14. Caseous mass attached to the cæcum (Card specimen)
By Hugh Walsham, M.B. 48
15. Three cases of ulcerative appendicitis
By William Hunter, M.D. 49
16. A vermiform appendix eight inches long containing a concretion (Card specimen) By W. J. Tyson, M.D. 51
17. Mucous casts of the large intestine, passed during several months, in a case of cancer of the colon, with great hypertrophy of the bowel above the seat of stricture By P. H. Pye-Smith, M.D. 52
18. Extensive ulceration of the large intestine in a case of enteric fever (Card specimen)
By Arthur F. Voelcker, M.D. 54
19. The parts concerned in the radical cure of inguinal hernia six months after the operation
By Henry T. Butlin 54

PAGE

20. The parts concerned in the radical cure of inguinal hernia two years after the operation
By James Berry, B.S. 56
21. Case of infantile hernia on which radical cure was performed (MacEwen's method); death five days after operation By C. H. Golding-Bird 56
22. Case of hour-glass constriction of the sac of a femoral hernia
By Macpherson Laurie (per J. H. Targett, M.S.) 59
23. Pedunculated cysts pendent within a hernial sac
By C. B. Lockwood 61
24. Tuberculous liver with lardaceous disease (Card specimen) By Hugh Walsham, M.B. 65
25. Circumscribed fatty patches in the liver (Card specimen) By F. Parkes Weber, M.D. 65
26. Perihepatitis; thrombosis of inferior vena cava at point of entry of hepatic veins; ascites and great varicosity of superficial veins over anterior thoracic and abdominal parietes (Card specimen)
By Frederick Willcocks, M.D. 67
27. Loose body in a depression on the convex surface of the liver (Card specimen) By H. D. Rolleston, M.D. 68
28. The relation of biliary calculi to malignant disease of the liver and gall-bladder By Cecil F. Beadles 69
29. Gall-stone impacted in the small intestine; removal by laparotomy By J. Hutchinson, jun. 94
30. Acute tuberculosis of spleen; splenectomy; recovery.
By C. H. Marriott (per J. H. Targett, M.S.) 96
31. Hæmorrhage near pancreas with fat necrosis (Card specimen) By Cyril Ogle, M.B. 98
32. A specimen illustrating a rare method of formation of intra-abdominal bands By J. Hutchinson, jun. 100
33. Calculi of calcium oxalate from a cyst of the pancreas
By Samuel G. Shattock 101

V. DISEASES OF THE GENITO-URINARY ORGANS.

PAGE

1. Atrophy of the kidney from stricture (? congenital) of the ureter (Card specimen)
By G. Newton Pitt, M.D. 113
2. Case of large white kidneys with thrombosis of the renal veins and the inferior vena cava (Card specimen)
By Theodore Fisher, M.D. (per J. H. Targett, M.S.) 113
3. Case of bilateral sarcoma of the hilum of the kidney (Card specimen)
By Theodore Fisher, M.D. (per J. H. Targett, M.S.) 115
4. Diffuse symmetrical lympho-sarcomatous infiltration of the kidneys of a child; with deposits in the cæcum, diaphragm, &c. (Card specimen)
By F. Parkes Weber, M.D. 117
5. Large sarcoma of the kidney. (Card specimen)
By J. D. Malcolm 119
6. Adrenal tumours of the kidney [With Plate II]
By J. H. Targett, M.S. 122
7. Epithelioma of the ureter causing hydronephrosis
By Henry Rundle, F.R.C.S. (per J. H. Targett, M.S.) 128
8. A case of spontaneous fracture of uric acid calculi
By Charles B. Plowright, M.D. (per W. M. Ord, M.D.) 132
9. Case of congenital deficiency of the abdominal muscles, with dilatation and hypertrophy of the bladder and ureters By Leonard Guthrie, M.D. 139
10. Case of lymph-scrotum [With Plate III]
By Johnson Smith 145
11. Diffuse interstitial syphilitic orchitis
By H. Betham Robinson, M.S. 146
12. A dermoid tumour of the testis
By J. Jackson Clarke, M.B. 148
13. Malignant tumour of the spermatic cord (? carcinoma)
By John H. Morgan 150

PAGE

14. Case of glandular enlargement of the prostate; excision of both testicles eight months before death.
By N. Davies-Colley 152
15. Carcinoma of the prostate (Card specimen)
By R. G. Hebb, M.D. 154
16. Diverticula of the bladder associated with vesical growths [With Plates IV, V, VI] By J. H. Targett, M.S. 155
17. Primary colloid carcinoma of bladder (Card specimen)
By H. C. Sharp, M.D. (per J. H. Targett, M.S.) 168
18. Case of primary sarcoma of the vagina in a child, associated with multiple polypi By D'Arcy Power, M.B. 169
19. Uterus unicornis with congenital malposition of the right kidney (Card specimen)
By Arthur Voelcker, M.D. 173

VI. DISEASES, ETC., OF THE ORGANS OF LOCOMOTION.

1. Traumatic separation of the epiphysis of the great trochanter (Card specimen) By J. Hutchinson, jun. 174
2. Old injury of humerus from an Egyptian mummy
By J. H. Targett, M.S. 174
3. The pathology of hypertrophic pulmonary osteo-arthropathy [With Plate VII]
By William Thorburn and F. H. Westmacott 177
4. Case of osteitis deformans
By F. J. Fielder (per J. H. Targett, M.S.) 190
Discussion on Non-suppurative Ankylosis of Joints. By Mr. William Anderson, Sir George M. Humphry, Mr. Howard Marsh, Mr. Davies-Colley, Mr. Griffiths, Mr. D'Arcy Power, Mr. C. A. Morton, Mr. Jackson Clarke, and Mr. Targett 193—222

VII. DISEASES, ETC., OF THE DUCTLESS GLANDS.

PAGE

1. Cystic accessory thyroid body [With Plate IX] By WALTER EDMUNDS 223
2. Accessory thyroid body By CYRIL OGLE, M.B. 224
3. Sequel of a case of cystic accessory thyroid body in which four operations for recurrence were performed in the course of six years By ARTHUR E. BARKER 225
4. Multiple exogenous adenomata of the thyroid body By SAMUEL G. SHATTOCK 231
5. On the transformation of solid thyroid adenomata into cysts By JAMES BERRY, B.S. 234
6. Further observations and experiments on the pathology of Graves's disease [With Plates VIII and IX] By WALTER EDMUNDS 235

VIII. DISEASES, ETC., OF THE SKIN.

1. Crateriform ulcer of face (Card specimen) By H. D. ROLLESTON, M.D. 240
2. Two simultaneous squamous-celled carcinomata (Card specimen) By H. D. ROLLESTON, M.D. 241
3. An anomalous tumour (? adenoma) of sebaceous glands [With Plate XII, fig. A.] By H. D. ROLLESTON, M.D. 242

IX. MORBID GROWTHS.

1. Saponifying necrosis in a lipoma of the thigh (Card specimen) By SAMUEL G. SHATTOCK 246
2. Saponifying necrosis in a lipoma of the breast (Card specimen) By J. H. TARGETT, M.S. 248
3. Encysted fatty concretions in a breast affected by chronic mastitis By W. WATKINS-PITCHFORD, M.B. (per S. G. SHATTOCK) 249

PAGE

4. Macrodactyly due to diffuse lipoma
By Robert Jones (per D'Arcy Power) 252
5. Osteomata from the scalp (Card specimen)
By Sydney Jones 255
6. Lymphangioma cavernosum from the parotid region (Card specimen) By H. Betham Robinson, M.S. 255
7. Loose bodies from a subdeltoid bursa (Card specimen)
By J. Jackson Clarke, M.B. 257
8. Syphilitic lesions of lymphatic glands
By J. Jackson Clarke, M.B. 257
9. The non-existence of "round-celled sarcoma" as a distinct class of new growths By Herbert Snow, M.D. 259
10. Chondrifying sarcoma of the humerus following upon a fracture By Samuel G. Shattock 261
11. Sarcoma of mamma containing multinuclear giant-cells (Card specimen) [With Plate II, fig. A]
By H. D. Rolleston, M.D. 267
12. Case of (?) metastatic sarcoma of both breasts; multinucleated giant-cells in the growth (Card specimen)
By E. L. Fox (per J. H. Targett, M.S.) 269
13. Secondary sarcomatous growth in the mamma (Card specimen) By H. D. Rolleston, M.D. 272
14. Three cases of carcinomatous cyst of the breast
By Charters J. Symonds, M.S. 273
15. Carcinomatous cyst of the breast (Card specimen)
By W. S. Sprent (per J. H. Targett, M.S.) 277
16. Carcinomatous cysts of the breast
By Cecil F. Beadles 278
17. Carcinoma of the mamma associated with a large cyst (Card specimen) By H. D. Rolleston, M.D. 284
18. Cystic disease of both breasts, with scirrhus carcinoma in the right breast By H. Betham Robinson, M.S. 285
19. Hæmorrhagic duct-cancer of the breast (Card specimen)
By Rutherford Morison (per J. H. Targett, M.S.) 288
20. Malignant tumour from ischio-rectal region of a fox terrier (Card specimen) By C. S. Wallace 290
21. On sarcomata of the bladder and their classification [With Plates V, X, XI] By J. H. Targett, M.S. 291

X. MISCELLANEOUS COMMUNICATIONS.

PAGE

1. Acute nephritis due to oxalic acid poisoning
By W. HALE WHITE, M.D. 312
2. Notes on the occurrence of large quantities of hæmatoporphyrin in the urine of patients taking sulphonal
By ARCHIBALD E. GARROD, M.D., and F. GOWLAND HOPKINS, M.B. 316
3. On the xerosis bacillus [With Plate XV]
By J. EYRE, M.D. 334
4. Diphtheria and pseudo-diphtheria bacilli
By E. A. PETERS, M.D. 345
5. Diphtheria bacilli in a cultivation from the throat twenty-two weeks after the primary attack; bacilli markedly virulent (Card specimen) By R. T. HEWLETT 360
6. The escape of diphtheria bacilli into the blood and tissues
By A. A. KANTHACK and J. W. W. STEPHENS 361
7. Cultural variation in *Streptococcus pyogenes bovis* [With Plate XII] By SAMUEL G. SHATTOCK 375
8. Microscopic preparations of *Streptothrix Maduræ*
By C. G. SELIGMANN (per S. G. SHATTOCK) 379
9. Extensive hæmorrhage associated with the presence of pyogenic micro-organisms
By RAYMOND JOHNSON, M.B. 382
10. An undescribed form of hæmatozoon [With Plate I, fig. A] By NORMAN MOORE, M.D. 384
11. The healing of incisions in vegetable tissues [With Plates XIII and XIV] By SAMUEL G. SHATTOCK 387

REPORTS OF THE COMMITTEE ON MORBID GROWTHS.

PAGE

1. On Dr. Cyril Ogle's specimen of growth of the trachea. [ANTHONY A. BOWLBY and R. G. HEBB] 7
2. On Dr. Cyril Ogle's specimen of sarcoma of the œsophagus. [WALTER G. SPENCER and J. H. TARGETT] 41
3. On Mr. Morgan's specimen of malignant tumour of the spermatic cord. [W. G. SPENCER and J. H. TARGETT] 152
4. On Mr. Arthur E. Barker's specimen of cystic accessory thyroid body. [JAMES BERRY, ANTHONY A. BOWLBY, and SAMUEL G. SHATTOCK] 229

LIST OF PLATES.

		TO FACE PAGE
I.	Pneumonomycosis. (C. J. Arkle and F. Hinds.) (Page 8)	10
II.	Adrenal Tumours of the Kidney. (J. H. Targett.) (Page 122)	124
III.	Lymph-scrotum. (Johnson Smith.) (Page 145)	146
IV—VI.	Diverticula and Growths of Bladder. (J. H. Targett.) (Page 155)	156, 160, 164
VII.	Hypertrophic Pulmonary Osteo-arthropathy. (W. Thorburn and F. H. Westmacott.) (Page 177)	186
VIII, IX.	Pathology of Graves's Disease. (W. Edmunds.) (Page 235)	238
X, XI.	Sarcomata of the Bladder. (J. H. Targett.) (Page 291)	304
XII.	Cultural Variation in *Streptococcus pyogenes bovis*. (S. G. Shattock.) (Page 375)	378
XIII, XIV.	Healing of Incisions in Vegetable Tissues. (S. G. Shattock.) (Page 387)	400
XV.	Xerosis bacillus. (J. Eyre.) (Page 334)	410

LIST OF FIGURES IN THE TEXT.

PAGE

1. Pneumonomycosis 10
2. Infantile hernia 58
3, 4. Cysts in herniial sac 62
5. Malignant disease of liver 91
6. Epithelioma of ureter 130
7—9. Deficiency of abdominal muscles . 139, 141, 142
10, 11. Sarcoma of vagina 170, 171
12—17. Hypertrophic pulmonary osteo-arthropathy 179, 182—185, 187
18. Macrodactyly 252
19. Sarcoma of bladder 294
20—25. Healing of incisions in vegetable tissues 391, 392, 397, 402, 406, 407

REPORT.

SESSION 1895-1896.

I. DISEASES, ETC., OF THE NERVOUS SYSTEM.

1. *Case of syphilitic gummata of the brain.*

By Cecil F. Beadles.

The patient, aged 28, was admitted into Colney Hatch Asylum in a state of acute mania. He had been a 'bus driver, but formerly a soldier, and was invalided home from India four years before with enteric fever. While there he had contracted syphilis, and now exhibited signs of having had the disease very severely, being scarred all over the back, arms, legs, and feet. He was greatly run down in health, and was much emaciated. There were no signs of heart or lung disease.

His mental state had existed for two weeks, and he had been so restless and excited that confinement in a padded room had been necessary, and he was brought to the asylum in a strait jacket: for some days past he had taken but little food. There was no history of insanity in the family.

When seen he was quite incoherent and extremely restless; he was said to have delusions of being mesmerised, was dead at one moment, and the Prince of Wales the next, but it was impossible now to make out anything of the kind. After his admission he continued in the same restless state, throwing himself about, not sleeping at night, but shouting and singing and refusing his food. It was necessary to feed him by the œsophageal tube on several occasions. Large doses of bromide and chloral produced no effect. A half-grain of hyoscyamine entirely failed to give sleep, and it was only after one grain hypodermically that slight rest was obtained.

At the end of a fortnight he quieted down a little, took his food better, and got out of doors, but he continued to throw himself about, and was greatly addicted to masturbation: he continued on bromide night and morning. A couple of weeks later he was

placed on an iron tonic and gained somewhat in strength, but there was no sign of mental improvement; he remained quite incoherent. He was always able to walk, and there was no sign of paralysis, although general weakness.

Just short of three months from his admission he had what seemed to be a hæmorrhagic seizure. After washing himself in the morning he suddenly fell down, became unconscious and blue all over; within half an hour he had recovered consciousness, said he felt better, and there was no indication of paresis. An hour later he again relapsed into unconsciousness and lay quiet, except for foaming at the mouth, was of a natural colour, pulse very slow and intermittent, and scarcely felt at apex; right pupil widely dilated, left contracted to a pin's point. Eight hours later he was breathing quietly, pulse had slightly improved, both pupils widely dilated and equal. He died fourteen hours from the onset of the attack, not having again recovered consciousness.

After death there was found a very slight degree of atheroma of the cardiac valves and of the aorta; a deep scar existed on the surface of the spleen, and the kidneys were hard and slightly granular, but not reduced in size. The membranes of the brain were only slightly thickened, and the blood-vessels were fairly healthy. Beneath the right frontal lobe about its centre a hard mass could be felt; it did not project externally. This readily separated from the brain substance, and was found to be a small tumour, firm, of darker colour than the brain tissue, three quarters of an inch in diameter, and connected with the pia mater.

The brain throughout was softer than natural, but the floor of the lateral ventricle on the left side with the whole of the basal ganglia was found in an excessively softened and disorganised state. This half of the ventricle was more dilated than the right, and the hemisphere had a generally swollen appearance. On making vertical sections through the lower part of the left hemisphere there was discovered a second tumour, of similar appearance and size to the other. It was situated at the inner and lower part of the lenticular nucleus on a level immediately in front of the optic commissure, and was closely connected with the middle cerebral artery.

Microscopically these growths were granulomata, composed of round-cell infiltration with areas of caseation and necrotic tissue, and were undoubtedly syphilitic gummata.

Now, notwithstanding the frequency of syphilis as a cause of

insanity—a frequency, however, which in this country we do not recognise as anything like so great as do alienists upon the Continent, especially in the production of general paralysis,—we rarely discover gummatous growths in the brain after death; in fact, the rarity with which they are found is almost phenomenal. I have been able to look over the *post-mortem* notes recording the conditions present in the brain of 4000 insane persons, and in only five instances is it stated that gummata were present. In the forty instances of all varieties of intra-cranial growths mentioned there are possibly a couple more of doubtful cases that may have been of syphilitic origin. It is possible that in some instances gummata may disappear entirely, but from the above figures it is highly probable that gummatous growths are even rarer than is usually supposed, and symptoms referred to their presence may, in fact, be due to changes in the vessels and membranes, or to their secondary effects on the nervous tissue.

January 7th, 1896.

---

2. *Psammoma of the dura mater.* (*Card specimen.*)

By J. H. Targett, M.S.

The specimen consists of a rounded tumour removed from the parietal lobe of a left cerebral hemisphere. It measures 3 inches in diameter, and weighs 8½ oz. The external surface is markedly lobulated all over except superiorly, where it is much flattened and intimately blended with the dura mater, having indented the parietal bone by pressure. Portions of the cerebral cortex and pia-arachnoid membrane are firmly adherent to the surface of the tumour, and in the deep grooves between its lobules. The cut surface shows that the substance of the growth is chiefly composed of dense fibrous tissue extensively infiltrated with a spongy calcareous material.

Microscopical examination.—The stroma of the growth is composed of nucleated spindle-celled tissue well supplied with vessels, and it may be described as fibrous rather than sarcomatous. Dispersed through the stroma are a large number of calcareous bodies, of

various sizes and shapes. These are so numerous that thirty or more may be counted in any field of the section. The majority are rounded or oval in shape, but not a few are cut longitudinally, and thus appear as irregular or branched columns. The larger bodies have resulted from aggregation of the smaller ones; hence their cut surfaces frequently exhibit the outlines of the component nodules. Each body is surrounded with nucleated fibre cells in the form of a capsule. Very few of them show the concentric lamination which is usually described. The process of development of the bodies would seem to be the deposition of small homogeneous calcareous particles between the cells of the stroma, which subsequently adhere and form larger bodies.

History.—The specimen was removed from a woman aged 67, who died suddenly in bed. She had suffered from right hemiplegia for nearly twenty years. The following account of the case was obtained from the friends of the deceased by Dr. William Lee, who presented the specimen to the College of Surgeons' Museum (No. 3788B).

"When the deceased was forty-eight years old she experienced the sensation of pins and needles in the *left* foot (the tumour was on the *left* side of the skull). This was followed in a day or two by numbness and deadness of the left foot, and subsequently by signs of an apoplectic stroke affecting the *right* side. After a year's illness she was able to walk a little, but she never regained the use of the *right* arm. Since that occurrence the woman had always been an invalid, but had been better on the whole during the last five years of life than in the preceding ten years. Ultimately she became quite helpless as regards the lower extremities, and for some months before death she had to be lifted in and out of bed every day, though she was able to feed herself. The patient was as well as usual the day before her death: she wandered a little in her mind when she was put to bed, but fell asleep and died without waking."

Dr. Lee first saw the woman on October 1st, 1886, when she had right hemiplegia, which was thought to be due to a left cerebral hæmorrhage. The paralysis was confined to the right side, but her daughter was quite certain that the symptoms commenced in the *left* foot. She was attended from time to time till March, 1890, and was then lost sight of. Her death occurred in January, 1895, at the age of sixty-seven years. *May 5th*, 1896.

II. DISEASES, ETC., OF THE ORGANS OF RESPIRATION.

1. *Traumatic rupture of the branch of the right bronchus leading to the upper lobe of the lung; pneumothorax and subcutaneous emphysema.* (*Card specimen.*)

By Hector W. G. Mackenzie, M.D.

There is a longitudinal rupture about a third of an inch long on the upper surface of the branch of the right bronchus leading to the upper lobe of the right lung. This led directly into the pleural cavity, and was attended with pneumothorax and complete collapse of the whole of the right lung, which lay at the lower and posterior part of the cavity. The pleura was lined with a thick layer of inflammatory lymph, and its cavity contained about a pint of turbid brownish fluid, in addition to air. The lesion in the bronchus was unaccompanied by any injury to the ribs, although there was some bruising over the front of the thorax, with subcutaneous effusion of blood. The bronchial glands below the bifurcation of the trachea were enlarged, and partly tubercular and caseating. The affected glands were not, however, near the ruptured bronchus, and therefore could have had nothing to do in the way of predisposing to its rupture. There were two other injuries the right clavicle being dislocated forwards at its sternal end, and the upper epiphysis of the right humerus being completely separated from the shaft and communicating with the surface through a lacerated wound of the shoulder.

The specimen is from a boy aged 12, who fell off a van, and was run over, fourteen days before death. He was admitted the same day to the hospital. He first developed subcutaneous emphysema over the front of the chest, and fracture of ribs was suspected although no crepitus could be detected. The emphysema spread to the neck and face, and then gradually subsided. About the end of the first week signs of pneumothorax on the right side were clearly

made out. Aspiration was performed, and a good deal of air was let out with relief to the patient. The improvement was only temporary, and the patient gradually became weaker and died.

The case is interesting on account of the rarity of rupture of bronchus without rib injury. Dr. Rolleston records a case of complete rupture of the right bronchus in vol. xlii, and Mr. Sheild a similar case of rupture of the left in vol. xl of the Society's 'Transactions.' In both these instances the ribs were fractured, and the injuries proved almost immediately fatal. It is difficult to explain the mechanism of rupture in the case where the ribs themselves are uninjured. *December 3rd*, 1895.

---

2. *Polypoid growth of the trachea.*

By Cyril Ogle, M.B.

The specimen shows the larynx and trachea of a child. A recent tracheotomy wound is seen, and above it a soft round growth, of the size of a small dried pea, projects inwards by a slender pedicle from the anterior wall at the level of the cricoid cartilage. Below the wound a scar is seen on the inside of the trachea in the middle line.

Clinical history.—The child, aged 1¼ years, was admitted for diphtheria; tracheotomy was performed for laryngeal dyspnœa. At the end of a month it left the hospital one morning apparently well, but was readmitted the same evening in a moribund condition with stridor, the mother stating that the child had experienced in the afternoon some difficulty of breathing of spasmodic nature; on a recurrence of this she had brought it back to the hospital. Although nearly dead tracheotomy was a second time performed, but the child did not recover its breathing under artificial respiration.

The growth is attached by a very fine pedicle at the seat of the original tracheotomy wound. It seemed at first, at the autopsy, that this was not the case, for on examining the trachea just below the recent tracheotomy aperture a distinct scar is seen upon the anterior wall of the tube: but the original tracheotomy was performed high up, and this is borne out by the presence of strong

adhesion of the tissues in front to the cricoid and upper part of the trachea, just at the level of the polypus; so that the lower scar must be attributed to ulceration caused by the end of the old tracheotomy tube. I have recently come across a good example of this condition of an ulcerated patch covered by membrane and caused by the end of a tracheotomy tube, and this I have placed for comparison beside the specimen above described.

There appears to be no doubt that the child had laryngeal diphtheria on the former occasion. The obstruction to breathing which caused its death might have arisen from catarrhal swelling set up by cold on leaving the hospital, with consequent impaction of the polypus in the cartilaginous ring of thyroid and cricoid: there may have been spasm in addition. I have not met with the description of a similar case, and I should be glad of any expression of opinion as to the mode of origin of the growth, and whether it can be attributed to any fault in the performance of the original tracheotomy.

March 17*th*, 1896.

Report of the Morbid Growths Committee on Dr. Cyril Ogle's specimen of growth of the trachea.—The specimen submitted to us consists of the trachea and adjacent parts from a young child. There is a tracheotomy wound commencing about a quarter of an inch from the upper end of the trachea, and, separated from the upper end of this wound by a small area of normal mucous membrane, is a minute growth the size of a large pin's head, attached by a very slender pedicle to the mucous membrane in the middle line upon the anterior wall of the trachea. The surface of this growth is smooth. The growth and the surrounding mucous membrane were removed, and sections were cut in paraffin and stained with hæmatoxylin. These sections show that the growth is a small polypoid tumour with a smooth surface, consisting of loose fibrous tissue rich in vessels, and showing no trace of granulation tissue. We consider the growth to be a polypus, and do not think that so minute a tumour in this situation could have been the cause of any serious symptoms during life. Some members of the committee were of opinion that the tumour might have arisen in connection with the first tracheotomy.

ANTHONY A. BOWLBY.
R. G. HEBB.
S. G. SHATTOCK, *Chairman.*

3. *A case of pneumonomycosis.*

By C. J. Arkle, M.D., and F. Hinds, M.D.

[With Plate I.]

History of case.—The patient was an agricultural labourer, aged 22, whose occupation consisted chiefly in leading a team of horses in a cart in one of the healthiest parts of Sussex. He did not remember any previous illness.

His occupation did not entail any great exertion or the lifting of heavy weights, and it was, of course, carried on in the open air. He did not play any musical wind instrument. His parents were both living, and his family history was very good.

Present illness.—In October, 1892, he walked some little distance to his doctor's house, and complained that he had been feeling "poorly" and suffering from shortness of breath for about a week. He had been quite strong and well up to that time.

On examination it was noted:—He is much cyanosed, his breathing is very short, his pulse small—80, and his temperature normal. The chest is resonant all over, and the breath-sounds are well heard, and there is nothing noteworthy about their character. The cardiac dulness is diminished, and the impulse of the heart is not well felt. There is no murmur. The voice is clear but weak. The bowels are regular and the urine normal. The dyspnœa is worse on exertion.

Course of illness.—The patient gradually became worse, and was obliged to keep his bed, and he had from time to time several severe attacks of dyspnœa with blueness.

He was admitted into the Worthing Infirmary, and for a time seemed somewhat to improve.

In December, 1892, a slight deficiency of resonance over the left back was noted, but in other respects the physical signs remained the same.

He occasionally had some pain, first on one side and then on the other, and at times his temperature was slightly febrile.

In January, 1893, the attacks of dyspnœa became more frequent; they lasted about half an hour, and seemed to be relieved by stimulants, but in one of these attacks he died, on January 26th, 1893. As a rule, he had been able to lie down and rest, and only

when the attacks of severe dyspnœa occurred did he assume the sitting position, leaning somewhat forward.

Post-mortem.—Body fairly well nourished. When the sternum was removed both lungs bulged up into the opening; the heart was almost entirely covered by lung. Both lungs had very large emphysematous bullæ upon them. The left lung was free from adhesions, and the hand passed between it and the parietal pleura easily separated the lung from the chest wall. The right lung was adherent along the front to the chest wall by loose but strong adhesions, and when these were carefully broken through and the hand passed to the back of the lung, which was free from adhesion, there was a sudden escape of air, and the lung fell back into the cavity of the chest, suggesting that possibly a pneumothorax had been opened.

When removed both lungs were enormously enlarged; some of the bullæ at the apices and along the anterior borders were as large as a pigeon's egg. Over the back of the left lung the pleura was thickened and opaque. On section the lung appeared much more fleshy and coarser than is usual. The other viscera were healthy. The left lung was moderately distended to its original size with air and carefully dried. Sections made through the organ thus preserved show a most extreme degree of emphysema which is universally distributed.

The emphysema itself shows the ordinary appearances of the disease in a severe form. The lung is somewhat darkly pigmented.

A portion of the right lung which had been preserved in Müller's fluid was examined carefully: to the naked eye it presented an unusual appearance; it was extremely fleshy, and resembled very closely a piece of sponge with many minute cavities and specks dotted upon its cut surface. There was no sign of any decomposition about the hardening agent, or of any growth of mould in it or upon its surface.

Sections were made and stained with logwood, and they presented the following appearances.

The lung is greatly disorganised in places, showing small microscopic cavities with breaking down of the substance of the organ. The walls of the pulmonary alveoli are notably thickened, as also are the small bronchi. In many places the lung tissue would hardly be recognised as such. Much pigment is deposited in the parenchyma of the organ. Scattered throughout the lung,

and lying chiefly where the structural changes are most marked, is an extensive mycelial growth.

The hyphæ of this mycelium are for the most part delicate and slender, although they present well-marked varicosities at different points. The hyphæ are jointed and branched, and here and there (apparently when a bend or branch is viewed end on) a well-marked rounded body is seen. No sign of fructification can be made out, which adds greatly to the difficulty of identifying the fungus; not

FIG. 1.

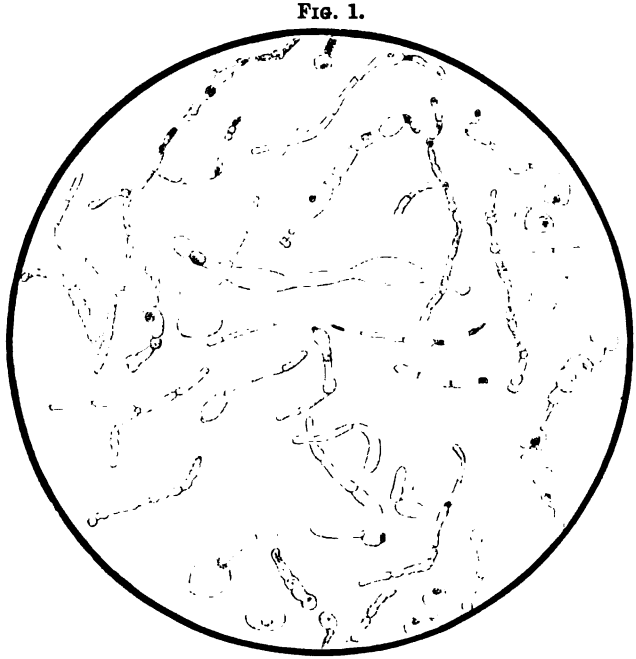

Fragments of a jointed mycelium seen under a high power. There are "varicosities" and rounded bodies, but no sign of fructification.

that there is any necessity of doing so if the mycelial growth is recognised. The mycelium lies to some extent in small cavities which it may have itself produced. In some cases it is seen apparently in bronchioles, but by far the larger portion is lying in the walls of the alveoli, and in the substance of the lung itself. In most places definite signs of vital reaction can be seen, as evidenced by the number of leucocytes, and large cells which

DESCRIPTION OF PLATE I.

FIG. A illustrating Dr. Norman Moore's paper on "An Undescribed Form of Hæmatozoon." (Page 384.)

Blood stained with eosin and methylene blue, and seen under $\frac{1}{12}$ in. oil imm. lens. The hæmatozoon with projecting processes is visible within a red corpuscle.

FIG. B illustrating a paper by Drs. C. J. Arkle and F. Hinds on "A Case of Pneumonomycosis." (Page 8.)

Section of lung tissue under a low power (obj. 1 in. Pillischer), showing greatly dilated spaces with thick fibrous walls, stained with logwood. Mycelium is present everywhere, and in places there is much pigment.

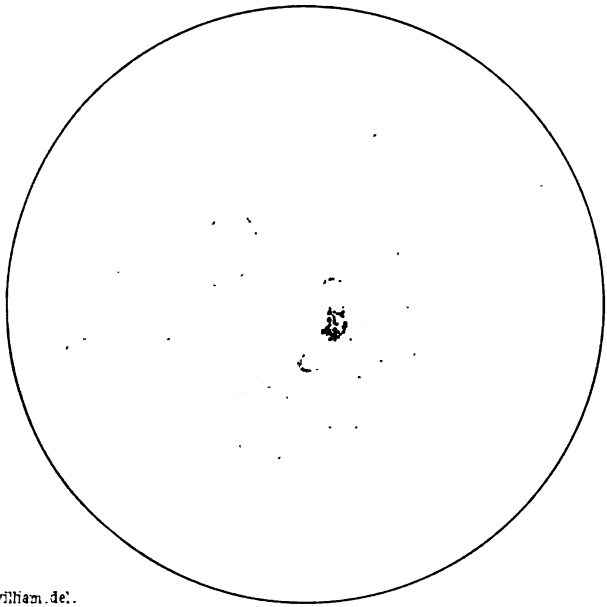

G.T.Gwilliam.del.



Cecil F. Beadles. del.

Lith.Anst.v.E.A.Funke Leipzig.

appear to be phagocytes, as they occasionally contain bits of the mycelium; and this fact is strong evidence that the fungus was present during life. In one or two places near the periphery of the organ the mycelium was not found, and the lung here showed signs of an early interstitial pneumonia.

Sections of the lung were very kindly examined for us by Professors Marshall Ward and Oliver, and in their opinion the presence of the varicosities seen so distinctly on the mycelium make it almost certain that the growth is an aspergillus.

Remarks.—It is somewhat unusual for a healthy young man of twenty-two to suddenly develop emphysema without apparent cause, and of such an extreme degree that it proved fatal within four months. The usual exciting causes of emphysema were all absent in this case, and the patient's occupation could not well have been healthier. It did not seem likely that the condition was a congenital one, for the patient had never suffered from dyspnœa on exertion up to the time of his last illness.

It is evident that some general cause affecting the whole of both lungs could alone explain the condition, and up to the time of the discovery of the extensive mycelial growth in the organs an idea was entertained that some trophic nerve lesion perhaps offered the best explanation of the changes found. After careful microscopical examination, however, and the discovery of a wide-spread mycosis in the lungs, we are inclined to think that this somewhat unusual emphysema may have been connected with the growth of this particular mould.

The association of fungi with many pathological conditions, both in man and in the lower animals, has long been recognised, and every day fresh observations are being made with regard to these affections—observations which show that these mycoses are by no means so uncommon or so innocent as has been supposed.

In the majority of cases, however, the growth has been connected with phthisical cavities, gangrenous lung, or some other morbid process, and may have had only an accidental association with the results of these cases.

Virchow, who observed the condition just forty years ago, gives a *résumé* of all previous observations up to 1856, and mentions, amongst other cases, those of Bennet and Gairdner from English records. Both these observations were from cases of phthisis with pneumothorax. His own cases were four in number at that time

and he found the growth three times in the lung and once in the larger bronchi, calling the conditions broncho- and pneumono-mycosis aspergillina. With one exception a destructive process was present in the lungs, generally gangrenous; in two cases there was marked emphysema and a notable softening of the tissues.

Fürbringer, in 'Virchow's Archiv,' 1876, gives references to all recorded cases between Virchow's and his own. He found gangrene present in nine out of eleven cases. In such cases of gangrene it appears that *Aspergillus, Leptothrix, Sarcina ventriculi,* and *Mucor mucedo* have been found, whilst *Oidium albicans* has been seen in cases of putrid bronchitis.

Penicillium glaucum has not been found. *Aspergillus* is found as a rule with hæmorrhagic infarction or pneumonia; *Leptothrix* in gangrene from pneumonia and bronchiectasis; *Mucor mucedo* in hæmorrhagic infarcts and gangrene from exhaustion.

In the Pathological Society's 'Transactions,' vol. v, the late Dr. Bristowe records a case of a vegetable parasite growing in a cavity in the lung of a woman who was supposed to be phthisical; and Dr. Wheaton found an aspergillus growing in a tubercular vomica.

Boyce has given a full description of an aspergillar affection of the lung in a patient dying of heart disease, in the 'Journal of Pathology,' vol. i, and other cases have from time to time been recorded.

There is abundant experimental evidence on record where the spores of such fungi have been injected into the circulation in animals, and the mycelium discovered subsequently in the organs; and the liability of birds in nature and captivity to such affections is also well known, attention being called to this condition in the case of birds dying at the Zoological Gardens, by Bland Sutton in the 'Path. Trans.,' vol. xxxvi.

A paper by Chantemesse at the International Medical Congress, 1890, contains facts concerning a class of people in Paris who are employed in feeding pigeons, and who suffer from phthisical symptoms probably due to a mycosis.

The practice is to take a quantity of grain into the mouth, and after chewing it to impart this nourishment to the pigeons by spitting it into their crops.

The risks attendant on such a procedure are very evident, as it seems quite certain that grain is a common vehicle for these moulds, and indeed, in one pigeon examined, the mycelium was found

starting from a grain of corn which had passed into an air-cell. One case of Chantemesse's has been verified *post mortem*.

The close resemblance of an affection like the one we have described with actinomycosis is of interest; although we have found nothing more than a mycelium, and lay the greatest weight on Prof. Marshall Ward's opinion that the fungus is an aspergillus, yet the mode of infection by the respiratory tract, and the fact that it occurred in a man who worked amongst straw and grain, is worth bearing in mind. In this connection the probable date of infection, so far as can be judged, would roughly correspond with harvest-time.

The case differs from many which have been recorded, in that the growth appears to have taken place in otherwise healthy lungs, and not to have been connected with any antecedent pathological process.

It is possible that the growth of hyphæ in the walls of the alveoli and small bronchi—or by the growth forming small microscopic cavities—there may have been produced a great softening of the lung tissues, which would greatly diminish the resistance and elasticity of the organ, and so lead to the remarkable over-distension which has occurred.

In conclusion, we think the emphysema, both in its origin and course, an unusual one; that the occurrence of a mycelial growth throughout an otherwise healthy lung is uncommon; and we suggest that its existence there offers perhaps the best explanation of the condition found in the lungs, at any rate to justify us in bringing the case before this Society.

Pneumonomycosis bibliography.—*Virchow.*—'Archiv für path. Anat.,' vols. ix and x, 1856. *Fürbringer.*—'Virchow's Archiv,' vol. lxvi, 1876. *Wilson Fox.*—'Diseases of the Lungs,' p. 467, and references. *Boyce.*—'Journal of Pathology,' vol. i, and references. *Chantemesse.*—'Rep. Int. Med. Cong. Berlin,' 1890. *Bland Sutton.*—'Path. Soc. Trans.,' vol. xxxvi. *Bennett.*—'Trans. of the Roy. Soc. Edin.,' 1842, vol. xv, 2, p. 277. *Gairdner.*—'Edin. Month. Journal,' 1853, p. 472. *Wheaton.*—'Path. Trans.,' vol. xli. *Bristowe.*—'Path. Trans.,' vol. v. *Grawitz.*—"Ueber Schimmelvegetationen in thier. Org.," 'Virchow's Archiv,' vol. lxxxi. *Robin.*—'Histoire naturelle des vegetaux Parasites qui croissent sur l'homme et sur les animaux vivants,' 1853. *Baumgarten.*—'Lehrbuch der pathologischen Mykologie,' 1886–90.

May 5th, 1896.

III. DISEASES, ETC., OF THE ORGANS OF CIRCULATION.

1. *Heart from a fatal case of angina pectoris, with thrombosis of the right coronary artery.* (*Card specimen.*)

By F. Parkes Weber, M.D.

The heart weighed 16 oz. at the *post-mortem* examination. There are no valvular lesions, but the channel of the right coronary artery is obliterated by organised thrombus at about 2½ inches from its orifice for a space of about 1 inch. Though the left coronary artery is not thrombosed, the lumen of its main trunk is very much narrowed by atheromatous changes at about 2 inches from the orifice. The specimen thus confirms the view that "true" angina pectoris is caused by chronic obstruction in the supply of blood to the heart muscle, the obstruction making itself felt by an attack of angina pectoris when for any cause the heart is called upon to do extra work.

When the heart was first removed, a patch of the wall of the left ventricle, of the size of a shilling, situated at about the middle of the posterior surface, was somewhat paler in appearance and more easily indented with the finger than the rest of the heart wall. Microscopic sections show an extreme fibroid localised degeneration of the muscular substance (a stage of myomalacia cordis), affecting the whole thickness of the ventricular wall at this spot. This degenerated portion was thinner than the surrounding parts of the ventricular wall.

If the man had lived much longer he would probably have had a cardiac aneurysm at this spot. A microscopic section from another portion of the heart wall shows only very slight fibroid change.

History.—G. T—, aged 56, a baker, a native of Würtemberg, was admitted at the German Hospital, Dalston, October 22nd, 1895.

Patient was a big man with a tolerable amount of subcutaneous fat, who had been in the habit of taking much beer. During last winter he was an in-patient at the German Hospital under my care, suffering from chronic pulmonary tuberculosis, chronic bronchitis with emphysema, and albuminuria. The physical signs of advanced tuberculous lesions in the lungs were very distinct, though the general clinical aspect of the case was rather that of chronic bronchitis and emphysema. At that time patient had no attacks of angina pectoris. He improved somewhat under treatment. On October 22nd, 1895, patient was readmitted suffering from angina pectoris. Symptoms were somewhat relieved by the inhalation of nitrite of amyl. There was no fever or sign of active progress of his pulmonary tuberculosis. On November 10th patient died during one of the attacks of angina pectoris.

A necropsy was made on the following day. *Lungs:* old pleuritic adhesion, especially on the right side. Extensive tuberculous lesions in the lungs, some old, some recent. The *heart* has already been referred to. There was some atheroma of the aorta. *Liver* weighed 80 oz. There were a few calculi in the gall-bladder, and a few peritoneal adhesions over the surface. *Spleen:* remains of old perisplenitis. *Kidneys:* the capsules stripped readily, but left a somewhat granular surface, and the gland substance was slightly shrunken.

Judging from the new blood-vessels in the thrombosed portion of the right coronary artery, it is evident that the clot was not quite recent. It may have existed before the attacks of angina pectoris commenced; and the anastomosis between the right and left coronary arteries, which was formerly denied by anatomists, but which has been abundantly proved by injection of the vessels after death to be present in most cases, may have been for some time sufficient to maintain the nutrition of that portion of the heart muscle supplied by the right coronary artery. According to this explanation, the lumen of the left coronary artery afterwards becoming diminished, the increased difficulty in the supply of blood to the heart wall caused at first the attacks of angina pectoris, and then the patient's death. At any rate we may assume that the disease in either of the coronary arteries by itself was probably not sufficient to give rise to fatal angina pectoris.

The case likewise illustrates the usually very slow progress of pulmonary tuberculosis when it occurs in patients who are the

subjects of a certain amount of interstitial nephritis,[1] with general degenerative changes in the circulatory system. They seldom die of their pulmonary lesions, although the autopsy may show, as in the present case, that the tuberculous process is still progressing. They are more likely to die of chronic uræmia, an acute exacerbation of Bright's disease, cerebral hæmorrhage, or some degenerative disease of the vascular system, of which the present instance is a rare variety.

January 7th, 1896.

---

2. *Heart with obliteration of the commencement of the right coronary artery; no angina pectoris.*

By F. Parkes Weber, M.D.

The heart exhibited shows obliteration of the origin of the right coronary artery, but the position where the opening should be is marked by a small pit in the right sinus of Valsalva, with an appearance of scarring about it. As most of the aorta has undergone extensive atheromatous changes, it is difficult to say whether the closure was congenital (occurring before birth), or caused by changes similar to those which have taken place in other parts of the aorta. The heart musculature appears to be normal.

During life the patient had no attacks of angina pectoris. This specimen, therefore, supplements the preceding specimen, and serves to demonstrate the fact that one coronary artery being obliterated, as long as the other coronary artery remains sound the circulation of the heart can be perfectly carried on, at least in cases where, as it usually does, an anastomosis between the two coronary arteries exists. That there must have been complete anastomosis between the two coronary arteries in this case appears evident from the fact that the right coronary artery, although obliterated at its aortic orifice, was quite pervious immediately outside the aorta, a fact which Mr. J. H. Targett showed by dissection.

[1] *Vide* 'On the Association of Chronic Interstitial Nephritis with Pulmonary Tuberculosis,' by Dr. F. P. Weber, (Thesis), London, 1892.

As the case offered some other points of pathological interest I may be allowed to add the following short note concerning it.

The patient, Mrs. J. F—, aged 61, was admitted at the German Hospital on November 29th, 1895, and died December 15th, 1895.

For the last year she had suffered from various kinds of pains in the head, not worse at night-time. There was at times offensive purulent discharge from the nose, leading to the suspicion that one of the sinuses connected with the nose was the seat of the trouble. The visible parts of the nares appeared normal.

As there was a history of repeated miscarriages, and as there was an old perforation of the palate, the active mischief was suspected to be of a tertiary syphilitic nature. She was treated at first with iodide of potassium, and afterwards by mercury with iodide of potassium. There was no sign of active syphilis or active disease of any other kind elsewhere in the body. The urine (examination on December 5th) had a high specific gravity and a moderate cloud of albumen. The evening temperature was usually above 100°, and during the last days there was fever in the morning likewise. On the 15th December the patient died after severe venous hæmorrhage from the nose.

The following are the results of the *necropsy* (performed by the house physician, Dr. Luce).

The brain, meninges, and meningeal sinuses, and the base of the skull as viewed from above, presented no appearance of disease. The base of the skull and nose were divided vertically in the sagittal line by Harke's method, which best enables one to examine the sphenoidal cells, &c., without disfiguring the face. A considerable portion of the basi-sphenoid bone was necrosed, the anterior and lower portions of the nasal passages being normal. The bleeding had probably proceeded from some large vein in the substance of the sphenoidal bone closely communicating with the large venous sinuses at the base of the brain: it had probably been laid open during the process of separation of a sequestrum. The parts about the necrosed bone were, however, black and decomposing at the necropsy, and the exact site of the ruptured vein could not be found.

The heart has already been described. The lungs showed old scarring and calcareous material at one apex. The stomach was full of black clotted blood. In the liver there was scarring around an old gumma at the lower part of its right side, and there was a localised fatty change near the round ligament; otherwise the organ

was normal. The kidneys showed interstitial nephritis; both capsules were very adherent. In the right supra-renal body there was a small cyst containing thick brownish opaque material. The aorta showed extensive atheromatous changes; at its root, moreover, the changes seemed to involve all its coats, and the pericardium was adherent over it at some places, thus suggesting that these changes may have been due to a tertiary syphilitic process involving all the coats of the vessel rather than to an ordinary atheromatous process involving the intima only. At one spot on the arch there was a commencing aneurysm about the size of a small cherry, the sharply punched-out appearance of which suggested that it was due to the yielding of a spot weakened by a localised gummatous formation. *December 17th*, 1895.

---

3. *The heart from a case of angina pectoris, showing stenosis of the coronary arteries; old partial thrombosis in the basilar artery; commencing lardaceous change in the various organs.*

By F. Parkes Weber, M.D.

The coronary arteries in this case afford an excellent illustration of the condition of obstruction to the blood-supply of the cardiac walls, which is by many authorities considered to be the cause of well-marked angina pectoris, if "nervous angina" be excluded. The changes in the coronary arteries in the present case are similar (but less in degree) to those in the first case (see case No. 1, p. 14), where the right coronary artery was thrombosed, and the patient actually died during one of the anginal attacks.

I will first give short notes of the case and of the *post-mortem* examination, and will then make some remarks on various points of interest connected with them.

Karl O—, aged 61, a native of Würtemberg, was admitted into the German Hospital September 15th, 1895, and died on the 8th March, 1896. There was an old history of syphilis, and ten years ago he is said to have developed a crossed hemiplegia involving the whole of the left face and the right arm. This improved much, apparently under antisyphilitic treatment, but a paresis remained.

On admission patient was seen to be a tall, powerfully built man,

with scars, probably from tertiary syphilis, on his face. By auscultation no murmur could be heard over the heart. The lungs were emphysematous. There was œdema of the lower extremities and some ascites. Urine, sp. gr. 1008, contained about three per mille (by Esbach's tube) albumen. The remains of the crossed hemiplegia were apparent.

Later on the patient began to suffer from attacks of angina pectoris. The quality of his urine remained much the same throughout, but the daily quantity varied somewhat.

On January 20th, 1896, I have a note that a faint mitral systolic cardiac murmur could then be heard, but that the emphysema masked the probable enlargement of the heart. However, on January 28th the apex-beat could be felt in the fifth intercostal space about 2 inches outside the nipple line. On the 3rd February œdema of the arms and chest walls was noted. On February 20th the cardiac apex-beat could be felt in the fifth intercostal space (? 1 inch) outside the nipple line; no murmur could be heard, except a slight systolic murmur over the mitral area accompanying the first sound. The pulse was 72, regular; crepitations were heard at the pulmonary bases; the hepatic dulness extended from the fifth rib to below the costal margin.

The patient's general condition appeared sometimes to be temporarily improved by short courses of digitalis or strophanthus, with nux vomica and citrate of caffeine, or by digitalis with iodide of potassium or with ether and ammonia.

In the last weeks no angina-like pains were complained of. The œdema, however, increased, and towards the end the ascites necessitated tapping.

Necropsy (March 9th, 1896).—*Brain:* a cyst about the size of a large cherry and containing clear fluid was found involving the central portion of the left internal capsule. In the basilar artery at the level corresponding to the junction of the pons and medulla oblongata was a small decolourised adherent thrombus, not completely blocking up the channel. The left "half" of the pons was obviously considerably smaller than the right "half." Microscopical examination has not yet been made. *Heart:* weight about 24 ounces. Pericardium adherent by recent lymph, but easily separated from the heart. The hypertrophy was nearly confined to the left ventricle. No valvular affection was present except slight atheromatous thickening. *Coronary arteries:* both of them

thickened and tortuous. The two main branches of the *left* coronary artery were represented by two vessels, separate from their commencement; both were very atheromatous, the interventricular one being extremely stenosed about one inch from its origin. The lumen of the *right* coronary artery, about half an inch from its commencement, was almost obliterated by atheroma: this is well shown by the microscopic sections. Microscopic examination of the wall of the left ventricle shows the presence of a lardaceous change in some of the small arteries similar to that found in the other viscera (liver and kidney). There was considerable atheroma of the *aorta*. *Lungs:* no pleuritic effusion present. *Abdomen:* considerable collection of ascitic fluid (though paracentesis had been recently performed). The *liver* weighed about 60 ounces, was "nutmeggy," and its surface was scarred by irregular (gummatous ?) perihepatitis. By the microscope a lardaceous change in some of the vessel walls can be made out. The muscle-fibres of the middle coats of the small arteries are thus in some parts beautifully picked out, but the capillaries are not affected, as they are in more advanced lardaceous disease of the liver. The *spleen* slightly enlarged and hard (a "cardiac spleen"); the capsule thickened from old perisplenitis. The *kidneys* to the naked eye appeared typical contracted kidneys of an advanced period of chronic interstitial nephritis. When sections stained with methyl violet were examined under the microscope, a lardaceous change in several of the glomeruli and small arteries could be made out.

Remarks.—An interesting feature, though not an unusual one in like cases, was the cessation of the attacks of angina pectoris towards the end, when the signs of increasing cardiac failure began to show themselves by œdema in the lower extremities. Whatever the primary cause of angina pectoris may be, the pain, tension, and other terrifying feelings which constitute the attack can naturally only be felt through the medium of the nervous system, and if the patient does not die suddenly during one of these attacks, there is a tendency for the nervous system to accommodate itself in some way to the abnormal conditions in the heart, so that the attacks no longer take place. Although the anatomical changes which gave rise to the angina pectoris, persist or increase, the patient may then, as in this instance, become free from anginal pain, and die of gradual cardiac failure.

I regard the pain of angina pectoris as the expression of a rude

struggle between the parts of the nervous system on the one side, which control the mechanism of the circulation, and on the other side the diseased heart itself, which, in its endeavours to respond to reflex nervous impulses, calls forth the pain. The anginal attack arises from any attempt on the part of the nervous mechanism to raise the general blood-pressure, and thus suddenly increase the work of the already over-burdened heart, whether because the patient is taking voluntary exercise or for some other reason. Amyl nitrite and other drugs which dilate the peripheral arteries may then be of use, but in many cases before the patient's death, together with the onset of gradual cardiac failure, the nervous system learns to accommodate itself, and no longer attempts to raise the blood-pressure.[1] In fact, in such cases the anginal attacks cease because the nervous mechanism has given up the struggle; it has adapted itself, but only to circumstances which will lead to death in another manner.

When the coronary circulation is already disturbed by severe aortic reflux, a much slighter obstruction to the blood-flow in the coronary arteries may naturally be expected to produce attacks of angina pectoris than when, as in the present case, the aortic valves are quite competent. This consideration suffices to explain some objections which have been raised to the "coronary theory" of angina pectoris.

It may, however, be objected that angina pectoris sometimes occurs when there is only very little obstruction in the coronary arteries (and in the absence of aortic valve disease), but it must be remembered that persons of a "nervous" constitution will naturally react, where the nervous system is concerned, with peculiar readiness, even when the organic changes in the heart are slight or when there are transitory ("functional") vaso-motor disturbances only. It is thus that I would explain such cases. One may liken attacks of "nervous[2] *pseudo*-angina" to persons "crying out before they are hit." When such persons become really affected by organic cardiac disease, they may, indeed, perhaps actually "cry out" less and be less affected by palpitation and angina.

[1] The patient in such cases is not likely to attempt any sudden movements which tend to cause a rise in the blood-pressure. In the present case all considerable exertion was unnecessary, as the patient was in the hospital.

[2] Of course I do not refer to cases in which the presence of a distinct neuritis has been proved.

The necropsy was likewise of interest on account of the old crossed hemiplegia from which the patient suffered, and on account of the lardaceous changes found in the viscera, though suppuration, in the ordinary sense of the term, could not have been the cause. Of the relation between syphilis and lardaceous disease, of which this case is an example, I have endeavoured to explain the probable nature in 'American Journ. Med. Science,' 1895. It may be noted that this case and No. 1 (p. 16) differ from many of the best known cases of angina pectoris due to coronary obstruction, in that the main obstruction was not situated at the mouths of the coronary arteries, but at some distance from them.

January 7th, 1896.

---

4. *Cardiac aneurysm.* (*Card specimen.*)

By Cyril Ogle, M.B.

The specimen consists of an aneurysm measuring 5 inches by 3 inches, its circumference being 13 inches. It springs from the dome of the left ventricle, with the cavity of which it communicates by a fibrous orifice of the size of a sixpence, situated in front of the upper part of the left half of the anterior mitral cusp.

The aneurysm had extended behind the pulmonary artery and the aorta, which must have been considerably compressed by it. The left auricle is stretched over its posterior surface.

The wall is of dense fibrous tissue, containing no laminated clot; at the back it is thinned and perforated by a pin-hole aperture leading into the left auricle. There is much and widely spread fibrous change in the walls of the heart, chiefly marked as regards the septum and superior curve of the left ventricle, but also present in patches beneath the endocardium of the left wall of the left ventricle and the septum of the right ventricle.

There is a second aneurysm of globular shape, about two inches in diameter, the mouth of which, of the size of a shilling, is situated in the left wall on a level with the tip of the anterior mitral cusp.

The parietal layer of the pericardium was strongly adherent to the heart. The aorta and all the valves were practically healthy.

The lower lobe of the left lung was collapsed; there was no pleural effusion.

The patient was a man aged forty-eight years, with a distinct history of syphilis and ague, and a doubtful one of acute rheumatism when a boy. Breathlessness, œdema of legs, and pain in the cardiac region, with numbness of the left arm, were the chief symptoms. A systolic murmur, widely heard in the mitral region, and a broad area of cardiac dulness with forcible impulse were noted. A well-marked presystolic murmur and a diastolic whiff were heard a few days before death.

Microscopic sections of the myocardium where only slightly changed by fibrous tissue show the fibroid material, not in plates or definite strands, but pervading the bundles of muscle in an irregular way, the muscular fibres preserving their striation. The change seems most marked beneath the endocardium.

The aneurysm is noteworthy chiefly on account of its size, and the absence of any pressure symptoms. Although there was so much fibroid change in the heart's muscle, an abnormal slowness of pulse was not present during the several periods, extending over two years, that the patient was under observation; the rate was usually between 64 and 68 per minute. *May 5th*, 1896.

---

5. *Aneurysm or gumma of heart.* (*Card specimen.*)

By Cyril Ogle, M.B.

Situated on the left side of the fore-part of the septum of the ventricles, just below the junction of the right and left anterior aortic cusps, is a mass of grey and rather crumbling matter, measuring 1 inch by ¾ inch, with a well-defined and hard wall. The visceral pericardium over the left ventricle is opaque and thickened, and united in places by organised adhesions to the parietal layer; there are no adhesions over the right ventricle.

As there were scars and gummata in the liver and adrenals, and fibroid patches in the testes, it was thought that the mass in the heart's wall was also possibly a gumma, but the microscopic appearance did not bear this out, and was in favour of its being a cured aneurysm. The softer part is composed of a network of fine fibres,

staining well with picro-carmine, and becoming more and more laminated towards the periphery, where it emerges into stratified fibrous tissue. There is no cell infiltration and no caseation; the aspect is therefore not that of a gumma.

There is extensive subendothelial fibroid degeneration of the walls of the heart, chiefly visible in the infundibulum of the pulmonary artery, behind which the mass lies, but also to be seen in the left ventricle. In addition there is general, diffused, interstitial fibrosis, as streaks and bands in the muscle of both ventricles. The left ventricle is dilated and thickened, and contained some *antemortem* clots, softening in their centres. The aorta and both coronary arteries are free from disease. The innominate veins were thrombosed.

From the body of a man aged thirty-nine years, formerly a heavy drinker. No rheumatic history. His symptoms were partly due to cardiac failure, with Cheyne-Stokes breathing, œdema, and pleural effusion; and in part due to uræmia from catarrhal nephritis without lardaceous change. The pulse rate was not a slow one whilst under observation. *May 19th*, 1896.

---

6. *Embolic aneurysms of the heart, buttock, and axilla.* (*Card specimen.*)

By J. Jackson Clarke, M.B.

A girl, aged 10, was admitted under Dr. Lees into St. Mary's Hospital on February 25th, 1896, complaining of pain in the left axilla. A month before admission a swelling as large as half a walnut appeared in the right buttock, and gave rise to so much pain that the patient had been unable to use the corresponding limb. This lump gradually subsided. Three weeks later a similar swelling appeared in the axilla. The heart's apex was in the fifth space and outside the nipple line. There was a systolic mitral murmur, but a good second sound. On March 11th the patient was heard to groan, and was found to be dead. The usual measures failed to restore the cardiac or respiratory movement. A few days before death an effusion of blood was noticed in the left axilla beneath the skin.

Post mortem about six ounces of clot and as much serum were found in the pericardial cavity. The surface of the heart presented over a dozen swellings, which varied in size from that of a small chestnut to that of a pea. The largest of them was situated opposite the middle of the anterior inter-ventricular groove. It was conical in shape, and at its apex had a small round hole, from which blood could be made to issue by pressure. Some of the other swellings were incised, and were found to be aneurysms containing laminated clot. The aneurysms had formed on the primary and secondary branches of the coronary arteries, and thus came to lie beneath the serous covering of the basal half of both ventricles. There was also one on the right auricle. The mitral valve showed a fibrous ridge of thickening, but no recent vegetations. The aortic valve was normal except for the fact that its anterior flap was larger than the other two.

In the left axilla the loose tissue surrounding the glands was full of recently extravasated blood, and it is fair to assume that an aneurysm had ruptured here, although this point was not ascertained by dissection.

The emboli had evidently separated from the mitral valve some weeks before death, at a time when the endocarditis was active. The formation of aneurysms had probably been determined by micrococci contained in the emboli. In the course of a further dissection it was observed that the inner coats of the coronary arteries and their branches were everywhere greatly thickened, suggesting a possibility of syphilis as an alternative to the theory of embolism (St. Mary's Hospital Museum, No. 664A). *April* 21*st*, 1896.

---

7. *Stenosis of the pulmonary orifice of the heart.* (*Card specimen.*)

By Hugh Walsham, M.B.

The specimen was removed from a girl aged 18 years, who died in Victoria Park Hospital of chronic pulmonary tuberculosis. The heart weighed 12¼ oz. The pulmonary orifice was very small, only measuring about two-eighths of an inch across. The cusps

of the pulmonary valve were much thickened. The right auricle and ventricle were markedly hypertrophied. The foramen ovale was patent, but the interventricular septum was perfect. There was also some thickening of the tricuspid valve. *November 5th*, 1895.

---

8. *Syphilitic disease (?) of the ascending aorta and sigmoid valves.*

By P. H. Pye-Smith, M.D.

The patient from whom this specimen was taken was admitted into the clinical ward of Guy's Hospital on December 23rd, 1895. He was a blacksmith by trade, about 32 years of age. He had never suffered from rheumatism or its allies (chorea, erythema, &c.); and though when quite a young man he used a hammer weighing 14 pounds, he had since twenty-three years of age relinquished it for one of only 2½ pounds weight. Moreover, he was a slightly built man with no unusual development of the chest or arms; he had never to his knowledge strained his strength, and had no symptoms of disease until three or four weeks before he came under my care. About the beginning of December he began to suffer from decided dyspnœa with præcordial pain, and a fortnight or ten days later he noticed that his feet were swollen.

On admission, a loud to-and-fro basal murmur was heard, the pulse was collapsing, short and frequent, and the left ventricle was ascertained to be much enlarged. The liver was swollen, the legs œdematous, and the urine slightly albuminous.

The patient's age, the apparent acuteness of the disease, and the probable absence as above stated of endocarditis or atheroma, made the origin of his malady a matter of doubt during life, though its nature was abundantly clear. Treatment had only palliative effect, and he died suddenly on the 5th of January, 1896, less than five weeks after decided symptoms obliged him to give up work.

At the autopsy the heart was found much enlarged, weighing 22 oz. The left ventricle was very thick, and all the cavities were dilated and hypertrophied. The sigmoid valves were sclerotic,

deformed, fused together, and partly calcareous. There was no breach of surface, perforation, or adherent masses of fibrin. The first part of the aortic arch was marked by a soft, raised, slightly reddened patch with a convex crescentic margin. Beyond its advancing edge were several small raised spots apparently still more recent, and of the same soft gelatinous character.

The rest of the aortic arch was completely free from atheroma. The coronary arteries were not thickened or narrowed. The other valves were normal. There was some passive effusion in each pleural cavity, the liver was beginning to become myristicate, and the spleen and kidneys were hard. There was a small patch of red hepatisation in the lower lobe of the right lung.

The evidence of the syphilitic origin of this case is not, I admit, conclusive. I was led to it first by the absence of more frequent causes of valvular disease and arteritis. The patch of inflammation in the aorta above described struck those who saw it by its resemblance to a late secondary eruption on the skin, with its gyrate raised edge and scattered forerunners. We therefore looked for any other signs of syphilis, but found only early fibrinous degeneration of both testes, and scars of adhesions about the gall-bladder. During life no pigmentation or other remains of cutaneous disease, no nodes, or evidence of past iritis, no hard lymph glands, or other proof of lues could be found. The history, as usual, was ambiguous; there was the possibility of infection, but no proof of it.

There are numerous cases of syphilis affecting the heart recorded in our 'Transactions' and elsewhere, but they almost all refer to gummata or to fibrous degeneration of the myocardium. One instance of valvular disease in a subject recently suffering from syphilis was shown to our Society in 1868 by the late Dr. Leared, and was reported on by Dr. Burdon Sanderson and Dr. Cayley (vol. xix, pp. 94 and 95). This was, however, clearly a case of acute ulcerative endocarditis of the aortic valves. It may possibly have been set up by softening of a gumma, as was probably a case of purulent myocarditis following suppuration in a gumma, which I showed the Society in 1869 (vol. xxi, p. 94), but in neither case was syphilitic endocarditis present.

If we admit, as I take it we must, that syphilis is a frequent cause of aneurysms of the aorta, as well as of endarteritis of the mid-sized and smaller vessels, the lesion here described would exactly correspond with such an origin. Valvular disease has been ascribed

to lues in isolated cases on the Continent and in America, but often on doubtful grounds. If, however, the aortic disease in this case is conceded to be syphilitic, it seems most probable that the deformity of the sigmoid valves has the same origin. *January* 21*st*, 1896.

---

9. *Atresia of the pulmonary artery.* (*Card specimen.*)

By Cyril Ogle, M.B.

The heart of a child, who died from cyanosis and dyspnœa at the age of four months.

The left side of the heart with its valves is normal, and the aorta arises from it as usual.

The pulmonary artery is about half the size of the aorta; where the valves should be visible is seen a nipple-like projection or dome within its lumen, as if from coalescence of the valves, although no mark of separate cusps can be made out. The right ventricle is about half the size of the left, and no larger than a hazel-nut; the lining of its cavity is very opaque, as if from fibroid thickening beneath the endocardium, and there is a superficial rough patch in the infundibulum.

There is no opening between the two ventricles. There is ample communication between the two auricles, through the fenestrated Eustachian valve and foramen ovale. Circulation through the lungs must have taken place through the branches of the pulmonary artery, by way of the foramen ovale, the aorta, and ductus arteriosus, the last of these being the size of a crow quill. There was an absence of mesocolon on the right side, but no other deformity. Cyanosis since birth. No hæmophilia. A loud systolic murmur, not especially marked in the pulmonary region, and without evidence of enlargement of the right side of the heart.

It would seem that cases of atresia of the pulmonary artery, with no communication between the ventricles, are comparatively uncommon. Dr. Peacock, in the 'Pathological Transactions,' for 1871, says that of forty cases of atresia reported, there were only eight or nine with the septum of the ventricles normally developed.

Although no sign of separate cusps can be seen, the fact that the

communication between the ventricles, which should persist up to about the third month of fœtal life, is no longer present, points to the closure of the pulmonary cusps by adhesion after this date, since it is probable that the septum would have remained incomplete had the pulmonary artery, from defect in development, been always impervious. *May 19th*, 1896.

---

10. *Embolism of the coronary artery.* (*Card specimen.*)

By Cyril Ogle, M.B.

A heart weighing 28 oz.; the large size is due to a thickened and greatly dilated left ventricle.

The patient was a messenger aged 17 years, and had suffered from cough and from ascites, with œdema of legs for a fortnight. There was a history of two attacks of acute rheumatism. He was kept in bed under treatment for two months, with some improvement, his symptoms including a rapid pulse (usually 140—160 per minute) with a somewhat tense artery; the urine, of a sp. gr. of about 1020, always contained a small but varying amount of albumen. There was evidence of a very large heart, but no murmur was ever heard, and a condition of adherent pericardium was considered probable.

On March 27th he suddenly became very distressed for breath and cyanosed, and died within ten minutes of the onset of the symptoms: it was not clear whether he suffered pain; it was thought not.

At the examination *post mortem* the aorta was healthy; the valves were quite flexible, and the aortic valves held water. The muscle of the hypertrophied left ventricle appeared healthy microscopically.

Both coronary arteries were free at their mouths, but one of the two main divisions of the left coronary, the descending or septal branch, was firmly plugged by a clot of a streaky black and yellow aspect, not attached to the wall of the vessel, and situated at three quarters of an inch from the mouth of the artery. In the dilated cavity of the left ventricle, near the apex, was an adherent, streaky polypus of exactly the same aspect as that of the clot in the coronary artery, and from this no doubt the latter was derived.

In the other parts of the coronary system there was a little liquid

blood only. There was no œdema of the lungs, and a striking appearance was presented by the great quantity of black clot in the cavities of both sides of the heart.

The left kidney was reduced to a putty-like mass of caseous tubercular matter; the right kidney weighed 8 oz., and, except for an old and some recent infarcts, appeared microscopically to be nearly healthy.

There appears to be no case described to the Pathological Society of embolism of a large branch of a coronary artery. In Pepper's 'System of Practical Medicine' (vol. iii, p. 381) such a case is alluded to, with death within twenty hours after the onset of symptoms.

Cohnheim, in his 'Lectures on General Pathology' (vol. i, p. 35, of New Sydenham Society's Series), says that the sole cause of death may be embolism of a coronary artery, and discusses the effect of ligature of any large branch of the coronary arteries in dogs, showing that a fatal result ensues within about two minutes.

May 5th, 1896.

---

11. *Aneurysm of the right inferior thyroid artery; abnormal distribution of vessels.* (*Card specimen.*)

By John R. Lunn.

The specimen was removed, October 6th, 1895, from a woman aged 59, who was admitted into the St. Marylebone Infirmary on March 22nd, 1895, with a small pulsating expansile swelling about the size of a horse-bean at the upper end of the right supraclavicular fossa, and to the outer side of the sterno-mastoid muscle. A soft systolic murmur was heard over the tumour, and was conducted over the aortic and cardiac areas. The artery was ligatured above and below (June 12th, 1895), and divided; the wound healed well, but the pulsation still remained.

History.—Susan A—, aged 59, a servant, was admitted into the St. Marylebone Infirmary on March 22nd, 1895, with dementia and aphonia. She had always been a healthy woman until ten years before admission, "when she was laid up with paralysis."

On admission the woman was fairly well nourished, with no well-marked physical signs, though she had lost her voice off and on for some months. The right pupil was thought to be a little larger than the left one; both pupils acted to light and accommodation. On examining her throat with the laryngoscope the vocal cords were normal in colour, the abductor muscles worked imperfectly, and the vocal cords approximated in the anterior two thirds, but not in the posterior; the weakness seemed evenly marked on the two sides. It was also noticed that the patient had a very small pulsating, expansile swelling about the size of a small bean at the upper end of the right supra-clavicular fossa to the outer edge of the sterno-mastoid muscle, and apparently corresponding to the position of the right inferior thyroid artery. Over this pulsatile swelling was a loud systolic murmur, which was conducted over the aortic area; pressure over the artery above the swelling made no difference to the character of the murmur. The pulsations of the right and left temporal and facial arteries were equal on both sides; there was no venous engorgement about the neck or face. The urine contained no albumen. It was decided to watch the case on account of the woman's age and her general condition, as there seemed no urgency for any active treatment.

The patient was kept on low diet with rest in bed, and given a mixture of iodide of potassium. A few months after admission the swelling became much larger, and looked as if it was going to burst, so it was decided something should be done. The patient was put under an anæsthetic on June 12th. A four-inch longitudinal incision was made over the site of the swelling (a little to the outer side), and on carefully dissecting down towards the tumour a fusiform aneurysm was discovered in the course of the inferior thyroid artery extending downwards into the chest; the coats of the artery seemed very thin and diseased. An aneurysm needle was passed above and below the vessel, and the artery was divided between the two ligatures. It was impossible to find a healthy part in the course of the artery. The wound soon healed, but the pulsation still remained. The patient became emaciated, and developed signs of tuberculosis, and gradually sank October 16th, 1895, four months after the operation.

Autopsy.—Both lungs were studded with tubercles. Both kidneys were small and dark, each weighing only 2½ oz. The heart weighed 9½ oz. The left ventricle was moderately hypertrophied,

the valves were competent; most of the arteries in the body were atheromatous. The liver and other viscera were normal.

The aneurysm and vessels were removed for examination, and it was found that both common carotid arteries and both subclavian arteries came off from the innominate artery. On the right side the subclavian and common carotid came off from a common trunk. On the left side there was a common trunk for the common carotid and subclavian, the common carotid being of very small size. On the right side the common carotid, vertebral, and thyroid axis were so much mixed up in the clot resulting from the aneurysm as to be indistinguishable. The common carotid, thyroid axis, internal mammary, and posterior scapular could be clearly made out on the left side. *May 5th*, 1896.

---

12. *Cured aneurysm of the external iliac artery.* (*Card specimen.*)

By Douglas Drew.

History.—The patient, aged 48, was admitted into University College Hospital in April, 1887, with an aneurysm of the external iliac and common femoral arteries. The tumour measured five inches in length, and it reached from the pubic spine to the anterior superior iliac spine. Digital and instrumental compression failed to effect a cure. Ligation was therefore decided upon, and the incision had just been made when pulsation in the sac ceased, so the wound was closed. The patient had struggled under the chloroform.

The specimen shows that the sac has been converted into a mass of fibrous tissue. The wall can be identified as it is calcified in parts. The epigastric, circumflex iliac, and profunda vessels arise from the sac. The external iliac artery above the sac is converted into a small fibrous cord.

March 17th, 1896.

13. *Rupture of the inner coat of the abdominal aorta.* (*Card specimen.*)

By Arthur Voelcker, M.D.

The inner coat of the abdominal aorta is ruptured transversely at the origin of the common iliac arteries. The outer coat is not torn, but the detached inner portion of the wall is coiled up into a conical plug, which projects upwards in the aorta as high as the origin of the inferior mesenteric artery.

History.—From a boy aged 14, who was squeezed by a lift across the lower part of the abdomen. There was no fracture of any bone.

The specimen is preserved in the Middlesex Hospital Museum.

March 3rd. 1895.

IV. DISEASES, &c., OF THE ORGANS OF DIGESTION.

1. *Malignant disease of the tonsil.* (*Card specimen.*)

By Lennox Browne.

History.—A man aged 68, a tin-plate worker, living at Watford, applied at the Central London Throat Hospital on January 14th, 1895, complaining of pain and swelling in the throat with difficulty of swallowing.

Family history good. Father died at the age of seventy-four, and mother aged eighty; one brother died from "cancer in the throat," aged fifty-three.

Personal history.—Had experienced good health up to two years ago, when he first noticed a swelling in the right tonsil, followed by enlargement of the glands under the jaw on the right side, but without pain until recently, and that only in the neck externally. Has lost weight rapidly. The wife (a second one) reported that he had been very intemperate for the last fifteen years.

State on admission.—The right tonsil was seen to be intensely red, and so swollen as to extend far beyond the middle line of the fauces, pushing the uvula to the left. The gland was somewhat papillary on the surface, and extremely hard and unyielding to the touch. The tongue was quite mobile. The vocal cords acted normally, both superficial and deep. The glands of the right side, extending to the supra-clavicular fossa, were enlarged, indurated, and tender.

Chest.—Resonance was impaired over the left lung, both at the apex in front and in the supra-spinous fossa behind. Vocal fremitus was absent, vocal resonance increased, and no breath-sounds were audible at the situation indicated. On very deep inspiration slight crepitus was detected. Tenderness and resistance to deep pressure were experienced over the hepatic region.

On January 21st a portion of the growth was removed with a snare, and was submitted to examination by Mr. Wyatt Wingrave, who reported, "Tissue consists of the following:—(1) Surface epithelium stratified; limits not clearly defined, as it tends to invade the subjacent structures. (2) Remains of cloudy distorted lymphoid

tonsil tissue. (3) Dense spindle-celled trabeculæ, strangling and displacing lymphoid nodules of the tonsil.

"*Conclusions.*—There has been some slow inflammatory process at work, which may possibly be assuming a more active phase, suggestive of malignancy; but the tissue is of so indefinite a character that it does not enable a finite statement to be made as to its clinical aspects."

Injections of Coley's fluid were commenced on January 28th, and continued until February 11th, when the patient developed a sharp attack of erysipelas, and later of cervical cellulitis, which required free incision; no pus was evacuated, but a large blood-clot was removed, which gave great relief.

It is of clinical interest to record the temperature, which when treatment was commenced was 97°; it rose by slow degrees with each injection, the highest temperature reached being 104·8° on February 7th. On cessation of the treatment the temperature gradually fell to normal on February 25th, and remained so after that date.

The patient was discharged early in March. The tonsillar swelling had almost entirely subsided, and was softer in consistence, as was also the external swelling, but the patient had been much reduced in both strength and weight by the treatment.

He returned on December 2nd, stating that his throat trouble had remained quiescent for nine months, but that during the last three or four weeks it had again commenced to be intensely painful.

The external swelling was seen to be larger than ever, and the tonsillar growth had now involved the lymphoid tissue at the root of the tongue, the movements of which were much impaired.

No further treatment was attempted, but a portion of the growth was removed and submitted to a microscopic examination by Mr. Wingrave, who reports, "The chief feature is a marked ingrowth in all directions of the surface stratified epithelium to such an extent as to entirely disguise the nature of the organ. The ordinary tonsil lymphoid tissue is replaced by ramifying strands of epithelial elements, the oldest of which show marked vacuolation, whilst here and there is an apparent tendency to nest formation."

Remarks.—This case does not greatly vary from those which in past years I and others have shown at this Society; and it has no clinical feature specially germane to pathology except that (1) it is

a confirmation of my already expressed experiences that alcoholism is a strong predisponent of malignant disease of the tonsils; and that (2) its course under treatment by Coley's injection corroborates the experience of those who believe the relief by that remedy to be at best only temporary. It is, however, interesting to note that from some cause or other the progress of the growth, usually so rapid in this region, has been phenomenally retarded, and it is fair to assume that the treatment adopted may have a causal relation to this slow growth. It may also be noted that there has been neither ulceration nor hæmorrhage.

Turning to the histological features, it may be remarked that there was some conflict of opinion as to its nature, one or two who examined the section having suggested that the case was one of sarcoma, but Mr. Wyatt Wingrave has expressly pointed out that the small-celled tissue which ordinarily accompanies the epithelial ingrowth is not sufficiently marked to constitute the primary lesion. On the other hand, the epithelial elements not only predominate in quantity, but encroach in all directions upon the tonsil substance, so as to entirely mask and replace the original lymphoid tissue.

Mr. Wingrave also draws my attention to the fact that in epithelioma in this region nest formation is usually indistinct, the cells, on the other hand, having a great tendency to cyst-like vacuolation. This atypical characteristic of tonsillar epithelioma is well illustrated in the sections when seen with a low power.

December 17th, 1895.

---

2. *Congenital occlusion of the œsophagus.* (*Card specimen.*)

By Bilton Pollard, B.S.

Description of specimen.—The œsophagus is occluded about half an inch above the bifurcation of the trachea. The lower segment of the œsophagus communicates with the trachea immediately above its bifurcation.

The subject of the malformation had also an imperforate rectum, but with the exception that the cleft between the second and third toes of one foot extended to the base of the metatarsal bones there were no other malformations of either the internal or external organs. The stomach was distended with meconium.

History.—The child was admitted for imperforate rectum on the

second day after birth. The bowel was opened from the perinæum at once. No mention was made of the child's inability to swallow, but this was discovered by the nurse during the first night after admission. Unsuccessful attempts were made to pass a tube into the stomach. During the night the child twice vomited meconium. It died early on the following morning. *April* 21*st*, 1896.

---

3. *Simple dilatation of the œsophagus.*

By H. D. Rolleston, M.D.

This specimen was removed from the body of a patient of Mr. Edgcombe Venning, by whose kindness I was enabled to make the *post-mortem* examination and bring forward the case.

A boy aged 8 years, after an attack of whooping-cough, began to suffer from choking fits; this was succeeded by vomiting, which resisted all manner of treatment, and though fed for six weeks by the rectum he emaciated and died. Some little time before the fatal illness the patient had a somewhat similar attack, from which he recovered.

The family history is of interest in showing apparently a marked susceptibility to vomiting. Another child of the same family had a similar attack, but recovered; and yet another died with vomiting in the course of scarlet fever. An uncle died of vomiting which was thought to be of neurotic origin.

Description of the specimen.—The commencement of the œsophagus at the cricoid cartilage is of normal size, and there is no loss of elasticity here. Below this point the œsophagus is dilated, its circumference when distended measuring $3\frac{1}{2}$ inches, and at the *post-mortem* examination it contained liquid food. It was $9\frac{1}{2}$ inches in length (the measurement normal to the œsophagus of an adult), and before removal ran a somewhat tortuous course through the thorax. The muscular coat was hypertrophied, especially when allowance is made for the accompanying dilatation. The mucosa was normal. The lower end of the œsophagus was again of normal size, and between its two ends the œsophagus appeared as a dilated spindle. A finger easily passed into the œsophagus from the stomach, and there was no sign of stricture either to the naked eye or microscopically.

All the other organs, including the brain, were normal, with the

unimportant exceptions that there was a calcareous gland near the cæcum, and a small exostosis on the anterior surface of the right humerus, just above the elbow-joint, and not near the position of the origin of the pronator radii teres, where a supra-condyloid process is occasionally met with. No pressure or source of irritation could be found in the course of the phrenic or pneumogastric nerves. The stomach contained some liquid food.

Remarks.—This appears to have been a case of primary dilatation of the œsophagus, since there was no evidence of any stricture at the cardiac end. Mackenzie [1] says that the progress of the disease is generally slow, lasting from five to ten years; in this case the disease ran a rapid course, and forms a contrast to the case recorded by Dr. Wilks [2] of a man aged seventy-four, who had always vomited his food, and in whom, after death from pneumonia, the œsophagus was found to be as large as the colon; the cardiac end was described as being constricted, but as there was no evidence of disease or of a cicatrix, it is probable that it was an example of primary dilatation.

As to the cause of primary dilatation, Morell Mackenzie says it is probably due to general weakness, congenital or acquired, of the whole circumference of the œsophageal wall. It is remarkable that the muscular coat of the œsophagus should become greatly hypertrophied in cases of so-called simple dilatation. Dilatation with wasting and thinning of the muscular coat can be understood as a result of weakness, but dilatation with hypertrophy from analogy so forcibly suggests obstruction that, failing an organic one, it is not unreasonable to inquire whether it is possible that during life a functional obstruction may not have been present at the cardiac orifice of the stomach.

Apart from organic change, continued closure of the cardiac orifice might be due either to inhibition of contraction of the longitudinal muscular coat on the one hand, or to spasm of the circular muscular fibres on the other.

If the obstruction was spasmodic, some special hypertrophy of the muscular fibres forming the cardiac sphincter might have been expected.

The records of published cases do not make it plain that this is so, and in this specimen there is no sign of it.

Possibly a failure in the co-ordinating mechanism by which the

[1] 'Diseases of Throat,' vol. i, p. 117.

[2] 'Path. Soc. Trans.,' vol. xvii, p. 138.

cardiac sphincter is relaxed during swallowing—a kind of stammering with other organs than those of speech—might give rise both to hypertrophy and to dilatation of the œsophagus.

Paralysis or continued inhibition of the longitudinal muscular fibres of the œsophagus would allow dilatation of the tube to occur, and at the same time by interfering with the opening of the cardiac sphincter would induce hypertrophy of the circular muscular coat.

Simple dilatation with muscular hypertrophy can then be more satisfactorily explained as due to inhibition or atony of the longitudinal coat, than to the similar change in the whole musculature of the œsophagus.

In this case the vomiting appeared to be a neurosis intimately connected with whooping-cough. In that affection the manifestations are connected with irritation of the vagus; and simple vomiting, though it might lead to some hypertrophy, need not produce any dilatation of the œsophagus. Perhaps the dilatation was a late event in the course of vomiting, which, starting as a neurosis after pertussis, had become a habit. *December 3rd*, 1895.

---

4. *Diphtheria of the œsophagus.* (*Card specimen.*)

By E. W. Goodall, M.D.

History.—Richard S—, aged 8 days, was admitted to the Eastern Hospital at noon on November 30th, 1895. He was said to have had a "croupy cough" since birth, and a nasal discharge since November 29th.

The infant was exceedingly ill, in fact moribund on admission. A yellowish exudation could be seen on the palate, and there was an amber-coloured nasal discharge. He died at 1.23 a.m. on December 1st.

Diphtheria bacilli, long and short, were grown from the exudation on the palate.

At the *post-mortem* examination, made on December 3rd, there was membranous exudation on the palate and its arches and the epiglottis. The membrane extended down the œsophagus to within an inch or so of the cardiac orifice of the stomach. There was also extensive lobular pneumonia. The foramen ovale and ductus arteriosus were patent.

The specimen is preserved in the museum of the Royal College of Surgeons. *December 3rd*, 1895.

5. *Sarcoma of the œsophagus.*

By Cyril Ogle, M.B.

History of case.—The patient was a man aged 50, who had suffered from increasing difficulty in swallowing for three months, and from regurgitation of frothy fluid. Gastrostomy was performed, but death took place a week later from peritonitis and broncho-pneumonia.

At the autopsy no secondary growths were found either in the neighbourhood of the œsophagus or elsewhere. On laying open the gullet a polypoid growth like a small sausage was seen springing from its wall.

Description of specimen.—The tumour is attached to the left wall of the œsophagus at a distance of five inches below the cricoid cartilage. It is distinctly pedunculated, and may be described as consisting of two parts, a body and a pedicle.

The body of the tumour is moulded into a cylindrical or sausage-shaped mass, the long axis of which corresponds with that of the œsophagus. This mass measures 4 inches in length, and about an inch and a quarter in its shorter diameters. It has an uneven lobulated outline, but the surface is for the most part smoothly covered with mucous membrane. The body is directly continuous with the short pedicle.

The pedicle measures one inch in thickness where it is attached to the body of the tumour, but widens out considerably where it blends with the wall of the œsophagus. In the latter situation there is an oval plaque of growth which measures 1½ inches in its chief diameter, and is placed between the mucous membrane and the muscular coat of the gullet, in the submucous tissue. This plaque projects three eighths of an inch above the level of the mucous surface of the tube, and to its centre is attached the narrow pedicle of the main portion of the tumour as above described. Examination shows clearly that the growth has not invaded the muscular tissue, and that its path of extension is along the submucous coat. Beyond the fact that the calibre of the œsophagus is somewhat dilated at the seat of the tumour, there is no abnormal appearance in the remainder of the tube. There are no enlarged lymphatic glands.

On section the growth has a markedly homogeneous appearance, and is of soft consistency. Microscopical examination shows that it is made of sarcomatous cells, chiefly spindle-shaped, which are arranged in interlacing bundles, and the tissue is penetrated by a few thin-walled vessels. Some of the spindle-shaped cells are of considerable size, a feature which has been noticed in other specimens of sarcoma of the œsophagus. The preparation is preserved in the museum of St. George's Hospital.

March 17th, 1896.

Report of the Morbid Growths Committee on Dr. Cyril Ogle's specimen of sarcoma of the œsophagus.—We are of opinion that this tumour is a large spindle-celled sarcoma, which has originated in the submucous tissue of the œsophagus.

WALTER G. SPENCER.
J. H. TARGETT.
S. G. SHATTOCK, *Chairman.*

---

6. *Extensive malignant ulceration of the œsophagus.*

By J. H. TARGETT.

CLINICAL HISTORY.—The patient was a woman aged 54, who came under observation on January 26th for a swelling under the jaw on the left side. She had been ill for six months with neuralgic pains, followed in two or three months by dysphagia and hoarseness; and for some time past she had rejected her food occasionally on attempting to swallow it.

On admission the patient was sallow and had lost much flesh. The lungs and abdominal viscera were healthy. The glands in the left submaxillary region were enlarged and hard. Laryngoscopic examination showed that the left arytænoid cartilage was motionless, and the left vocal cord in the cadaveric position. An œsophageal bougie (No. 15) was stopped 12½ inches from the dental arch. After a little manipulation a No. 12 bougie was passed into the stomach. It was gripped in passing through the stricture, but loose when removed twenty minutes later. No blood or fragments of tissues on the bougie. During the next three months bougies were passed

from time to time, and the patient's condition on the whole improved, so that she gained flesh and strength and was able to go out for a walk.

On May 10th she began again to reject her food. A bougie (No. 9) was passed, and was thought to have entered the stomach, but on withdrawal it was found doubled up about 12 inches from the teeth, and it had evidently not passed the stricture. Smaller bougies were subsequently tried with success, and again the patient's health improved considerably.

On September 17th it was noted that dysphagia had been increasing for several days. Much frothy mucus was expectorated. Attempted intubation of the œsophagus failed, but the end of the tube was caught a little way below the larynx, and air at once passed through it during inspiration. After withdrawing the tube a little blood was coughed up. From this time a blood-stained muco-purulent expectoration continued, and any liquid swallowed became mingled with the sputum.

Signs of pneumonic consolidation supervened, and the patient gradually sank on September 29th, having been under observation for eight months.

Autopsy.—On removal of the œsophagus it was found that its posterior wall was firmly adherent to the pre-vertebral muscles, to the roots of the lungs, and to the arch of the aorta. Hence several lacerations in the wall of the gullet were made at the *post-mortem* examination. Subsequent dissection of the parts showed a very extensive ulceration of the œsophagus, beginning about 1½ inches below the cricoid cartilage, and reaching to a point fully two inches below the roots of the lungs. At no part of its course was there a projection as of a new growth. Opposite the roots of the lungs almost the whole circumference of the tube had disappeared, and it was here that adhesions had been contracted to the adjacent tissues, so that practically the wall of the canal was made up of the aorta, roots of lungs, and pre-vertebral muscles. Several perforations of the tube were found here on dissection, but there was no reason to believe that they had existed during life.

At the upper limit of the ulceration a fistula of considerable size in the anterior wall of the œsophagus passed directly into the trachea, and there was no doubt that the bougie had entered this fistula. Owing to the depth and extent of the ulceration, it was difficult to say whether much stricture had ever existed. What

appeared to be the narrowest part of the tube was exactly behind the left bronchus.

Microscopical examination of the edge of the ulcer showed that it was due to a squamous-celled epithelioma; the glands along the roots of the lungs contained secondary deposits.

Remarks.—The most remarkable feature of the specimen is the extreme degree to which the ulceration of the epitheliomatous growth has proceeded, and the absence of production of any new material. This is the more noteworthy since there was no clinical evidence of ulceration. The breath remained sweet, and the expectoration free from blood until a few days before death, and the passage of the bougies caused no bleeding until the opening into the trachea had been established.

About seven years before the onset of her fatal illness the woman had been under treatment as an out-patient for dyspepsia with doubtful phthisis, but no evidence of past tuberculous disease was found at the autopsy.[1]

December 3rd, 1895.

---

7. *Epithelioma of the œsophagus invading the trachea and left bronchus; extensive cystic degeneration of the secondary deposits in the liver and stomach.* (*Card specimen.*)

By Arthur F. Voelcker, M.D.

Description of specimen.—There is a large epitheliomatous growth in the œsophagus situated just below the level of the bifurcation of the trachea, which has invaded the trachea and left bronchus. The cardiac end of the œsophagus is free from growth.

Secondary deposits are seen on the small curvature of the stomach and in the liver. These nodules, even the small ones, show marked cystic change, a smooth thin layer of new growth alone being left as the wall of the cyst. There were a few small solid masses of new growth in the liver. The lungs show inhalation pneumonia and gangrene.

From a man aged 49, who died in Middlesex Hospital.

October 15th, 1895.

[1] This specimen has been described as an example of apparently simple ulceration of the œsophagus. See 'Brit. Med. Journ.,' 1892, vol. ii, p. 1173.

8. *Epithelioma in an œsophageal pouch.*

By G. Newton Pitt, M.D.

John C—, aged 50, a solicitor's clerk. At the age of twenty-five he was ill for twelve months with a very severe form of ulcerated throat; five years later he was again ill for a year with inflammation of the lungs. He enjoyed good health until 1891, when he had influenza. He has had indigestion for some years; no history of syphilis.

Two years ago he first noticed he had a slight difficulty in swallowing, but this did not become very troublesome until a year ago. He had no pain in swallowing. For between one and two years he has taken his meals alone because part of his food regurgitated, so that he required a porringer at his side into which to expectorate. The vomiting was looked upon as due to gastric disturbance.

Two months ago the vomiting became more frequent, and since then he has wasted greatly, although he has not had much pain. Latterly he has not been able to swallow anything but liquids. He was admitted under my care on December 20th, 1895.

He says that for fourteen days he has been unable to swallow even fluids, all attempts producing pain in the throat, and after half a minute the food produces a cough and returns up into his mouth again. Two days ago an œsophageal probang was used, but could not be passed beyond the cricoid. For two days he has had nutrient enemata. A spare man, not looking his age; he was able to walk up into the ward without assistance. He complains of intense thirst, is very hungry, and is not emaciated; the abdominal wall is retracted. The larynx appeared normal.

Mr. Jacobson recommended gastrostomy, but the man refused any operation, and it was not found possible to pass even the smallest œsophageal tube, the obstruction being just beyond the cricoid. The patient has painful internal piles.

He was fed with nutrient enemata, consisting of peptonised milk with meat juice and a nutrient suppository every four hours. For four days these were retained, the suppositories being stopped on the third day on account of the pain they caused. After this several enemata were returned, and he died of exhaustion on

December 28th, eight days after admission. He used quantities of tea, beer, and iced water to rinse out his mouth. The occurrence of the cough a short time after he had taken any liquid suggested the possibility of a communication between the trachea and œsophagus due to the growth, but turned out to be the result of the contraction of the pouch causing the fluid to be ejected over the surface of the larynx.

Autopsy.—Upon the posterior wall of the œsophagus on the right side, at the level of the lower margin of the cricoid, there is an aperture $\frac{5}{8}$ inch across, which leads into a pouch an inch and a half long. On the anterior wall of the pouch is an epitheliomatous growth which projects slightly into its cavity, and extends up to its orifice, but not into the œsophagus or pharynx. The pressure of the growth on the œsophagus produced so much obstruction that a finger could not be passed down.

It is clear that the œsophageal bougies passed into the pouch, and the case shows what great care is necessary in using them, as with very little pressure the bougie would have punctured the lower end of the thin-walled sac.

Microscopically the growth is a squamous-celled epithelioma with much small-celled infiltration of the connective tissue which forms the stroma. The specimen is preserved in Guy's Hospital Museum.

January 21*st*, 1896.

---

9. *Dilatation of the stomach.* (*Card specimen.*)

By R. G. Hebb, M.D.

The specimen came from a middle-aged man, who gave a history of vomiting and epigastric pain from April, 1895. On examination the stomach was found to be greatly distended. While in Westminster Hospital, where he was admitted November 13th, 1895, under Dr. Donkin, he frequently vomited, and occasionally brought up blood. Died February 2nd, 1896, of asthenia.

The stomach was found to be greatly dilated. The last three inches of œsophagus were much fibrosed, and the surface ulcerated. The first part of the duodenum was much stenosed, the circumference

at the narrowest part being just three quarters of an inch. The wall of the gut at this part is unusually thin. In the mucosa there is a furrow, parallel to the long axis of the gut, half an inch long. This probably represents the cicatrix of a healed ulcer to which the stenosis is due. The pylorus is dilated. *April 21st*, 1896.

---

10. *Multiple polypi of stomach and intestine.*

By William Collier, M.D.

History.—A man aged 21 was admitted to the Radcliffe Infirmary on June 28th, 1895.

His illness commenced about twelve months previously with pain across the upper part of the abdomen and vomiting. These symptoms increased in severity during the last six months. On one or two occasions the vomit was blood-streaked. Pain did not seem to be affected by food.

Condition on admission.—The patient looked anxious and very decidedly ill. Nothing was discovered in the abdomen to account for the pain and vomiting. While in the infirmary he vomited daily, and often complained of severe abdominal pain. Bowels confined; he was put on a fluid diet.

On the evening of July 10th the patient was seized with more than usually severe abdominal pain, and the vomiting became urgent. The following morning a distinct tumour could be made out running obliquely across the abdomen from right to left. This was considered to be most probably an intussusception, and it was decided to open the abdomen. On this being done a large intussusception was found commencing within a few inches of the pylorus. This was easily reduced, but the patient's condition did not improve, and he died about twenty hours after the completion of the operation.

July 12th.—On *post-mortem* examination an enormous number of polypi were found, varying in size from a pigeon's egg to a pea; they were scattered throughout the stomach and small intestines, the greatest number being in the duodenum and upper part of the jejunum. Many of them were furnished with long pedicles.

The specimens are preserved in the museum of the Royal College of Surgeons. *October 15th*, 1895.

11. *Tuberculous ulceration of the ileum with perforation.* (*Card specimen.*)

By Hugh Walsham, M.B.

The specimen was taken from the body of a man aged 43, who died of chronic pulmonary tuberculosis and peritonitis.

On opening the abdomen the coils of intestine occupying the right iliac fossa and pelvis were found matted together by recent adhesions. On separating the coils a large perforation was found in the ileum about two inches from the ileo-cæcal valve. On opening the gut this perforation was found to be in the floor of a large tuberculous ulcer, which completely surrounded the circumference of the bowel. The ileo-cæcal valve was almost completely destroyed by ulceration. Two more large tuberculous ulcers were found higher up the ileum. The large intestine was free from ulceration. The mesentery contained many miliary tubercles. The mesenteric glands were enlarged and tuberculous. The liver and kidneys had many tuberculous nodules scattered through their substance.

March 3rd 1896.

---

12. *A diverticulum ilei of unusual length and position.* (*Card specimen.*)

By Bilton Pollard, B.S.

Description of specimen.—At a distance of 24 inches from the pylorus the intestine bifurcates. The two segments are similarly supplied with mesentery, so that it is only by tracing them that the true intestine and the diverticulum can be distinguished. The diverticulum after a course of 36 inches reaches the umbilicus, beyond which it originally terminated as a large

cul-de-sac in the umbilical cord. The other segment of the intestine terminates at the ileo-cæcal valve after a course of 63 inches.

There was no other malformation.

The specimen is preserved in the museum of the Royal College of Surgeons.

April 21*st*, 1896.

---

13. *A diverticulum ilei attached to the mesentery.* (*Card specimen.*)

By Hugh Walsham, M.B.

The specimen was taken from the body of a man aged 39, who died of chronic pulmonary tuberculosis.

The diverticulum is situated about three feet from the ileo-cæcal valve. It is about 4 inches in length, and is firmly attached by its extremity to the mesentery. Nothing was found in the diverticulum.

November 19*th*, 1895.

---

14. *Caseous mass attached to the cæcum.* (*Card specimen.*)

By Hugh Walsham, M.B.

From a man aged forty-four, who died of chronic pulmonary tuberculosis.

The specimen consists of the cæcum with portions of the ileum and ascending colon. Attached to the end of the cæcum by a mesentery is a small flattened mass about the size of a cobnut. The outer surface is distinctly granular. On section the mass appears to be partly caseous and partly fibrous. Under the microscope a few giant-cells are seen in the sections, mostly confined to the periphery of the mass.

There were a few small tubercular ulcers in the small intestine. The mesenteric glands were not enlarged or caseous, but quite fresh miliary tubercle was scattered throughout the mesentery.

December 3*rd*, 1895.

15. *Three cases of ulcerative appendicitis.*

By WILLIAM HUNTER, M.D.

CASE 1.—A cæcum and portion of ileum removed from a boy aged 13, under the care of Dr. Green, Charing Cross Hospital.

The appendix is considerably thickened, and bound down throughout its length (1 inch) to back of cæcum. At about its middle an ulcerated aperture is seen, through which communication has taken place between the lumen of the appendix and adjacent extra-peritoneal tissues. The adjacent lymph glands are enlarged and soft; in the recent state they were red, soft and swollen. The appendix was filled in recent state with dirty grey pus; and the surrounding tissues were in a dark, sloughy condition.

History.—Admitted December 11th, 1895, as a case of "enteric fever." Died December 17th, 1895. Seventeen days before admission was seized with vomiting, shivering, profuse sweating, and diarrhœa; and since then daily attacks of shivering and sweating.

After admission daily rigors, followed by profuse sweating, average temperature during rigor being 104·2° F. Heart's action was rapid and tumultuous, with an apical systolic murmur, changing in character daily. Two days before death a presystolic thrill felt. Liver extended down to umbilicus, was tender on pressure, and friction sounds heard over it. Spleen felt below costal margin.

Autopsy.—Peritoneal cavity contained 18 oz. of clear straw-coloured serum.

Liver projected 3 inches below costal margin; weight 56 oz. The posterior part of its right lobe was occupied by a large swelling 6 × 4 inches in diameter, studded with points of suppuration. On section greater part of right lobe occupied by multilocular abscess cavity, filled with dirty yellowish pus; the liver substance around soft and inflamed. There was recent local peritonitis over liver, but no general peritonitis.

Portal vein filled with partially broken-down blood-clot and dirty grey pus, its walls and its branches throughout the liver being surrounded by pus.

Small intestine.—No change. *Large intestine* shows some prominent follicles.

CASE 2.—A cæcum and portion of ileum removed from a woman

aged 35, admitted into Charing Cross Hospital on December 30th, 1895, under the care of Mr. Boyd, and died the following day.

There is great matting and thickening of tissues around cæcum and appendix. The appendix forms a thick, somewhat flattened cord 2 inches long, $\frac{3}{4}$ inch across, with truncated end, and is traversed by a dark sloughing channel corresponding to the lumen; close to the cæcum there is an ulcerated opening $\frac{3}{4}$ inch long. Around this there was an abscess cavity containing 8 oz. of fæcal-smelling pus; and an oval fæcal concretion, $\frac{3}{4}$ inch long by $\frac{3}{8}$ inch wide, was removed. The apex of the appendix, $1\frac{1}{2}$ inches long, was removed by operation during life.

History.—There was a history of illness for a week previous to admission; then acute pain two days before admission, followed by hiccough and cold clammy sweats.

At the operation an abscess cavity was opened, and 8 oz. of fæcal-smelling pus evacuated, with a brown fæcal concretion of the size of a plum-stone, and $1\frac{1}{2}$ inches of a greatly thickened appendix was removed (thickness that of the middle finger). The mucous membrane lining the canal of this portion was in a dark, sloughy condition.

Autopsy.—There was recent diffuse general peritonitis, with matting together of intestines, and more localised collections of pus were found between small intestine and transverse colon, and in the region of the hepatic flexure. There was great inflammatory œdema of extra-peritoneal tissues around right kidney, and in right flank behind ascending colon.

The abscess cavity close to cæcum lay over the ulcerated opening in the appendix, its wall formed partly by the exposed lumen of the appendix, partly by the thickened surrounding tissues. No secondary abscesses were found in liver or other organs.

Case 3.—A cæcum and portion of ileum removed from a child aged 6 admitted into Charing Cross Hospital under the care of Dr. Abercrombie.

The peritoneal coats of cæcum and ileum are coated with yellowish lymph. The appendix is about two inches in length, its apex adherent to ileum. The greater part of it is extensively ulcerated, and in recent state was in a gangrenous condition. The proximal portion of the appendix is healthy.

There was extensive suppurative peritonitis, the whole of the

abdomen below umbilicus forming an abscess cavity, communicating with more localised collections of pus in right and left flanks and hypochondria. The appendix lay on brim of pelvis, and projected into abscess cavity, occupying Douglas's pouch.

History.—Admitted for abdominal pain and vomiting, sudden in onset, ten days previous to admission. After admission there was diarrhœa (four to nine motions daily). Fever varying from 100° morning to 102° evening; daily vomiting, tenderness over abdomen, and rigidity of abdominal walls over lower part. Death occurred ten days after admission, temperature day before rising to 105·4°.

March 3rd, 1896.

---

16. *A vermiform appendix eight inches long containing a concretion. (Card specimen.)*

By W. J. Tyson, M.D.

The specimen shows an appendix which measures eight inches in length. At two inches from its distal extremity there is an ulcerated opening an inch long. The whole tube was attached to the cæcum and ascending colon.

The concretion was found lying in a small abscess cavity which had ruptured into the general peritoneal cavity. It is ovoid in shape, measuring in length ¾ inch, and in width ½ inch; there is on its surface a short spinous process.

History.—The man from whom the specimen was taken was 20 years of age. Taken ill on Saturday, April 11th, 1896, and admitted into the Folkestone Hospital on the following Tuesday with well-marked signs of appendicitis, sickness, great localised pain between umbilicus and right anterior superior spine, tenderness on pressure, and impaired dulness.

The collapse which took place on the day following admission indicated a perforation of the appendix. Death followed on the Monday, nine days from commencement of illness. General suppurative peritonitis was found at the autopsy. *May 19th*, 1896.

---

17. *Mucous casts of the large intestine, passed during several months, in a case of cancer of the colon, with great hypertrophy of the bowel above the seat of stricture.*

By P. H. Pye-Smith, M.D.

S. W—, a woman aged 50, was admitted into Guy's Hospital under my care at the beginning of December, 1895. She had during the whole year and part of 1894 been suffering from constipation, with distension of the abdomen and occasional attacks of diarrhœa; and all this time she had been passing at frequent intervals large soft gelatinous shreds, and more or less complete cylindrical casts. She was much wasted, and suffered from griping pains, with visible peristalsis of the bowels. There was, however, little vomiting or fever, and no sign of peritonitis.

The membranous casts, which were seldom absent from a stool, were unstained with biliary pigment; they were soft but consistent, sometimes mere fragments, but sometimes complete cylinders one and a half or two feet long. Chemically they consisted of mucin, not fibrin, and microscopically showed no tissue-structure, only a few leucocytes scattered through the mucus. They were passed in such abundance that I did not think it possible they could all be produced from the mucous membrane below the sigmoid flexure, the most likely place for the stricture, and therefore was led (as it proved erroneously) to fix it in the transverse colon. It seemed probable from the patient's age, and the absence of acute symptoms or of secondary tumours, that the obstruction was due to an annular stricture independent of the membranous colitis, and this had been the conclusion of my colleague Dr. Goodhart, under whom the patient had been earlier in the year. The operation of colotomy was proposed but declined. The bowels were kept tolerably open by means of enemata, but she became thinner and weaker, and at last died suddenly and painlessly by syncope.

The abdomen was found after death filled by the enormously thickened and distended colon, of which a specimen is shown. When cut open it remained stiff like a bag of thick india rubber. There were several pouches in the mucous membrane, and the longitudinal as well as the circular fibres of the muscular coat were

hypertrophied. The mucous membrane was smooth and unchanged not only in this distended part of the colon, but also below the stricture. This consisted of an annular carcinoma which just admitted a No. 6 catheter, and was situated near the beginning of the sigmoid flexure. There were two or three carcinomatous lymph glands in the mesocolon, but no other secondary growths throughout the body. It was remarkable that not only the ascending transverse and descending colon were hypertrophied in the way described, but the small intestine partook in the same change. The ileum just above the valve measured four inches in circumference, the colon above the stricture nine and a half inches, both taken on the mucous surface.

The colon below the stricture and the rectum were contracted, and contained mucous casts like those passed during life. When these were washed off, the surface of the mucous membrane was found to be unaffected.

The pelvic, thoracic, and other viscera were healthy.

I have found only two similar cases recorded in our 'Transactions,' although they are not perhaps so rare as this would imply. The first case, recorded in 1850 by Mr. Hutchinson, was reported upon to the Society by Dr. Wilks and Dr. Andrew Clark (vol. ix, p. 188, pl. viii). It consisted of gelatinous, not fibrinous casts, but they contained numerous columnar epithelial cells, and also perforations which answered to the mouths of Lieberkühn's tubules.

The second case was contributed by Dr. Goodhart in 1882 (vol. xxiii, p. 98, pl. i). Like the last, and like my own, it occurred in a middle-aged woman; it agreed in the gelatinous condition of the casts, but differed in the fact that the casts were solid, not hollow tubes.

These cases are clearly distinguished in pathology from those of membranous (so-called "croupous" or "diphtheritic") colitis with fibrinous exudation on an inflamed surface, and also from the still rarer case of sloughing of a ring of mucous membrane, of which I had a remarkable instance in 1887 (cited in Fagge and Pye-Smith's 'Text-book of Medicine,' vol. ii, p. 242). The present case, like those of Mr. Hutchinson and Dr. Goodhart, appears to be one of excessive secretion of a thick gelatinous mucus by the tubular glands of the colon, without any inflammation, or indeed participation of the epithelial surface of the mucosa.

January 21st, 1896.

18. *Extensive ulceration of the large intestine in a case of enteric fever.* (*Card specimen.*)

By Arthur F. Voelcker, M.D.

The colon shows extensive honeycombing, which is most marked in the splenic and sigmoid flexures. The cæcum shows no ulcers. The ulcers appear to commence as a follicular enteritis, and their increase in size appears to be due to distension of the colon. There were soft fæces in the distended colon, but they were not adherent to the ulcers. The small intestine shows healing typhoid ulcers (about twenty-third day).

From a woman aged 49, who was admitted for enterica into the Middlesex Hospital, and died from heart failure.

October 15*th*, 1895.

---

19. *The parts concerned in the radical cure of inguinal hernia six months after the operation.*

By Henry T. Butlin.

The patient was a boy 3 years of age, who was admitted into St. Bartholomew's Hospital May 25th, 1895. He was suffering from a right inguinal hernia, with some doughy thickening in the lower part of the sac above the testicle, which led to the belief that there might be adherent omentum.

On May 29th the right inguinal canal was opened through the aponeurosis of the external oblique; the sac was found and opened. Some straw-coloured fluid issued through the opening, and when the abdomen was gently pressed several ounces of similar fluid escaped. The sac was carefully examined, and its interior was discovered to be studded with miliary tubercles. The doughy swelling above the testicle was found to be a softening mass of tubercle. This was dissected away. The sac was separated from the surrounding tissues, transfixed at the internal ring, tied with catgut in two halves, twisted, and one end of the ligature passed

through it to maintain the twist. The end of the sac was cut off, and the stump was fastened with catgut to the under surface of the internal oblique muscle. The aponeurosis of the external oblique and the skin were sewn with very fine fishing-gut sutures. The operation was performed with strict antiseptic precautions. The wound healed by the first intention, and remained firmly healed up to the time of the patient's death. The slight fulness of the abdomen which had existed before the operation gradually subsided.

June 28th.—The patient was sent to the Convalescent Hospital at Swanley.

July 12th.—Sent back to the hospital from Swanley on account of pain in the right hip. Found to be suffering from commencing disease of the hip-joint.

September 20th.—Abscess diagnosed in front of the hip-joint.

October 1st.—Abscess opened.

December 17th.—Symptoms of meningitis noted, which rapidly developed and proved fatal on December 22nd.

Post-mortem examination.—Firm scar in the right inguinal region. At the site of the internal abdominal ring on the peritoneal aspect a mass of pigment in the peritoneum. No pocket or depression. The canal was firmly consolidated. Abdomen: numerous tubercles on the peritoneal surface of the liver, and a few thickened patches on the surface of the spleen. Otherwise no tubercle found either on the peritoneum or in the viscera. Chest: no tubercle. Head: tuberculous meningitis at base of brain. Neck: slight enlargement of some of the cervical glands. Owing to the changes which had taken place in connection with the presence of tubercle, there was some doubt whether the hernia was congenital or not. I am disposed to think it was not congenital.

The case is of interest, not only on account of the condition of the parts which had been the seat of operation, but because the operation had been performed on a subject actually suffering from tubercle of the sac. The fluid in the abdomen at the time of the operation suggests that the peritoneum was at that time the seat of disseminated tubercle. After the death of the patient tubercle was only found in the peritoneal coverings of the liver and spleen, so that it may be believed that the operation was the means of causing the removal of many miliary tubercles from the abdomen, especially as, during the first few weeks after the operation, the abdomen became very much smaller. *April 21st*, 1896.

20. *The parts concerned in the radical cure of inguinal hernia two years after the operation.*

By James Berry, B.S.

The patient from whom this specimen was obtained was a woman aged 58, who died in St. Bartholomew's Hospital of perforation of a duodenal ulcer two years and three months after an operation for the radical cure of a right inguinal hernia. The operation had been performed by Mr. Alfred Willett, to whom I am indebted for permission to show the specimen, and had been perfectly successful. The hernia was an ordinary labial hernia, of moderate size. The operation consisted in dissecting up the sac, tying it with silk, and cutting it away; the pillars of the external ring were then united with the same material. The wound healed apparently by first intention, but two weeks later a little localised suppuration took place at the upper part of the scar, and a suture was removed. The wound then quickly healed. The specimen shows that the whole of the inguinal canal has been filled up with dense fibrous tissue. The situation of the internal ring is indicated by a slight puckering of the peritoneum over it. The external abdominal ring has been almost obliterated. There is no local bulging of the abdominal wall. *April* 21*st*, 1896.

---

21. *Case of infantile hernia on which radical cure was performed (MacEwen's method); death five days after operation.*

By C. H. Golding-Bird.

The specimen shown is from a man aged 38, who died five days after an operation for the radical cure of an inguinal hernia by MacEwen's method. As the case proved to be a form of infantile hernia, a short clinical note will be of interest. The man on February 7th, 1895, was admitted into Guy's under my care with an irreducible right inguinal hernia of large size, in a semi-strangulated condition. The patient stated he had had the hernia all his life; he

could always reduce it whenever it came down until now, sometimes easily, and at other times it took him hours to do so, and he had to use great force: of this last statement the now bruised state of the scrotum bore evidence.

For two days he refused to have anything done, but getting worse he then consented.

Under an anæsthetic the scrotal hernia was returned with the greatest ease, but as something seemed left behind, I operated. On opening the scrotal tumour I found I had entered a distended tunica vaginalis, open up to, but not into the abdomen. The testis, which was small and flattened, was completely enclosed in a mesorchium which projected from the posterior wall of the tunica vaginalis for about two inches. This mesorchium was itself distended above the testis, and on opening it by a vertical incision I found the true hernial sac empty. The finger in the tunica vaginalis could not enter the abdomen; the serous sac being normally closed. The tissue composing the mesorchium was loose and vascular, and in it the hernial sac lay. Hence to reach the interior of the sac three layers of peritoneum were divided, viz. the parietal layer of the tunica vaginalis, the anterior layer of the mesorchium, and then that of the hernial sac itself.

I determined to obliterate the sac, and did so by MacEwen's method; the detachment of the sac right up to the general peritoneum presented no difficulty, and the operation was completed *secundum artem*.

The patient, however, after recovering from the anæsthetic was profoundly collapsed, and more or less in this state he lingered till the fifth day; symptoms of peritonitis also supervened. His condition precluded the possibility of further operation, nor was it clinically evident why, after the operation, his state had not improved.

At the autopsy, made by Dr. Newton Pitt, the cause of death was found, and the specimen handed round shows it. There was general peritonitis, but the local changes as now seen are as follows:

The incision into the scrotum and tunica vaginalis are seen; then that into the mesorchium, the loose cellular tissue of which is recognisable. On the abdominal aspect of the specimen, in the subperitoneal tissue, and in about the position of the inner ring, is seen the accordion-pleated hernial sac, now not much larger than a filbert, and a probe passed up the substance of the mesorchium, along the track where

the hernial sac lay, impinges now upon this crumpled mass representing the sac. Close by it is seen the peritoneal inner ring, which the operation had not closed (for reasons that will be seen directly), and through it projects a knuckle of bowel into the peritoneal tissue. It has no sac. At the autopsy this knuckle was almost in a gangrenous state, and its non-reduction was clearly the cause of death.

FIG. 2.

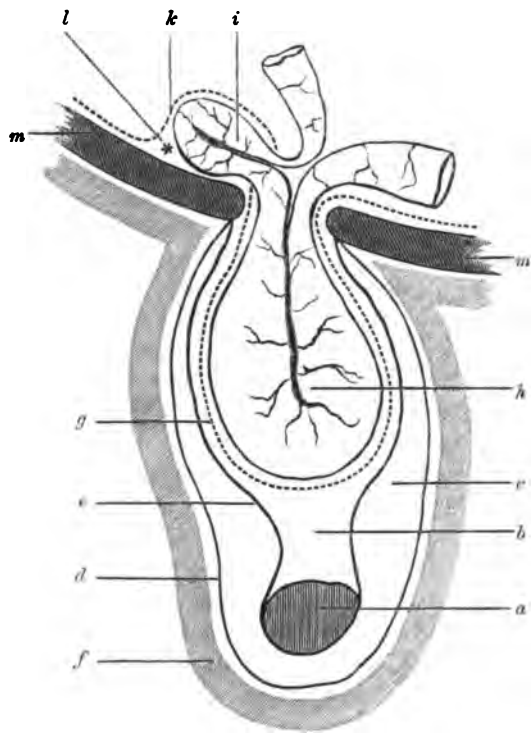

a. Testis. *b.* Mesorchium. *c.* Cavity of tunica vaginalis. *d.* Parietal peritoneum of tunica vaginalis. *e.* Reflected peritoneum covering mesorchium. *f.* Scrotum. *g.* Peritoneal sac of hernia. *h.* Gut in sac. *i.* Knuckle of bowel strangulated outside peritoneum through aperture in neck of the main sac. *k.* General parietal peritoneum. *l.* Subperitoneal space. *m.* Musculature of abdominal walls.

The order of events appears to have been that the patient before admission used all but brute force to effect reduction, and succeeded in driving a knuckle of bowel through a rent in the neck of the sac just below the general peritoneal level. The bulk of the intestine,

however, remained in the scrotum. Under the anæsthetic this was easily returned, and the sac appearing quite empty to digital examination, I performed the radical cure, never suspecting a subperitoneal protrusion of a knuckle at the inner ring; and hence also when the silk suture puckered up the sac in the usual fashion, it could only do so as far as to where this knuckle protruded, and consequently the opening of the hernial sac at the general peritoneum was not obliterated.

This excepted, the specimen shows well the mechanics of MacEwen's operation; how the sac is both completely obliterated, and at the same time forms a cushion outside the peritoneum at the inner ring, converting what was a depression leading to the sac opening into an eminence, and so directing the bowel away from the spot where its constant impinging might reproduce the rupture.

I should add that Dr. Newton Pitt considered it likely that the knuckle, which now is seen lying without any sac, may have had one; in fact, that it entered one of the diverticula from the sac on its posterior wall which are known to develop sometimes in infantile hernia.[1]

The state of the parts at the time of the *post-mortem* was such that no immediate dissection could be made, and now a careful examination of the specimen (coupled with the known fact that the man had used extraordinary force in attempting reduction) makes me adopt the view I have expressed, viz. that the peritoneum had been ruptured, and not that there was a pre-existing lateral pouch from the main sac. *April* 21*st*, 1896.

---

22. *Case of hour-glass constriction of the sac of a femoral hernia.*

By Macpherson Laurie (per J. H. Targett, M.S.).

History of case.—The patient was a woman aged 21, who came under observation on account of a swelling about the size of a small hen's egg, situated in the left groin below Poupart's ligament.

[1] An almost identical case of infantile hernia in the practice of M. le Cat (1750) is quoted by J. Macready, 'Treatise on Rupture,' p. 82.

She first noticed the swelling two and a half years previously, after a sudden straining effort. It had not increased much in size since its first appearance. She suffered at intervals from a good deal of pain, and was compelled at those times to lie up for a few days. She was then able to push it partly up, but some protrusion always remained.

On examination the swelling was found to be a femoral hernia, rather tender to the touch, and distinctly constricted at its middle. The patient was advised to go to London in order to be fitted with a truss. After careful trials the truss maker reported that it was impossible to obtain a satisfactory result by mechanical appliances. An operation was therefore decided upon. After the preliminary incisions the sac was separated from its bed and pulled down from the crural canal, so that the neck could be transfixed and tied by locked ligatures of silk. When the sac had been removed the proximal end of the peritoneal pouch slipped back into the abdomen.

A good recovery ensued from the operation, and no further discomfort was experienced.

Description of specimen.—The appearance of the sac on removal being somewhat peculiar, it was distended with water from a tap, and found to consist of a serous pouch constricted near the middle by a tight ring, so that in shape it resembled an hour-glass. After further dissection the following notes were made :—The lower compartment of the preparation is formed by an oval serous cyst measuring an inch and a half in its chief diameter. The upper compartment is an incomplete space bounded by a broad fringe of peritoneum, the margin of which represents the cut edge of the hernial sac. These two compartments communicate through a round aperture about the size of a No. 12 catheter. This aperture is bounded by a narrow hard ring of thickened peritoneum, which is clearly a part of the substance of the sac wall. There are no signs of old peritonitis or adhesions.

Remarks.—The occurrence of a constriction in the sac of a femoral hernia is sufficiently rare to be worthy of comment. Two explanations present themselves. The narrowed part may correspond with the line of pressure on the hernial sac caused by the tight edge of a small saphenous opening. Under such circumstances an annular stricture would not be expected, in consequence of the well-known character of the saphenous opening. A more probable view is that which regards the constriction as the original

neck of the femoral hernia formed at the crural ring, or upper aperture of the crural canal. By a subsequent development of the hernia, the primary sac with its narrow neck has been thrust further down the crural canal, permitting the formation of a secondary hernial sac behind it. Thus the preparation represents two stages in the development of this rupture, and the condition corresponds exactly with what is not unfrequently observed in the large sacs of an inguinal or scrotal hernia, in which as many as four compartments have been described. Perhaps the reason why the condition is so rare in femoral hernia may be found in the narrowness of the crural canal, the greater rigidity of the surrounding parts, and the absence of that laxity in the peritoneal connections which is so marked a feature of a large inguinal sac.

April 21*st*, 1896.

---

23. *Pedunculated cysts pendent within a hernial sac.*

By C. B. Lockwood.

Whilst operating upon a non-strangulated hernia I met with certain cysts which projected into the sac. This communication gives a description of these cysts and discusses their pathology.

I am not aware that anything of the same kind has hitherto been recorded, and our museums contain nothing similar, nor does the Musée Dupuytren.

The case was that of a youth aged eighteen years. He stated that he had had a right inguinal rupture for six months. He had never worn a truss. Before the operation it was clear that there was a complete inguinal hernia upon the right side. The lower part of the sac was full of fluid, whilst the upper part contained something which was guessed to be omentum. I did the usual open operation for radical cure, the inguinal canal being laid open. But when the sac was slit up, two small pedunculated bodies came out with the fluid. They looked exactly like nasal polypi, and each was fastened to the back of the sac by a slender stalk. The size

and relations of these bodies is shown in the accompanying sketch (Fig. 3). The hernial sac was of the funicular variety, with a constriction about its middle. The smallest of the projections sprang from the hinder wall of the sac about a third of an inch above this constriction, whilst its larger companion was attached just below the constriction. These relations are shown in the accompanying

FIG. 3.

FIG. 4.

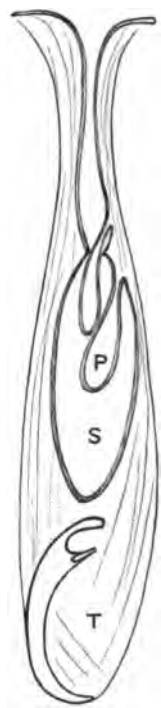

FIG. 3.—Hernial sac laid open to show the pedunculated bodies. P. Pedunculated bodies. S. Sac. T. Testicle.

FIG. 4.—Diagram to show relation of pedunculated bodies to hernial sac. P. Pedunculated bodies. S. Sac. T. Testicle.

diagram (Fig. 4). The constriction seemed to have no other relationship to these projections, except that the smaller one passed through it from the upper into the lower part of the sac. As I have said, these bodies when fresh looked like ordinary mucous polypi of the nose, and were gelatinous and semi-transparent. After a short sojourn in spirit and water they became opaque, and similar in

appearance to the rest of the sac wall. The upper and smaller body has collapsed since it was put in spirit, and is now shrunk and shrivelled, and not at all like what it was when fresh. Indeed, the whole specimen is much altered and damaged. The drawing was made from a sketch which was made directly after the operation. An incision into these pedunculated bodies showed them to be hollow with a narrow canal passing through their stalks to open by a minute orifice upon the exterior of the sac. These orifices were concealed by the muscular fibres of the internal cremaster, which, together with the other elements of the cord, was closely related to the whole length of the back of the sac. The larger pedunculated cyst contained clear fluid, and its interior was smooth. The smaller one certainly contained fluid, and may have had a cavity in it, but it was not easy to be sure by a mere naked-eye examination. In the upper part of the sac, and a little above and to one side of the attachment of the smaller cyst, are two other projections from the sac wall (Fig. 3). These are pedunculated and about a quarter of an inch long. I could not tell with certainty whether they were hollow like their largest companion. Despite the youth's assertion that he had only noticed a rupture for six months, it is probable that his hernial sac was congenital and not acquired. The cause of the constriction in its midst is obscure. As the sac lay in its position the constriction was opposite the external abdominal ring. The action of the spirit has made it look much tighter than it was in the fresh specimen. It has hardly any resemblance to those constrictions of hernial sacs which are caused by the displacement of a thickened, callous, and contracted neck of the sac. As is well known, such a neck is often thrust down by a fresh hernial protrusion.

As regards these pedunculated cysts, it is hardly necessary to say that they have no resemblance to any kind of infantile hernia, nor do they lend any countenance to Sir Astley Cooper's theory of encysted hernia, which I endeavoured to disprove some years ago.[1] Obviously no hernial protrusion could by any possibility have got into their interior, even had they been sufficiently capacious. The only peritoneal structures which resemble them at all closely are the appendices epiploicæ; but they are never hollow, so far as I am aware, their interior being filled with fat. But even if the likeness

[1] "The Morbid Anatomy and Pathology of Encysted and Infantile Hernia," 'Med.-Chir. Trans.,' 1886, vol. xlix, p. 479.

to the appendices epiploicæ were much closer, the comparison would throw little light upon their origin, because we seem to be singularly ignorant of the origin and uses of the appendices.

On the other hand, it is quite common to meet with pedunculated cysts growing into the tunica vaginalis from about the head of the epididymis. These contain no spermatozoa, and probably originate from the Wolffian tubules.[1] It requires, however, rather a stretch of the imagination to suppose that the Wolffian tubules could persist along the whole of the back of the processus vaginalis. There is, nevertheless, nothing improbable in this supposition, because originally the Wolffian body of the human embryo is continuous from the adrenal, which is developed from its fore-part, to the epididymis, which is developed from its hinder part.[2] On the whole I am inclined to attribute some such developmental origin to these pedunculated cysts projecting into this hernial sac.

The pedunculated bodies and cysts which sometimes originate in connection with the abdominal opening of the Müllerian ducts could hardly be concerned in the production of these cysts; but there is a specimen in the museum of St. Bartholomew's Hospital[3] which shows that cysts may project into the sacs of undoubted acquired hernia. It is the sac of a femoral hernia which was removed by Mr. Langton. The main sac has no peculiarity, and opened by a narrow mouth into the general peritoneal cavity. But at one side of this main sac is a sessile cyst almost as large as a walnut. It is attached to the wall of the main cyst by a broad but distinct neck. Its shape is irregularly round, and a concentric fold forms a partial septum in its interior. The hole which opens through its neck upon the outside of the sac is obviously an artificial production.

Thus it is evident that cysts may project into hernial sacs quite apart from any developmental cause. *February 4th*, 1896.

[1] "Observations on the Appendix of the Testicle and on Cysts of the Epididymis and Vasa Efferentia and Rete Testis," Joseph Griffiths, 'Journ. of Anat. and Phys.,' vol. xxviii, p. 110, &c.

[2] 'Hunterian Lectures on the Development and Transition of the Testicle,' by C. B. Lockwood, 1888, p. 76, fig. 47.

[3] Specimen 2087A.

24. *Tuberculous liver with lardaceous disease.* (*Card specimen.*)

By Hugh Walsham, M.B.

This specimen was taken from a woman aged 32, who died chronic pulmonary tuberculosis.

Caseous nodules are scattered throughout the liver, and the organ is also in an advanced stage of lardaceous disease. The spleen and kidneys were markedly lardaceous. There was extensive tubercular ulceration of the lower end of the ileum, but the large intestine and rectum were free from ulceration.

On microscopical examination tubercle bacilli were found in the caseous nodules. *December 17th*, 1895.

---

25. *Circumscribed fatty patches in the liver.* (*Card specimen.*)

By F. Parkes Weber, M.D.

The first specimen is from the free margin of a liver close to the round ligament. At the *post-mortem* examination a small, pale, circumscribed patch was observed in this part of the liver, differing much in appearance from the rest of the organ. The difference in appearance may be compared to that between a small area of xanthelasma and the skin around it. On cutting into the patch at right angles to the capsule, the whitish appearance was found not to be confined to the tissue immediately below the capsule, but to extend for about half an inch into the hepatic substance; and half an inch was, I think, the maximum dimension of this paler portion of the liver.

The mottled appearance of part of the patch, when viewed with the naked eye, suggested a localised fatty *infiltration* as its probable cause, and that this is the correct explanation is, I think, proved by the microscopical preparations stained with hæmatoxylin and those stained with osmic acid.

Nothing else worthy of mention was found in the liver, excepting a syphilitic cicatrix at some distance from the fatty patch. The patient was a woman aged 61, who died of syphilitic disease of the

sphenoidal bone, and a short note of her case has been given elsewhere with an account of the condition of her coronary arteries (p. 17).

The second specimen is from a liver in which there were miliary fatty spots. At the *post-mortem* examination this organ was remarkable by its containing many small pale spots both beneath the capsule and in deeper parts. To the naked eye these spots did not look exactly like tubercles, and their nature was uncertain.

Under the microscope their nature became evident, each spot being due to an extreme fatty change in the hepatic cells of a minute and sharply circumscribed area. Osmic acid of course made their nature still more evident. I must thank Dr. Gee for his kindness in allowing me to show the specimen with that from my own case.

The patient was a man, aged 27, who was admitted in a collapsed state to St. Bartholomew's Hospital on February 24th, 1894, and died the same day. At the necropsy (on the following day), pleuro-pneumonia of the right lung was found. The other morbid conditions present were—old pleuritic adhesions, the remains of an old tuberculous process at the pulmonary apices, some atheroma of the aorta, and caseous changes in the supra-renal capsules. The right capsule weighed one and a half ounces. There was no bronzing.

In a third case I have seen similar minute white spots in the liver, which microscopical examination proved to be of a fatty nature; in that case, however, the spots were only noticed just beneath the capsule.

Though I have found no published description of these circumscribed fatty spots in the liver, I think it very improbable that they have really escaped notice. The miliary spots are, I think, especially worthy of mention, because it is possible, without microscopical examination, to confuse them with tubercles.

Whether they have any special pathological importance is doubtful. They may (at least the first specimen) perhaps be regarded as an irregular fatty infiltration of the liver, due to an individual idiosyncrasy, analogous to that which leads to irregular pigmentation of the skin (sun-freckles, &c.) or to that which leads to an irregular distribution of subcutaneous fat (small multiple lipomata).

I have to thank Mr. Shattock for explaining a puzzling appearance in the osmic acid section of the second case, a section

which was mounted in Farrant's solution four years ago. The appearance is due to the presence of minute bubbles of air under the coverslip, which have caused black spots to appear in the section, so as to superficially imitate the true osmic acid staining. The explanation of the presence of these spurious spots, strange as it may seem, was not obvious at first. They threw discredit on the true fatty spots, and suggested that the localised changes were not of a fatty nature after all. That the true spots, however, are really fatty, Mr. Shattock, after a careful examination of the specimen, has no doubt. Moreover, when the specimens were examined four years ago, no doubt of this sort could have entered one's mind.

March 3rd, 1896.

---

26. *Perihepatitis; thrombosis of inferior vena cava at point of entry of hepatic veins; ascites and great varicosity of superficial veins over anterior thoracic and abdominal parietes.* (*Card specimen.*)

By Frederick Willcocks, M.D.

This specimen is taken from a child (Julia W—), aged 1 year and 10 months, who was admitted into the Evelina Hospital for Sick Children in December, 1894, and died on October 14th, 1895. Her illness commenced with an attack of vomiting, but previously she had enjoyed fair health. The family history was good, and no definite history of congenital syphilis was obtainable. The abdomen became rapidly distended with fluid, and the veins over the front of the abdomen and chest were very prominent and tortuous. There was no œdema of the legs and feet, which remained cold and somewhat cyanosed until towards the close of the illness. The liver extended about three inches below the costal margin; it was smooth, and presented no other abnormal features. The spleen was not enlarged. The temperature was somewhat variable, but in the earlier stage was practically normal. Heart and lung sounds normal.

She was treated for some time with the usual antisyphilitic remedies, and the abdomen was frequently tapped—on the average about once a week,—during the nine and a half months she was

in the hospital. The fluid withdrawn was straw-coloured serum, and varied in quantity from 15 to 35 oz. The extreme varicosity of the veins over the front of the chest and abdomen, and the absence of any œdema of the legs, led to the diagnosis being entertained that there was obstruction of the inferior vena cava. The presence of ascites pointed to the obstruction being probably situated in the neighbourhood of the fossa on the posterior aspect of the liver, at the point of emergence of the hepatic veins. The *post-mortem* examination confirmed this view. Towards the end of the case the legs became œdematous, and concurrently the collateral venous circulation over the superficial parietes of the chest and abdomen became less prominent.

Post-mortem examination.—Some scattered patches of bronchopneumonia in both lungs, especially at right base, together with old pleuritic adhesions. Liver adherent to lower surface of diaphragm; surface smooth. Complete occlusion of inferior vena cava from the orifice in diaphragm to lower border of posterior aspect of liver. Microscopic sections of the liver, made by Dr. Sly, pathologist to the Evelina Hospital, show commencing cirrhosis of the liver.

November 5th, 1895.

---

27. *Loose body in a depression on the convex surface of the liver.* (*Card specimen.*)

By H. D. Rolleston, M.D.

Lying loose in a depression on the convex surface of the liver, and kept in place by old adhesions between the liver and the diaphragm, there is a small irregularly oval body. It is firm and hard, and gives somewhat the impression of being calcified. A small piece was cut off, and after being embedded in celloidin was cut into microscopic sections. It showed a firm fibrous capsule, enclosing structureless material—appearances which are compatible with the view that it is a necrosed lymphatic gland. It was not calcified. It appears probable that it was the remains of a chronically inflamed lymphatic gland which from wasting of the surrounding fat had become pedunculated and then detached. A pedunculated

caseous gland was shown before the Society by Dr. Walsham earlier in the session. Such loose bodies are not very rare. In 1890 I showed a larger, though otherwise similar, loose body before the Society ('Trans. Path. Soc.,' vol. xlii, p. 103).

When loose in the peritoneal cavity it must have wandered about until it passed between the convexity of the liver and the diaphragm. There local inflammation of the peritoneal covering of the liver gave rise to the adhesions which partially enclose it. As mentioned above, it lies in a smooth depression on the surface of the liver lined by the visceral peritoneum, and in this way, therefore, resembles a loose appendix epiploica which I described ('Trans. Path. Soc.,' vol. xlii, p. 160) as being fixed on the convexity of the liver. This relationship to the capsule of the liver shows that the encapsuled mass is not derived from the interior of that organ, but has been implanted on it from without. If it had been under the capsule it might perhaps from naked-eye examination have been thought to be an encapsuled mass of inspissated bile. Such intra-hepatic calculi are occasionally met with. *May 5th*, 1896.

---

28. *The relation of biliary calculi to malignant disease of the liver and gall-bladder.*

By Cecil F. Beadles.

There are many facts with regard to gall-stones on which much light has yet to be thrown. We know little as to their ætiology, and are at present ignorant why in only a certain number of subjects they make themselves manifest by symptoms. The origin of calculi is still wrapped in much mystery, and the exact cause of their formation remains surrounded with doubt. Although for years, I might say for centuries, they have attracted attention, we are now but little nearer an explanation. The theories advanced are indeed numerous, and many of these directly oppose one another. What others have failed to unravel I do not propose to attempt; we must await the result of the experimentalist for the artificial production of these bodies in the laboratory. My sole object is to touch on

the relation which gall-stones possibly bear to malignant disease of the liver—to briefly state my own view and ask the opinion of others.

But from the nature of the subject I am bound to refer to one of the supposed causes of biliary concretions, viz. that which suggests their origin from inspissation of the bile. A considerable number of writers believe that the concentration and decomposition of bile within the gall-bladder following upon obstruction to its outflow play an important part in the production of calculi, and that solid particles are first formed by the precipitation of certain ingredients in the hepatic secretion. The starting point is thought by some to be a catarrh or an inflammation of the gall-bladder, by which a plug of mucus is thrown down, whereon pigment and cholesterin are collected. Lately bacillary invasion has been proposed as leading to such a condition. A nucleus once formed, it is easy to understand the increase in size of a stone by the deposition of further material upon its surface.

That gall-stones are usually to be found co-existing with primary cancer of the liver or gall-bladder is clearly proved by autopsical examination. In fact the coexistence of these two conditions is so constant and so marked that writers have sought some explanation of its occurrence.

Two hypotheses have been put forward, both of which recognise cause and effect but are entirely contrary to each other; briefly they may be called the *irritation* and the *concentration* theories.

1. The irritation theory seeks to explain the origin of the malignant disease of the liver as a secondary condition, the result of an irritation set up by the pre-existing gall-stones.

2. The concentration theory represents the presence of gall-stones as due to the stagnation of the bile in the gall-bladder from pressure and obstruction of the ducts on account of the malignant disease in the organ.

From what one reads in our latest text-books and hears expressed, these two conflicting views appear to be held almost equally at the present time, for while some writers on the subject apparently believe that biliary calculi exercise an important influence in the pathogenesis of primary carcinoma of the liver, others lend but slight support to that view, or are strongly opposed to it.

Ranking amongst the foremost supporters of the first view is Frederick Taylor, who in his 'Medicine' writes in no hesitating

terms. He says that when gall-stones become impacted in the common duct, the death of the patient is "much more frequently due to the development of cancer about the gall-bladder or bile-ducts" than to any other cause;[1] and he also writes, "the chief features in the ætiology of cancer of the liver are its relations to the various primary lesions, and to gall-stone troubles of older date."[2] From these and other remarks he makes, it is clear that he looks upon gall-stones, which he specially says are very commonly found with cancer of the liver, as the exciting cause and not the result of the malignant disease.

Hilton Fagge and Pye-Smith[3] express with almost equal force a similar opinion, for they say, "the way in which death is most frequently brought about in persons who have gall-stones is by the development of cancer of the gall-bladder or the bile-ducts," referring at the same time to the frequency with which a definite history of such an event could be traced in patients at Guy's Hospital. These observers, however, do not by any means ignore the opinions of those who differ from them. With this view Murchison also holds, although, except for quoting instances, he makes but scanty reference to the fact, and seemingly brings but little personal experience to bear upon the subject. He observes that when the gall-bladder enlarges from cancerous deposit in its walls, "more commonly the disease commences in the gall-bladder, and the peritoneum or liver is affected secondarily. It is remarkable that in most of these cases the gall-bladder contains calculi, and the cancer appears to be the sequel of gall-stones."[4] Further, in distinguishing between jaundice from gall-stones and jaundice from cancer, he writes, "the difficulty is increased by the circumstance that cancer of the liver is a common sequel of gall-stones,"[5] which statement he apparently bases to a large extent upon the researches of Fagge, for he continues his remark by quoting from that physician.[6]

On the other hand, Bristowe and Frederick Roberts do not support this theory. The only reference the former makes to the

[1] 'A Manual of the Practice of Medicine,' 1890, p. 623.
[2] Ibid., p. 614.
[3] 'The Principles and Practice of Medicine,' 1888, vol. ii, p. 504.
[4] 'Diseases of the Liver,' 1885, p. 584.
[5] Ibid., p. 419.
[6] 'Guy's Hosp. Reports,' 1875, vol. xx.

coexistence of the two conditions would lead one to infer that he holds the concentration view, for he makes no reference to the liability of gall-stones to set up cancer of the wall of the gall-bladder or liver, and the only mention of the existence of the two is when, speaking of the causation of gall-stones, he says, "Concentration and stagnation of bile have doubtless some influence over the production of gall-stones, as is shown by their much more frequent formation in the gall-bladder than in the hepatic ducts, and probably also by their comparative frequency in cases of carcinoma and other organic diseases of the liver."[1] Roberts[2] merely notes that "gall-stones are usually present" with cancer of the gall-bladder, but does not suggest any explanation unless we take that where he classes with the predisposing causes of gall-stones, "organic disease of the liver, gall-bladder, or bile-ducts, interfering with the escape of bile." Thudichum throughout his "Treatise on Gall-stones" makes no mention of malignant disease in relation to gall-stones, and Austin Flint likewise does not call attention to the coexistence of the two conditions. In Quain's 'Dictionary of Medicine' we have the anomaly in different parts of the same work of two sets of writers expressing contrary opinions. While Wickham Legg and Stephen Mackenzie[3] under the heading of the "Ætiology of Gall-stones" suggest cancer as a cause, Stephen Ward and James Goodhart,[4] in writing of malignant disease of the liver, say that "some few, at any rate, have appeared to be the direct outcome of the local irritation of a gall-stone," pointing out at the same time that "of such as originate in the liver, the disease in the larger number commences in the gall-bladder or the bile-duct, and is of the nature of cylinder-celled cancer." As to gall-stones coexisting with other organic diseases of the liver, it is not found to any marked degree. Wickham Legg and Stephen Mackenzie specially mention, and this is also my own experience, that calculi are scarcely ever seen with marked cirrhosis of the liver. Ziegler[5] gives it as his opinion that hyperplasia and papillary outgrowths from the wall of the bile-ducts may follow prolonged chronic inflammation

[1] 'Theory and Practice of Medicine,' Bristowe, 1887, p. 806.
[2] 'Theory and Practice of Medicine,' Roberts, 1890, p. 726.
[3] Quain's 'Dictionary of Medicine,' 1894, vol. i, p. 716.
[4] Ibid., p. 1148.
[5] 'Text-book of Pathological Anatomy,' English edit., MacAlister, 1887, pt. ii, 349.

from calculi, and a fibrous overgrowth of the organ may result; but although he refers to the fact that many cancers of the liver start in the smaller bile-ducts, he makes no connection between the simple and malignant growths. Moreover, "adeno-carcinoma" at the orifice of the common bile-duct into the duodenum, he does not associate with biliary calculi.

Lastly, Osler in his recent work [1] notes that "the association of cancer of the bile-passages with calculi has long been recognised, and they are present in at least seven-eighths of all cases;" but this association he does not attempt to explain.

It is thus clear that there are still held two exactly opposite theories to explain the same phenomenon. It is not within my power to settle a disputed point of so great a magnitude; I can only give the result of my own small experience, and the conclusions that this has gradually forced on my own mind. This experience has been gained from the examination of specimens and the study of the reports of many cases of primary malignant disease of the liver in the Brompton Cancer Hospital, and at Colney Hatch Asylum.

Before I give my own experience, and state to which of the above views it is in favour, it seems to me essential that we should clearly distinguish between primary and secondary cancer of the liver and gall-bladder, and that we should separate entirely the second class of cases from the first. Now, this is not done as a rule, or if it is, it is not to a sufficient extent.

The text-books in general use fail almost invariably to point out the main differences between the anatomical appearances of primary malignant disease of the liver, and livers owing their condition to secondary affection. These are written of together in the same brief paragraph, and the primary disease is merely mentioned as being a less common variety. On the other hand, cancer of the gall-bladder and of the bile-ducts usually receives special notice, and is often placed under a distinct heading. Such remarks apply likewise to special works on diseases of the liver, such as that of Murchison. Now, this arrangement I believe to be a mistake. I would lay more stress on the distinction of primary and secondary disease of the organ, and class cancer of the gall-bladder and duct with the former.

Apart from the ætiological and histological point of view, when we take it solely from that of the anatomical we find, at least so far as my own experience goes, that primary cancer of the liver differs

[1] 'Principles and Practice of Medicine,' 1895, p. 487.

very markedly from secondary in its situation and naked-eye characters, so that being unaware of malignant disease elsewhere in the body we could rarely be led astray in venturing an opinion as to the origin of the disease in the liver.

While metastatic deposits are invariably scattered about the organ, varying much in number and size, and even at times leaving but little of the normal hepatic tissue visible, they are always of rounded form, and when many in number are distributed more or less uniformly, and not massed particularly about the fossa of the gall-bladder, or quadrate lobe. On the other hand, primary malignant disease forms a hard, uniform, scirrhous mass, if not involving at least close upon the superior wall of the gall-bladder. It affects the anterior region of the liver towards its free edge, where it usually involves its entire thickness. From this region it invades the organ backwards and outwards to the right and left, and spreading tongue-like prolongations of the growth extend beyond the general mass. Generally we have, in addition, secondary deposits of a rounded form scattered more or less throughout the remainder of the hepatic tissue. Sometimes the walls of the gall-bladder are involved in the growth, and on rarer occasions still there is an actual part of the neoplasm projecting into the cavity of that viscus, usually from the upper or hepatic wall. But most frequently the walls of the gall-bladder have more or less escaped disease, and the biliary passages are obliterated up to their very entrance into the bladder, the growth having all the appearance of being developed more or less close to the orifice of the duct, and spreading thence into the soft tissue formed by the liver cells.

All specimens of primary carcinoma of the liver which I have seen favour the view that the disease has started either in the wall of the gall-bladder or in that of the immediate ducts, and from thence affected the liver; while all cases of secondary affection of the organ have been distinctive in character, and in no way suggestive of such an origin.

The minute differences of microscopical structure of growths in the liver I consider of less importance, for in cases of undoubted primary cancer affecting the gall-bladder and surrounding liver substance we may have a typical glandular carcinoma undistinguishable from cancer of the breast, or we may have what is practically a duct carcinoma where columnar or cubical-celled lined spaces form the substance of the growth. This, which evidently

arises from the biliary passages, forms the most frequent variety of primary malignant disease, but it will often be found to be associated with the other form of cancer, into which it frequently tends to develop as it becomes more advanced.

Ziegler, in speaking of primary carcinoma of the liver, describes three forms—the nodose, the infiltrating, and those where small nodules are scattered along the portal vessels. He points out[1] that the epithelial cell-masses assume various forms, the nests or the glandular type, and that it is sometimes possible to make out an actual communication between the cell-nests (cancer alveoli) and the unaltered bile-ducts without any indication of a cylindrical-celled lining in the former.

Primary growths of the liver, I believe, are extremely few which do not arise from hyperplasia in the first instance of the epithelial cell elements of the wall of the gall-bladder or bile-ducts; at any rate, every specimen which I have examined has suggested this, and these are not limited to the cases now given. In the present paper, therefore, I refer to cases of cancer of the gall-bladder or bile-ducts as synonymous with carcinoma of the liver.

A fair number of primary growths of this region have come under my notice, but they are uncommon. I maintain that they are far rarer in proportion to cases of secondary infection of the organ than some of our best recognised works make out. The proportion given as one fourth of all the neoplasms of the liver is absurd, and has evidently been copied from one book to another, and is probably based solely on Frerichs' analysis of 90 cases; 10 per cent. would be much nearer the mark, but it is even less than this at the Cancer Hospital. If we limit ourselves to the restricted and popular meaning of the term "primary malignant disease of the liver," it would be considerably under 1 per cent.

Of the thirteen cases hereafter to be described, unfortunately in the majority few minute details are given, and in only five, those that I have myself seen, is there any statement as to the microscopical appearances of the growths. Even in these it is difficult to assign the point of origin of the neoplasm, a difficulty which will almost invariably be found with growths in the liver and about the neighbourhood of the gall-bladder. In four of these the growth presents the character of a cubical or columnar celled carcinoma, in the other it is spheroidal. These, and possibly all, arose either from

[1] Loc. cit., p. 341.

the wall of the gall-bladder or the larger bile-ducts in close proximity, although in Cases 5 and 6 the evidence is less clear. Cases 9 and 11, where no gall-stones were found, almost certainly took their origin from either the viscus or duct, notwithstanding the absence of information on their minute structure.

I have never seen a case of primary cancer of the liver taking the third form described by Ziegler, which is probably the same as the third variety described by Osler[1] as "cancer with cirrhosis." I once saw a remarkable liver which to the naked eye resembled Osler's description in all respects, and which an experienced pathologist pronounced as cancer; but on careful microscopical examination not a trace of malignant cells could be discovered, and the condition appeared to be produced by a pure cirrhosis. In one of the *post-mortems* which I performed at the Cancer Hospital, throughout the liver there were minute deposits of cancer along the portal vessels. The liver was not enlarged. The scirrhus-like growth either formed a hard ring round the veins, which here had their calibre greatly contracted or almost occluded, or else was arranged around in the form of minute scattered deposits no larger than a pin's head. The veins in other parts were dilated. Nowhere did these liver growths exceed the size of a pea. This occurred in a woman aged seventy-eight, who died with scirrhus of both breasts of an atrophic character which had only been recognised for five months, although it had probably existed much longer. The growth infiltrated the skin of the chest and the left pleura, but no other internal organ. Microscopically the growth was also unusual in that, in addition to the ordinary structure of mammary carcinoma, there were many large solitary cancer cells separated from one another by thin bands of stroma. There were no gall-stones, neither were they present in a couple of cases that I have seen where small cancerous deposits existed in the wall of the gall-bladder, associated with large masses in the liver and secondary to cancer of the breast.

Now with regard to the frequency with which the two conditions are found coexisting. In 100 consecutive *post-mortems* on persons who died from some form of malignant disease in the Cancer Hospital, thirty-six had deposits in the liver secondary to disease elsewhere, and four had what seemed to be undoubted primary disease of the liver. There is a slight doubt ventured in the case of the latter group, because, as will be seen afterwards, there were some

[1] Loc. cit.

remarkable facts connected with two of the cases. The one was a tumour of singular structure, and the other co-existed with another growth elsewhere; for my own part, however, I look upon them both as primary cancerous disease of this organ. All four of the liver growths were associated with calculi in the gall-bladder, whereas in not a single one of the thirty-six cases of secondary disease were any calculi found, nor were they present in any of the remainder of the 100 cases,

Apart from the relation of gall-stones to cancer of the liver, it has been suggested that malignant disease in the body predisposes to the formation of gall-stones. I can only say that these figures strongly oppose any such theory. The explanation given in Fagge's 'Medicine' is probably correct—that when the two conditions coexist "it may be merely a coincidence, for both cancer and gall-stones are apt to occur in persons advanced in years." In the thirty-six cases the liver was variously affected; in some there were only a few small nodules, and in five instances these were confined to the surface, but in the majority the growths were extensive and distributed throughout the organ, forming in many almost a mass of new formation, with but little intervening hepatic tissue. The site of the primary growths in these cases were—

Carc. breast	14
„ uterus	3
„ stomach	4
„ rectum	2
„ sigmoid flexure	1
„ peritoneum	2
„ pancreas	1
„ kidney	1
Sarcoma pelvis	1
„ pharynx	1
„ mediastinum	1
„ skull	1
„ skin (melanotic)	3
Malignant growth in cyst of broad ligament	1

To these might be added a liver with large deposits of actinomycosis which might equally cause obstruction to the free flow of bile.

At Colney Hatch Asylum many of the *post-mortem* notes are briefly and vaguely recorded, which sometimes makes it difficult to understand the writers' meaning. But scattered over these reports

from the early years of the Asylum to the present date I have been able to pick out what seem to be five cases of primary malignant disease of the liver amongst the males, and four amongst the females. Of these nine cases, gall-stones were absent or not recorded twice, once in a male and once in a female.

In a very large number of the autopsy reports the condition of the liver is not referred to, but the chances are very considerable that in the unrecorded cases the liver, if not normal, yet contained no form of malignant disease. In the livers of 1754 males where its condition is noted, secondary deposits existed in eight, and in 1206 females secondary deposits were present in nineteen. These were as follows:

Males (8).	
Malignant disease of stomach	2
" " œsophagus	1
" " pancreas	1
" " kidney	2
" " peritoneum	1
" " temporal bone	1
Females (19).	
Malignant disease of breast	2
" " uterus	4
" " ovary	1
" " stomach	2
" " colon	1
" " peritoneum	3
" " pancreas	1
" " supra-renal	1
" " mediastinum	2
" " cranial bone	1
" " arm-bone	1

In two out of these twenty-seven cases of secondary growths in the liver, gall-stones were found coexisting; both were females.

What I have placed here as a case of primary disease of the pancreas in a man, was in the autopsy book referred to as one of primary cancer of the liver, with secondary growths in the pancreas. This I venture to think is incorrect, as it would be quite phenomenal to have secondary deposits only in the pancreas to disease elsewhere, and after all many cases of primary disease of the pancreas that have spread to the liver are put down as primary diseases of the latter organ. The brief notes are—"11037 Male, aged 40, liver

which weighed 190 oz. presented well-marked signs of scirrhous carcinoma. The carcinomatous portions were very hard and difficult to cut with a knife. Pancreas also was infiltrated with cancer which was probably secondary. A large nodule pressing on the inferior vena cava was probably glandular."

With regard to the two female cases where gall-stones existed, one was an example of carcinoma of the peritoneum, and the liver contained a deposit only on its surface. The other placed under malignant disease of the pancreas was of doubtful primary origin, there being growths also in the cranial bones. The following is extracted from the notes. "10339 Female, aged 52. Behind the pancreas there was a hard cancerous deposit as large as half an orange. Secondary deposits throughout the liver varying in size from a pea to a walnut. Gall-bladder distended and full of a somewhat milky fluid and many calculi of cholesterin. Two soft tumours of doubtful character beneath the pericranium, one situated over the left parietal bone size of a walnut, the other on left frontal and smaller." It was suggested that these cranial growths were gummata.

Thus we have 13 cases of primary malignant disease of the liver or gall-bladder, in which only 2 were unaccompanied by gall-stones; whereas in 64 cases of secondary disease of the organ, gall-stones were only found twice. These two cases of primary disease above referred to I did not myself see, but we have no reason to doubt the non-existence of the stones. That such cases do at times occur is clear; cases have been shown quite recently at this Society by Drs. Voelcker, Rolleston, and Lee Dickinson, where primary carcinoma of the liver was unaccompanied by gall-stones. At the same time it must not be forgotten that gall-stones may have been overlooked, or that they may have been passed before death. In passing I may note that Dr. Rolleston also showed a case of papilloma of the bile-duct associated with an impacted gall-stone, and suggested the former was set up by irritation of the latter. Personally I have never come across a liver with a simple papillomatous growth in any part of the biliary passages, and cannot help thinking they must be exceedingly rare. The case of cancer of the gall-bladder which I give, where a pedunculated growth protrudes into the cavity of the viscus, possibly started as a simple papilloma.

Surely the above figures are not a mere matter of chance. I cannot help looking upon them myself as a strong argument in

favour of the irritative origin of cancer from the presence of calculi. Exceptions we have, but the fact that there are such exceptions rather favours the view that the malignant disease is the result of irritation, for it stands to reason that there are other irritative causes besides the presence of gall-stones that we can fall back upon; whereas if the gall-stones result from the stagnation of bile, this, one would think, must operate in many more cases where secondary growths exist.

If the presence of the gall-stones is dependent on the latter condition, surely we should expect to find a far larger, if not equally high percentage of cases where gall-stones coexist with cancer of the liver of secondary origin as with primary, But it is far from being so. According to my own experience, the difference is extreme; instead of finding gall-stones the rule, we find these bodies only on the rarest occasions, and in such specimens where it would seem that they bear no relation to one another, and their co-existence appears to be little more than an accident.

Again, why does primary cancer of the liver so often start from the gall-bladder or its immediate neighbourhood? For the same reason, surely, that malignant disease is most frequently found at orifices, because of the important influence that friction plays in its production. It is at the orifice of the duct into the gall-bladder that the gall-stones are liable to become impacted and give rise to irritative action. For my own part I further believe that, given a certain amount of irritation, malignant disease developing at what are called orifices is due to the fact that at these sites the epithelial covering changes its character. There is always a kind of transitional epithelium, which is frequently between columnar and squamous celled, and I am inclined to think that these cells which are less fixed in type are the most prone to take on malignant development.

We do not know how long it takes for gall-stones to be formed. It probably takes months or even years. We have no data by which to prove this point, but it is extremely probable that the larger cholesterin stones take far longer in their formation than does a malignant growth.

I have heard it suggested that if gall-stones set up cancer of the gall-bladder, the same argument ought to hold good with regard to calculi in the urinary bladder, and that we ought to find stone and growths of the bladder coexisting. Although this does occasionally

happen, there is no doubt that it is extremely exceptional. Where the growth exists it has probably arisen from irritation. This is scarcely, however, analogous. In the case of the gall-stones, the bile-ducts are completely obstructed, and the outlet to the bile and other secretions is abolished, whereas such an event does not occur in the urinary bladder, some operative interference being undertaken long before the calculi have entirely filled the bladder and obstructed all outflow of the urine, or kidney mischief with uræmia or suppression has already brought life to a close.

I venture to think that no one would now bring forward the old argument, that though gall-stones are common, cancer of the liver is rare, and that if calculi are a cause of the malignant disease, we ought to find the latter far more frequently. We might as well bring the same argument against epithelioma of the lip and tongue, for I believe that all are agreed that irritation from smoking plays a not unimportant part in the production of malignant disease in those parts. Notwithstanding the frequency of gall-stones, I should doubt whether they bear a greater proportion to the cases of primary malignant disease of the liver than do smokers to those persons who develop epithelioma of the lip or tongue as its consequence. Besides, there is another argument that might be brought forward. No one doubts but that gall-stones at times cause inflammation, ulceration, and perforation of the wall of the gall-bladder, yet in what a small percentage of persons who have gall-stones does such an event occur! We do not hear the expression used that inflammation ought invariably to be set up, and yet I scarcely think that inflammatory lesions resulting from gall-stones are so much more common than malignant disease of the gall-bladder, when we take into consideration the large number of persons in whom biliary calculi are found. In order to show the true significance of this argument I will digress for a moment and refer to the frequency with which gall-stones occur amongst the general population. Those whose knowledge is derived only from the result of general or hospital practice, whether from the clinical or the autopsical aspect, can form no idea as to the frequency with which gall-stones exist. The general practitioner, or the hospital physician, sees little more than those cases in which the stones have given rise to symptoms during life, for seldom are they found in the body after death of the ordinary hospital patient.[1] This may be due to the comparatively young

[1] In the discussion that followed this paper, Dr. Voelcker stated that in his

average age of such patients. I have already referred to the rarity with which they were found at the Cancer Hospital. But a very large number of people have gall-stones without ever experiencing any inconvenience from them. This is particularly brought into prominence by examining persons who die in our poor law infirmaries, and in lunatic asylums.

Amongst the very aged females who die in workhouse infirmaries, gall-stones are constantly found where no symptoms pointed to their existence during life. Mr. Dudley Cooper, as a result of several hundred autopsies, found them in from 10 to 12 per cent. of all women, and in about 1 per cent of the men.

Amongst the insane the percentages are far higher. The frequent presence of calculi in the gall-bladders of lunatics was generally known to alienists, but before I brought the matter before the Medico-Psychological Association [1] in 1892, I believe there were no published data bearing on the subject. I then gave as the result of fifty consecutive *post-mortems* on females dying in Colney Hatch Asylum, the extraordinary high percentage of 36 in which gall-stones were present. With increased numbers of cases the percentages have tended to sink somewhat, my first cases being considerably swelled by a large number of deaths amongst aged females from the influenza epidemic that was at the time prevalent. During the last three years the livers have been uniformly examined, from which I find that 27 per cent. of the females, and rather over 6 per cent. of males, have gall-stones.[2] The average age of these females was close on sixty-three, the youngest being twenty-five and the oldest ninety-

experience gall-stones were present in 10 per cent. of the patients dying in Middlesex Hospital. I do not think so high an average will be found universally the case for non-insane persons, at any rate in this country. Dr. Dodwell found them in 5 per cent. of the patients at the Brompton Consumption Hospital; at University College the medical cases give about the same result. Abram ('Liverpool Med.-Chir. Journ.,' July, 1893) gives only 4 per cent. for his post-mortems. Haller's classical number was just over 6 per cent. ('Opusc. Pathol.,' p. 77). Kelynack ('Practitioner,' April, 1896) gives 6·5 per cent. for persons dying in the Manchester Royal Infirmary (females alone 12·5 per cent.), but quotes Naunyn that gall-stones occur in 10 to 12 per cent. of all bodies examined. The latter says that post-mortem examinations show that they are present in 25 per cent. of all women over sixty years of age.

[1] 'Journ. Ment. Sci.,' July, 1892.

[2] This frequency is not confined to pauper lunatics, for Dr. Warnock found them in 50 per cent. of females and 11 per cent. of males dying in Peckham House Asylum ('Med. Times and Hosp. Gazette,' October 13th, 1894).

seven. The average age of the males was between fifty-nine and sixty. In only two cases have I seen concretions within the smaller bile passages of the liver substance; these were both females who also had calculi in the gall-bladder.

The causes of these remarkably high percentages in the insane female we cannot now stop to consider, but I have already discussed them briefly in the paper above referred to. The point is that not more than a couple out of the whole number of persons included in those figures had any symptoms during life referable to gall-stones. In three or four cases inflammatory lesions were discovered after death, but in the rest no morbid change had occurred, although the cavity of the gall-bladder was frequently entirely obliterated by calculi. In a number of instances the hepatic, cystic, or common bile-duct was completely occluded by a stone, which in some, judging from the clear colourless mucus in the bladder, had evidently been impacted for a considerable time, and yet had given rise to no symptoms pointing to biliary or hepatic disturbance.

As an example of hydrops vesicæ felleæ I show a greatly dilated gall-bladder, resulting from the lodgment of a gall-stone in the cystic duct. The viscus, over six inches in length, is distended with colourless watery fluid, its walls are thinned and translucent, and there were several calculi in its interior. The liver weighed 54 oz., and appeared healthy. It occurred in a female lunatic, 11757, aged thirty-six, who during life presented no symptoms of gall-stone disease; the patient had never been jaundiced, and never had an attack of colic. She died from carcinoma of the cervix uteri, recognised for four months, having been insane from mania with epilepsy for two and a half years; more recently in a state of dementia. There were no secondary growths of cancer in the liver or elsewhere.

The following are brief notes of the thirteen cases of primary malignant disease of the liver to which reference has been made. The first four are from the Brompton Cancer Hospital, and the remaining nine from Colney Hatch Asylum.

Case 1.—E. H—, a female, under the care of Mr. Jessett, aged 46, with no family history of cancer. Symptoms commenced two months before death, and rapidly developed. The liver was greatly enlarged, and weighed 109 oz.; it reached below the umbilicus, and was adherent to the abdominal parietes. The lowest part of the liver was a solid mass of new growth, particularly at the anterior

part of the right lobe. The upper and posterior part had secondary deposits throughout. The gall-bladder had growth in its wall, and was filled with dark mucus and numerous black and yellow gall-stones, several of which were of large size. No growths elsewhere in the body except for enlargement of the glands beneath the liver and about the head of the pancreas.

Microscopically the growth is a columnar-celled carcinoma. It presents long, cleft-like spaces lined by a single layer of cubical-shaped epithelium, which is modified in places to a flattened and compressed form, and in others assumes a more columnar shape. Parts of the growth contain slit-like masses of spheroidal cells as one sees in ordinary glandular carcinoma. Parts of the growth are necrotic, and there is some hæmorrhagic extravasation. The kidney also presented extensive blood effusion, especially into the glomeruli.

Case 2.—A. F—, a female, under the care of Dr. Purcell, aged 52. A cousin had cancer of the uterus. Symptoms known to have existed about one month.

Liver enlarged, nodulated, and hard, and extending nearly to the umbilicus. Gall-bladder adherent in its entire length to the liver, and surrounded by hard growth; it was full of calculi. The liver was studded throughout with secondary nodules. There were some enlarged soft glands.

Case 3.—B. F—, a female, under the care of Mr. Jessett, aged 37, with no family history of cancer. Six months before death some swelling over the liver region had been observed. Three months later a tumour showed itself on the side of the chest in the right axillary line, and spread rapidly forward. After another month jaundice occurred for the first time.

The liver, which presented the appearance of primary malignant disease, was greatly enlarged in both lobes, and weighed 98 oz. A large carcinomatous mass of growth, size of a Tangerine orange, was situated at the anterior margin of the right lobe close to the gall-bladder, and extended through from the upper to the lower surface. The remainder of liver contained numerous secondary deposits. The gall-bladder was not dilated, but contained small facetted calculi, ninety-eight in number; with the exception of one rather larger encysted stone they were of about half an inch diameter. Abdominal glands enlarged, but no deposits elsewhere, unless we look upon the chest growth in that light. This growth was at first solid, but

became cystic from the extravasation of blood and the breaking down of the tissue inside; it was firmly attached to the periosteum of the fourth rib, the rib itself being necrosed and broken. It was external to the mammary gland, and appeared to have originated beneath the fascia, and quite independently of the breast. Whether it was an entirely distinct primary malignant growth I hope to discuss on a future occasion in connection with other such growths.

Histologically the liver growth presents small, irregular, and slit-like spaces lined by columnar and pear-shaped cells, while others are entirely occupied by cells more spheroidal in shape. There can be no doubt that this growth is derived from the bile-ducts, and is a modified form of cylindrical-celled carcinoma. The growth from the chest wall resembles more or less closely that in the liver, but the alveolar spaces are rounder, and are packed with cells, which to a large extent are more spheroidal. The individual cells vary more in size, and some are large and swollen; where clustered together they are frequently much smaller.

Case 4.—This is the case of a remarkable tumour, of which the history is unfortunately wanting, and the *post-mortem* notes are scanty.

M. A. C—, a female, under the care of Mr. Elam, aged 45, was in the hospital about a week. History wanting. The abdomen distended, and the peritoneum everywhere thickened. A mass of growth the size of a cricket ball was situated in the neighbourhood of the gall-bladder, in which the pyloric end of the stomach was involved. The gall-bladder was dilated, and a stone was embedded in its posterior wall, the duct passing through the growth. The liver was small and very soft, its peritoneal covering being much thickened. Abdominal glands enlarged. The growth was gritty on section, and was seen filled with small stones. There was also a large mass of similar growth occupying the pelvic cavity. Right kidney small and adherent to liver.

Microscopically the tumour connected with the gall-bladder presented some very unusual characters. It had a capsule formed of thick dense fibrous tissue, in which a few minute microscopical calcareous particles were embedded, and from which bands of fibrous stroma spread inwards, these splitting up to form irregular alveolar spaces. Some of these were filled with epithelial cells, for the most

part of spheroidal shape, but in places they were lined by a layer of cubical cells. These had the appearance of carcinoma that had arisen from some portion of the biliary passages, the malignant nature of which was further shown by the presence of the other growths in the abdominal cavity. But the most interesting feature of the tumour was the fact that a very large proportion of the alveolar spaces were to a considerable extent or entirely filled by rounded masses of amorphous or homogeneous material resembling colloid in aspect, with a disappearance in part or wholly of the epithelial cells. Further, many of these rounded bodies showed a concentric arrangement of material around a central nucleus, and presented the exact appearance of calculi on section. They were, I believe, minute biliary calculi.

Dr. Mott, pathologist to the London County Asylums, has kindly looked at sections of the growth and expressed his opinion that the case is one of undoubted malignant disease arising in connection with the gall-bladder, that a colloid degeneration has probably taken place in a carcinoma, and that there has subsequently been a deposition of calcareous matter in the colloid material and so the production of calculi.

Case 5.—Male, 273, aged 60. Mania of twenty-five years' duration. Liver much enlarged and very heavy, and studded throughout with cancerous masses, especially the right lobe. The gall-duct was obliterated, and the bladder contained twenty angular calculi. Glands below liver infiltrated, and also those extending up the right side towards axilla.

Case 6.—Male, 4744, aged 62. Dementia following recurrent mania of over thirteen years' duration. Liver studded with round cancerous growths varying in size from a pea to an orange. Gall-bladder completely filled by a large stone. No growths elsewhere.

Case 7.—Male, 9468, aged 57. Melancholia of about four years' duration. Symptoms of liver disease for eight months. The liver weighed 68 oz. On the upper surface of the right lobe were several masses of growth of different sizes and of a light colour; left lobe unaffected. The omentum was adherent to the right lobe of the liver. The place of the gall-bladder was occupied by a cyst the walls of which were formed by the surrounding tissues, principally

peritoneum, and was filled with about 10 oz. of purulent fluid. The fossa thus formed was deeply excavated, and small nodules of growth of a white character were disseminated throughout. The duct was occupied by two calculi, and was completely obstructed. No growths elsewhere.

CASE 8.—Male, 10368, aged 69. Symptoms of mania with general paralysis of one and a half years' duration. No symptoms of liver disease. The liver was small and contracted, weighing 45¾ oz., and was in an advanced stage of cirrhosis and fatty degeneration. The gall-bladder, which was full of small stones, had ruptured, causing small hæmorrhage into abdominal cavity. There were several small masses of hard cancer involving its wall and causing it to be adherent to adjoining structures.

CASE 9.—Male, 10827, aged 43, mania with delusions and aural hallucinations for eleven years. Symptoms pointing to liver disease existed for about six months, but he evinced little inconvenience from it, and was not laid up until a fortnight before his death. Liver of enormous size, weighing 193½ oz. Mass of carcinoma in neighbourhood of gall-bladder, and the rest of the organ studded with large deposits. No gall-stones found. No growths elsewhere in body.

CASE 10.—Female, 4996, aged 61, the subject of recurrent melancholia for twenty years; suicidal with delusions of poisoning. Symptoms of liver disease for about six weeks.

Liver studded throughout with scirrhous growths, most marked near the gall-bladder. The bile-ducts were enormously dilated, especially about the central portion of the organ. The gall-bladder was completely occupied with calculi, two large, and the shape of a thimble with many smaller. The cystic and common bile-ducts completely occluded.

CASE 11.—Female, 9591, aged 51, the subject of recurrent melancholia of five years' duration; restless, apathetic, refused food and to speak. Liver much enlarged, weight 80 oz. Upper surface covered by recent lymph and adherent to adjacent viscera. On section it showed deposits of new growth varying in size from ⅙ inch to 2½ inches in diameter. Gritty on section, white externally, and yellowish in the middle, while whole of centre was a sanguineous core. Gall-bladder small, contained bile, but no mention of stones. There was

a nodule of new growth occupying the place of one of the bronchial glands on the right side, and the uterus contained several "fibroids."

CASE 12.—This bears a close resemblance to one I referred to as occurring at the Cancer Hospital (Case 3), where two separate growths existed, the one in the liver and the other one connected with the thoracic wall.

Female, 5528, aged 61. Mania for close on twenty years; restless, suspicious, deluded, incoherent, and at times noisy, violent, and destructive. No liver symptoms at any time. Tumour at side of chest first noted about four months before death. As I propose to show this specimen on a future occasion in connection with another subject, I shall now confine myself principally to the liver specimen.

Tumour larger than an orange in right upper pectoral region, firmly attached to the ribs, encapsuled with skin freely moveable over it. To the naked eye it looked like a sarcoma, but microscopically seems to be of the nature of a glandular carcinoma, not unlike that in the liver. It did not appear to be associated with the breast. No enlarged glands in axilla.

Liver enlarged, and the seat of malignant disease which has all the characteristic appearances of a primary neoplasm of that organ. The anterior part of the right lobe and neighbourhood of the gall-bladder is a solid mass of hard cancerous growth. The surface nodulated, and the section showing a uniform area of scirrhus-like tissue. Through the rest of the organ are large rounded deposits. On opening the gall-bladder, which was enlarged, there was seen a mass of protruding growth from its upper wall, such as is never seen in secondary infection of the organ, but which is often to be found with cancer starting in the wall of the gall-bladder. The ducts were obstructed, and there was present a cholesterin stone the size of a pigeon's egg, together with a smaller one. No deposits elsewhere.

Microscopically the liver growth has the character of spheroidal-celled carcinoma. For the most part the alveolar masses are of large size, the cells uniform in size and shape, and no marked evidence of any duct formation. There is, however, a peculiar appearance presented in places by large swollen cells, having an aspect assigned to the so-called parasite to which they would probably be referred by those who hold to that view. Where several of these are clustered together they compress the outer cells, and give rise to an appearance not unlike ill-formed pearls of

squamous epithelium. The free edge of the growth is in a state of necrosis.

The growth from the chest is not quite similar to that in the liver. The alveolar masses are of larger size; the stroma more marked. The epithelial cells have even more the appearance of squamous epithelium, and cell-nest formation seems even more to be assumed. This is especially noticeable in some of the extensive areas which take the stain but feebly, and are undergoing necrotic change. Could both these growths have arisen from the surface epithelium of the gall-bladder?

CASE 13.—As a rule, cancer of the gall-bladder appears to arise without any recognisable previous inflammation. Throughout the body we generally find that hyperplasia of the tissues resulting from irritation more often than not is unpreceded by inflammatory signs, but this is by no means universally the case.

The following, which is an early case of carcinoma, brings my cases to an end. It is accompanied by the specimen, and shows, I believe, the sequence of events as to the part that gall-stones may play in first producing inflammation of the wall of the gall-bladder, to be succeeded by the development of malignant disease.

Female, 11,874, aged 56. Mania of sixteen months' duration with delusions of persecution and mesmerism, and hallucinations. Symptoms of liver disease for two months, which were jaundice, emaciation, occasional attacks of colic, tenderness over the liver, afterwards increased dulness over right side of the organ, with constant sickness. She acquired a delusion that a rat and snake were in her inside. Had constant sickness and diarrhœa and became comatose.

The liver was smaller than natural, ill-formed, and flattened out like a pancake. There was an extra lobule at the posterior border of the left lobe, and the lobulus Spigelii hung down considerably. It was very adherent to the diaphragm superiorly over a wide area between its lobes and posteriorly, and to the transverse colon immediately above the gall-bladder, where the organ was shrunken and presented a large fibrous cicatrix. On section it presented a dark colour, though markedly fatty in places, especially anteriorly. Throughout, the bile-ducts were dilated, and had very thickened fibrous walls. There were no growths about the liver (Fig. 5).

On cutting into the contracted gall-bladder, its walls were found

greatly thickened, from half to an inch or more, with firm fibrous-like tissue which spread into the surrounding darkly-coloured hepatic substance in the form of irregular bands of a yellowish tint. This new growth had more the appearance of chronic inflammatory tissue than of malignant disease. The inner surface of the gall-bladder was irregular, and the lining membrane had entirely disappeared. Numerous calculi lay embedded in it, and entirely filled the space with a small amount of pus-like fluid. The stones consisted of two larger ones the size of marbles, and over twenty smaller ones not larger than orange pips, composed mostly of cholesterin. Some of the bile-ducts were enormously dilated in the vicinity, and opened directly into the cavity of the gall-bladder.

Pancreas of normal size and form, but stood out prominently owing to its uniform hardening; it was evidently extremely fibrotic throughout, but there was no sign of general or localised growth. The lymphatic glands below the liver and in the neighbourhood of the pancreas were firm, and tinted yellow, and greatly increased in size, from an almond to a small walnut. Under the microscope this was seen to be due to chronic inflammation, the greater portion being necrosed, and no malignant cells were discovered in any of the glands examined.

The stomach was dilated, its mucous membrane dark, but with no new growth, and there were no deposits elsewhere in the body. No peritonitis, old or recent, beyond the adhesions already referred to.

Before death it was suggested that this patient had malignant disease of the pancreas. Such a view, however, was entirely negatived by the result of the autopsy, but it was not at first by any means clear that malignant disease existed at all.

I think that most persons seeing the liver, at least in the fresh state, would have been, as I was, more in favour of an ulcerative and chronic inflammatory condition set up by the presence of gall-stones (Fig. 5).

On examining histologically sections from the dense tissue around the gall-bladder, the case became clear as one of malignant disease starting in the wall of that viscus. There are definite epithelial cell masses, embedded in a dense fibrous stroma. These cell masses in places are identical in form and character to those found in primary cancer, starting from the bile-ducts, cleft-like spaces lined by cubical and columnar cells, but to a large extent there appears to be simply an increased cell proliferation of the lining of the ducts

of a non-malignant aspect such as is found in hypertrophic cirrhosis of the liver, where the proliferation is more of the nature of an

FIG. 5.

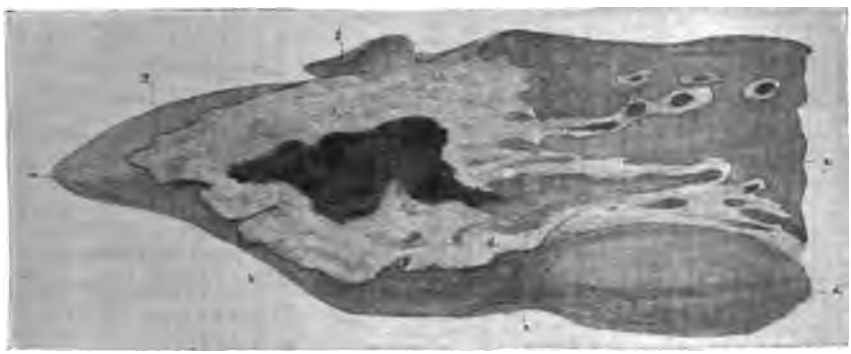

The specimen represented in the above figure is from Case 13. The liver has been divided by an antero-posterior vertical incision carried through the centre of the cavity of the gall-bladder, and the right side viewed. *a*. Exterior of anterior edge of right lobe. *b*. Cavity that contained gall-stones surrounded by a thick wall of inflammatory and cancerous growth. *c*. Interior of a dilated bile-duct opening into the cavity. *d*. Under surface of lobus Spigelii. *e*. Cut surface of liver showing dilated bile-ducts with thickened walls. *f*. Transverse colon adherent to upper surface of liver. *g*. Peritoneum adherent to free end of the growth.

adenomatous growth. This is marked at the advancing edge. A very large amount of fibrous stroma exists which, in the more distant parts of the growth, as it passes in amongst the hepatic cells, is of a younger and more embryonic type.

That there is actual inflammation occurring at the same time is clear from the amount of round-celled infiltration present in many places. This is marked in the neighbourhood of the branches of the portal vein and in the region where the hepatic cells are being advanced upon; here the liver cells are disintegrating and markedly pigmented. But inflammation is apparent also at the ragged edge of the new tissue, where it forms the wall of the cavity containing the gall-stones; there is extensive leucocytic infiltration combined with necrosis of the fibrous matrix, evidently set up by the suppuration that has occurred.

As already noted, the enlarged glands from the abdomen appear only to be chronically inflamed, the result, I should say, of the suppuration that has been taking place.

If I may venture an opinion as to the course of events in this case, I would suggest that the gall-stones are at the root of all the mischief. The irritation of the stones in the bladder has first set up an inflammation and ulceration of its wall. We have evidence that this inflammation has been very intense, as is seen by the state of the interior of the viscus, the scarring on the surface of the liver and the adhesions contracted to surrounding organs. This irritation, not being relieved by the more usual method in such cases of expulsion of the offending calculi by perforation into the bowel, has been prolonged and given rise to the local hyperplasia of the neighbouring tissues which has rapidly developed into malignant disease.

Even amongst the most advanced believers in a cancer parasite, there are, I believe, many who recognise that irritation forms an important predisposing agency in the production of the disease, by preparing the soil and so allowing a footing for the new growth, and that in many, if not all instances of malignant disease some source of irritation may be readily found. The malignant disease here is evidently still in an early stage of its existence. Whether or not an extraneous organism has gained access to the damaged site and there found a suitable spot for its development, I must leave to be discussed by the upholders of the parasitic origin of cancer.

Addendum.—Drs. Rolleston[1] and Kelynack[2] have lately written on allied subjects. The former, in his interesting paper, attempts to separate cancer of the bile-ducts entirely from cancer of the gall-bladder. But this to my mind seems not only useless but practically impossible. Surely we should regard the bladder as little more than a distended portion of the ducts, both in its anatomical and histological relations, and also in its development. He states definitely that cancer of the former may take the histological form of either cylindrical cells or of spheroidal cells, whereas he suggests that cancer of the bile-ducts is always of the cylindrical-celled form, which statement, however, is not supported by all the writers to whom he refers. I fail to see how, after acknowledging the existence of the two types of growth from the wall of the gall-bladder, he could make it a point of differential diagnosis, that given a growth in the liver, if it had a

[1] "Primary Carcinoma of the larger Bile-ducts," 'Medical Chronicle,' January, 1896.

[2] "The Relation of Gall-stones to Primary Cancer of the Gall-bladder," 'Practitioner,' April, 1896.

cylindrical-celled structure it arose from the bile-ducts, if a spheroidal-celled structure it spread from disease that originated in the head of the pancreas.

Dr. Rolleston strongly supports the irritation theory of the association of gall-stones with malignant disease of the gall-bladder. He refers to the proportion given by Musser as 69 per cent., but in the separated cases of cancer of the bile-ducts this is reduced to about half per cent. In the eleven cases collected by himself, there were only four with gall-stones. These figures, he thinks, favour the view that gall-stones are a predisposing cause of the cancer. This view Dr. Kelynack also holds. Gall-stones were present in all our of his own recent cases of primary malignant disease of the gall-bladder, and he gives the percentages found by Courvoisier, Musser, Ames, and Siegert in their collected cases, viz. 91, 92, 95·4, and 95 per cent. respectively. Commenting on the three views, irritation hypothesis, concentration hypothesis, accidental association, he dismisses the last at once as untenable in the light of these statistics, and in his final summary he remarks: "The presence of gall-stones in certain subjects, and doubtless in connection with other predisposing conditions, favours a cancerous development."

A point I have referred to is commented on by both these writers, viz. the objection that might be raised from analogy with regard to the rarity of malignant disease with renal and vesical calculi. Kelynack thinks that the local conditions of tissue must ever play an important part in cancerous growth, and that "the somewhat rudimentary character of the glands of the gall-bladder may possibly specially predispose the tissue elements in this situation to respond to a comparatively slight irritation by indefinite atypical growth." Rolleston makes the suggestion that possibly there is a special resistance offered by the urinary tract to the development of malignant diseases of all kinds.

With regard to the proportion in the sexes, my cases do not show a great preponderance of one over the other, there being three more females than men in a total of thirteen cases. The average age was just under fifty-four. The greater liability of females to primary cancer of the gall-bladder seems to be generally recognised. According to Kelynack, Courvoisier and Ames both found them in the proportion of four to one, and Musser gives three to one. Osler says that women are attacked less frequently than men by cancer of

the liver. Rolleston believes that in the limited cases of growth arising from the larger bile-ducts (not including those of the gall-bladder), the cases are equally distributed in the two sexes, and quotes Musser to that effect.

This question is interesting in connection with the greater liability of females to gall-stone disease. Osler gives three-fourths of the cases as occurring in women; Kelynack rather over double, and quotes Schröder that women are subject to them five times oftener than men. My own numbers come to a very similar proportion. References to other observers are given in my paper on gall-stones in the insane.

Finally, I might mention that even were it possible to diagnose during life in an ordinary individual between malignant disease of the larger bile-ducts and cancer of neighbouring structures, all such points as those given by Dr. Rolleston are apt to fail us in the case of persons who are insane, in whom, when we discover some gross abnormality, we are often obliged to leave the exact diagnosis in doubt. The way in which not only subjective symptoms are masked or entirely wanting but even the physical signs of many morbid lesions in insane persons is most extraordinary. *November 5th,* 1895.

---

29. *Gall-stone impacted in the small intestine; removal by laparotomy.*

By J. Hutchinson, jun.

The calculus is, as usual, extremely light for its size; it is on the whole rounded, but with a tendency to the octahedral form, and measures 9·5 centimetres, or 3¾ inches, in circumference, 2·5 centimetres in its shortest and 3 centimetres in its ongest diameter. It weighs only 121 grains. The symptoms of the case from which it was obtained were unusually definite, so that a positive diagnosis was made by my colleague, Dr. F. J. Smith, and by myself before the abdomen was opened. The patient was a woman aged sixty-nine, who gave the history of previous jaundice and very severe hepatic colic, the latter no doubt attending the passage of the stone by ulceration from the gall-bladder into the duodenum. Acute intestinal obstruction with excessive pain

(perhaps aggravated by the administration of aperients) had lasted for three days. The operation was of the simplest nature, for on opening the abdomen I at once came upon the loop of small intestine that was plugged by the stone and drew it out of the wound. The intestine above was much distended and inflamed, the part below so firmly contracted as to resemble that of a rabbit. It is well known that impaction usually takes place near the ileo-cæcal valve, but in this case I clearly ascertained that many feet of ileum intervened between the stone and the cæcum. It was impossible without using dangerous force to push the stone on, so an incision was made in the free border of the intestine just large enough to allow the extraction of the stone. The after-history of the case was so interesting that I propose to publish it elsewhere, and it will suffice to say that after she had rallied she became dangerously ill on the third day and was fully expected to die. She has, however, made an excellent recovery. Whether some peritonitis occurred around the inflamed intestine or the small longitudinal wound (which had been secured with a continuous silk suture in the mucous layer and interrupted Lembert's sutures in the other coats), or whether her illness was due to the effects of starvation and long-continued vomiting and pain before the operation, I cannot say.

From the pathological point of view one is struck by the small size of a stone which caused complete (and what would, I firmly believe, have been fatal) obstruction. It is only a little over an inch in its long diameter, and is practically the same size as the Murphy's button used for intestinal resection of the small gut. That the button alluded to may also cause fatal obstruction when it becomes free has unfortunately been proved in several cases, a fact foretold by Chaput in some interesting experiments on the dead subject. He found that Murphy's button (the size used for the small intestine) either passed along the lower end of the ileum with extreme difficulty or could not be forced through into the cæcum in some instances. Of course, it may be said that living intestine is more expansile than dead, but this is very doubtful. Another fact of interest is the seat of obstruction, it being exceptional for impaction of a gall-stone to occur elsewhere than in the lower end of the ileum near the ileo-cæcal valve.

It is erroneously supposed that cases of fatal gall-stone impaction in the intestine are rarely if ever met with. In a short search into the literature of the subject I found records of at

least thirty cases. Dr. Murchison apparently collected notes of twenty. Three unpublished cases of acute obstruction from gall-stone impaction have occurred within my knowledge in the last two or three years, beside the one now reported. In one, death occurred without operation; in the other two (both operated on by my colleagues at the London Hospital), one recovered and one died. In M. Sajous' 'Annual' for 1893 (vol. iii, c, 56) the extraordinary statement is made that M. Baudoin had seen twenty-seven cases of intestinal obstruction from calculi. It should no doubt read that he had collected records of them. In twenty-one, enterotomy and enterorrhaphy were performed, with six recoveries; six were left to nature's efforts, with only one recovery.

The late Dr. Hilton Fagge reported ('Trans. Path. Soc.,' vol. xix, p. 254) two cases in which large calculi caused obstruction, but were ultimately voided *per anum*, and in commenting on them remarks, "if one may judge from the published records of such cases, it is far less common for calculi so large as these specimens to be passed during life than for them to be found within the intestine after having caused fatal mechanical obstruction." It is true that the stones in Dr. Fagge's cases were much heavier (400 and 353 grains respectively) and larger (2 inches and 2¼ inches) than in my case. But the really important measurement is the diameter which is placed across the intestine, and this in both his cases was practically identical with that of the stone now exhibited (*i. e.* just over one inch).

I may venture to express a hope that early surgical intervention will render specimens of gall-stone impaction in the *post-mortem* room still rarer than they are at the present time. The danger of the operation and the possibility of natural cure must, however, be clearly borne in mind, and have been emphasised in the strongest manner by my father in his 'Archives of Surgery.'

December 3rd, 1895.

---

30. *Acute tuberculosis of spleen; splenectomy; recovery.*

By C. H. Marriott (per J. H. Targett, M.S.).

History of case.—From a married woman, aged 32, who was admitted to a hospital for a large abdominal tumour, which was first noticed two years previously. The patient had had one

child about three years previously, and no miscarriages; there were no signs of syphilis, and her husband had never suffered from any venereal complaint. She had, however, been troubled with ulceration of the vulva on two occasions during the last eighteen months, but this got quite well with simple remedies. The abdominal tumour caused little or no pain; it steadily enlarged at first, then the increase in size became much more rapid. As the diagnosis was doubtful an exploratory abdominal section was performed by Mr. Marriott, and an enlarged spleen was removed (January 22nd, 1895).

The blood was examined at the time of the operation and was found to be healthy, but the corpuscles were not counted. There were no enlarged glands in the neck, axillæ, or groins, and there was no history of such enlargement in the past. No definite physical signs of leucocythæmia beyond the condition of the spleen; the patient said that when she had cut her finger the bleeding was never excessive.

On the third and fourth days after the operation some hæmorrhage, to the amount of an ounce or so, took place from one of the suture holes. A second suture was inserted near this spot to draw the edges of the wound closer together. On the eleventh day the sutures were removed, when another of the openings bled more than usual, but the hæmorrhage was soon stopped. In all other respects the patient made an excellent recovery. Before she left the hospital convalescent from the splenectomy a chronic ulcer of the vulva was excised, but unfortunately this tissue was not examined microscopically. As stated above, the inguinal glands were not enlarged.

Eighteen months after the operation she was in perfect health with a rosy complexion, and there had been no recurrence of the ulceration of the vulva.

Description of specimen.—The spleen is uniformly enlarged, measuring eight inches in length, five inches from side to side, and three inches in thickness. The natural outline of the organ is preserved, and the impressions of the adjacent viscera on its surface are well seen. There are two notches on the anterior border, but neither of them is very distinct. The serous coat is smooth throughout, save for a few tags in front. The convex aspect of the spleen closely resembles a hobnailed liver, being studded with coarse rounded nodules which project slightly beyond the general level of the peritoneum. In appearance the cut surface of the

specimen is like that of its convexity, for the splenic pulp is stuffed with yellowish-white, slightly raised deposits in all parts of the section.

Microscopical examination reveals the presence of numerous grey tubercles, clustered for the most part, thus explaining the nodules above described. There is very little caseation, and the most striking feature of the tubercles is the large size of the so-called epithelioid cells which surround the central giant cell.

The chronic ulcer of the vulva would seem to have been the source of infection in this case, and it is remarkable that up to the present time there is no clinical evidence that any other organ than the spleen has become infected.

The specimen is preserved in the Museum of the Royal College of Surgeons. *November 19th*, 1895.

---

31. *Hæmorrhage near pancreas with fat necrosis.* (*Card specimen.*)

By Cyril Ogle, M.B.

A layer of blood, about half an inch thick, is seen behind the peritoneum, extending from the pancreas to the brim of the pelvis, and laterally to the outer borders of the kidneys. Both the mesocolon and the mesentery were infiltrated with blood; the adrenals and the solar plexus were buried in it.

There was no blood in front of the pancreas, but this organ, whilst retaining its shape, looked like a mass of cream cheese. The cavity of the small omentum in front of the pancreas contained a milky fluid to the amount of several ounces, and there was lymph on the posterior surface of the stomach. There was, however, no sign of inflammation in the larger sac of the peritoneum, but situated on the mesentery, chiefly upon the left side, were opaque white streaks and patches of fat necrosis. This condition was not seen as regards the fat of the great omentum or that of any other part. Beneath the microscope the fat cells in the necrosed spots were opaque, with granular débris and fine crystals.

On section of the pancreas the lobules were pale but well defined,

and between them was an opaque white material, which proved microscopically to consist of slender crystals and finely granular matter, lying either free or arranged in rounded groups, each group with a thick border of fine crystals—a condition seen in the fat necrosis of the mesentery. There was no blood between the lobules, and very slight evidence of any acute infiltration of cells; the nuclei of the pancreatic cells stained well. The pancreatic duct was normal; there were no gall-stones in the bile channels. The heart weighed 13 oz., and was healthy except for a few petechial hæmorrhages on its back. The source of the hæmorrhage could not be found. The arteries in the body were everywhere remarkably healthy as far as could be ascertained.

History.—The man, aged 31, was fat and addicted to beer. The symptoms were acute, and marked by abdominal pain, vomiting, and moderate distension and tenderness, with failure of the pulse, and death within seventy-two hours. There was no history of any injury to the abdomen.

As the source of the hæmorrhage could not be found, and as the evidence of any acute inflammation of the pancreas was very doubtful, the case may be classed with those described by Professor Fitz,[1] of unexplained hæmorrhage in the neighbourhood of the pancreas associated with fat necrosis, and rapid death by collapse.

A similar example, with, however, a history of former injury to the abdomen, was described by Dr. Rolleston in the 'Trans. Path. Soc.' of 1893.

It is possible, considering the habits of the man, that in the case now described there may have been an injury to the abdomen by a blow or fall subsequently forgotten. In favour of such a view is the fact that the blood had a chocolate colour, as if not very recently effused; the layer of it was also thicker in the lower part of the abdomen, as if it had been gradually effused, and thus, perhaps, it had not pressed upon the solar plexus until a considerable time after it had begun to infiltrate the tissues behind the peritoneum.

The chief interest of these cases appears to be their similarity in point of symptoms to those of perforative peritonitis.

March 3rd, 1896.

[1] Middleton-Goldsmith Lecture, 1889.

32. *A specimen illustrating a rare method of formation of intra-abdominal bands.*

By J. Hutchinson, jun.

The main facts as to the causation of intra-abdominal bands, and the extremely important part they play in acute intestinal obstruction are now generally known, but there still exist several doubtful points in connection with the subject. Leaving out of consideration the so-called internal hernia of intestine into pouches such as the fossa duodeno-jejunalis, the ileo-cæcal fossæ, &c., and through apertures in the mesentery, a convenient division of intra-abdominal bands would be into: 1. Those due to adhesions in connection with persistent fœtal and allied structures, *e. g.* the vermiform appendix, Meckel's diverticulum, and the omphalo-mesenteric vessels. 2. Those of new inflammatory formation, or in other words, due to localised peritonitis. 3. A third, though comparatively small class, might be formed of cases of band due to adhesion to the parietes, &c., of normal structures such as the great omentum or the appendices epiploicæ—cases in which there is, as a rule, no evidence of inflammation to account for such adhesion. The specimen shown is a remarkable example of an insignificant structure, one of the hydatids of Morgagni in the female, becoming adherent to the great omentum, and in course of time becoming elongated and hypertrophied so as to form a band many inches in length and of sufficient strength to have caused strangulation of intestine. It was obtained in the dissecting room of the London Hospital from an elderly subject. On opening the abdomen a long tough cord was found attached to the right broad ligament below and to the great omentum above, measuring at least six inches in length. There was no trace of old inflammation about the uterine appendages on either side and no evidence of peritonitis elsewhere. It was at first very difficult to account for this band, which had the consistence of stout catgut. Its true nature, however, was revealed by a careful examination of its upper end, where it ended in a small saccular body, exactly recalling the small cysts known as hydatids of Morgagni. These, it is well known, are somewhat variable in number, position, and the length of their pedicles. Anything approaching to the length in the present instance, however, I have never seen or read of. That this is the

origin of the band can, however, be doubted by no one who examines the specimen (which is in the London Hospital museum). The power of the intestinal movements in moulding and dragging out bands of lymph, &c., is extraordinary, and in this case one must consider the excursions of the great omentum as having had a similar effect upon the pedicle of the Morgagnian hydatid. In this connection I may mention a remarkable instance of displacement of the great omentum which also came under notice in the dissecting room. On opening the abdomen the liver was found to be completely concealed by the omental apron which turned upwards from the transverse colon, and was firmly adherent by its normal lower edge to the diaphragm, thus shutting off the entire hepatic region. There was no marked evidence of peritonitis, and the case is of interest as proving the strange alterations in position which the great omentum may sometimes undergo. Dr. Perry showed a few years ago at the Pathological Society two specimens of band causing fatal intestinal obstruction due to as strange a cause as the hydatid of Morgagni, namely, the appendices epiploicæ attached to the large intestine.

December 3rd, 1895.

---

33. *Calculi of calcium oxalate from a cyst of the pancreas.*

By Samuel G. Shattock.

In January, 1895, a woman was operated upon for an abdominal cyst by Mr. Bernard Pitts, to whom I am indebted for the opportunity of recording the pathological aspect of the case. The cyst itself contained a certain number of small calculi of oxalate of lime, and as the interest attaching to these rests essentially upon the cyst in question being pancreatic, it is necessary in the first place to criticise as closely as possible the evidence on which this is based.

In St. Thomas's Hospital Museum there is a kidney (No. 2090) in which are several cysts containing smooth, deeply-coloured calculi of oxalate of lime. The possibility of the cyst under consideration being of renal origin, therefore, is one that needs disposing of.

Again, calculi of the same composition, though not yet observed,

so far as I know, in the human intestinal canal, are not rare in that of herbivora, and might very well form in strict vegetarians; hence the possibility of the cyst having been, say, an intestinal diverticulum or pouch has also to be met. Apart from Meckel's diverticulum, sacculi (enteroceles they might be named, were not the term already in use for a hernial sac holding gut) are at times encountered along the intestine, and might under circumstances become closed off as cysts. I have described such sacculi in a preceding volume of this Society's 'Transactions' (vol. xxxiii, p. 192).

The large size of the cyst and the fact that it contained fluid with nothing of the nature of intestinal contents, and was quite free of the intestine, negative this hypothesis.

During the last three years two other pancreatic cysts have been successfully removed at St. Thomas's Hospital.

The *first* was a thin-walled sac (Mr. H. H. Clutton, November, 1892) found to have no connection with the kidney or pelvic organs and situated behind the great omentum between the stomach and transverse colon. When the cyst was lifted out through the abdominal wound it brought with it the tail of the pancreas, with which alone it was connected, and from which it could not be removed without dividing some of the gland. A large amount of fluid escaped for some days by the glass drainage-tube which it was necessary to insert into the wound; this fluid readily converted starch into sugar, and digested fibrin. The contents of the cyst, however, did neither, nor did they emulsify fat; they were highly albuminous, and turbid with cholesterin. Nevertheless, from its intimate connection with the pancreas, the cyst may be held to have been a retention one of that organ, the contents having undergone secondary changes like the fluid of a long-standing hydronephrosis.

The *second case*, under the care of Mr. Pitts, is thus briefly recorded in the statistical report of the hospital. Female, aged 35, enlargement of abdomen five years; no history of abdominal injury; large prominent globular tumour of abdomen, most of which is situated above the umbilicus. Fluctuation obtainable. Band of resonance between tumour and symphysis. Tumour apparently not connected with pelvis. Cœliotomy. Tumour covered by peritoneum. Transverse colon closely connected with cyst. Peritoneum incised; cyst partially shelled out. Tissue of pancreas found spread out over a small portion of its wall, and inseparable from cyst. Redundant portion of cyst wall cut off and remainder stitched

to abdominal wall. Good deal of discharge from pedicle; mostly greenish fluid. Left hospital on sixty-sixth day.

The case considered in this communication was that of a woman admitted under Mr. Pitts, January 18th, 1895. In the June preceding she felt an acute burning pain in the left inguinal region, which shifted to the left hypochondrium and upper part of the lumbar region. A swelling was first noticed about the same time, and this has increased. There was no dysuria, and no vomiting or emaciation.

State on admission.—A fairly well nourished woman complaining of abdominal swelling and pain. The abdomen bulges in its lower half. The swelling is globular and lies below the umbilicus, almost centrally but with a slight inclination to the left. Abdominal section revealed a thin-walled cyst. The mesentery, which passed in front, was separated from it and the cyst tapped, 31 oz. of clear fluid being withdrawn. The attachment of the sac was then made out; it appeared to run upwards, and was found springing from the pancreas. When the opening in the cyst was enlarged it was discovered to be multilocular, and in one of the compartments were some minute round grains like fish roe, and one larger bean-shaped concretion. The cyst was not removed, but sutured to the abdominal wound; after the greater portion had been cut away, a glass drainage-tube was inserted. Examination of the fluid by Dr. Gregor Brodie showed it to be faintly but distinctly acid, sp. gr. 1020; fair trace of albumen, no sugar; it converted starch into sugar.

The calculi.—The chief of these was of flattened oval form, deep reddish brown in colour, quite smooth, and in chief diameters 4 by 5 mm. The others, seven or so in number, were spherical, similarly coloured, of almost uniform size, the smallest ·5 mm. in diameter.

Of the largest, after removing part for chemical examination, I made a microscopic grinding, taking great care that the section included the centre.

Microscopic structure.—The body of the calculus consists of transparent crystalline material presenting a coarser and within this a finer radial striation; the striæ themselves are not rectilinear but somewhat wavy, without being individually traceable for any considerable distance. In addition to these there occurs here and there a less regular radial line of a different character, marking the lateral abutment of certain of the large wedges of crystalline material which by their lateral apposition constitute the body of

the concretion. As in all similar formations, there is in addition to this radial striation another that is concentric. The concentric striæ are finely undulatory, the undulations corresponding with the divisions between the coarser radial striæ, and in addition they have a wider range of curvature related to the wedge-shaped masses composing the calculus, each of which comprises a brush of the coarser processes. The exterior of the whole is raised in low elevations corresponding with the bases of the cones in question. The otherwise complete transparency of the calculus is disturbed by the presence of minute brownish granules; these are arranged in concentric lines parallel with the circumjacent concentric striæ, and are more pronounced at the periphery. Similar granules (presumably hæmatoidin) occur throughout the calculus, even in the complex nucleus to be presently described.[1] At the very surface there is a thin crust without radial striation, in which the concentric lines of granules are particularly close; this gives the dark brown colour to the concretions. Apart from the granules in question, however, the general substance has a faint brown tint.

Nucleus.—This is not constituted, as in many urinary calculi of calcium oxalate, by large octahedra, but by an irregular aggregation of small, doubly striated cones. The body of the calculus, which is of similar but more extensive cones, arises on the irregularly shapen nucleus. More particularly some of these nuclear conelets are arranged around distinct centres so as to form miniature calculi of radially and concentrically striated substance; the outlines of such spheres, however, are very irregular, their component conelets being of unequal lengths by reason of the interruptions in their growth occasioned by the juxtaposition of independent cones. Elsewhere the conelets are singly set, and when divided in the axis of their length appear as doubly striated fan-like bodies. There are no octahedra between these different aggregations, but irregular crystalline blocks consisting of long parallel elements, an appearance resulting from the oblique sections of similar interposed and disorderly cones or wedges; where such oblique sections involve the apical ends of the cones, the crystals are more slender. The method of construction it appears, then, has been from the first on the spherular type, and this doubtless by reason of the colloids originally present in the fluid of the cyst.

[1] Under $\frac{1}{12}$ oil imm. the "granules" are distinctly elongated elements of bright orange-red colour, some broader than others, with angular corners.

In the most minute calculi, as studied by microscopic sections, there is no nucleus, but the doubly striated cones meet centrally, the whole being a macroscopic example of the spherules produced by Rainey ('On the Mode of Formation of Shells, &c.,' 1858) in colloid media when two appropriate salts are allowed to undergo double decomposition. Rainey's original experiment consisted in allowing calcium chloride and potassium carbonate to interact in mucilage, when doubly striated spheres of calcium carbonate were formed in the viscous fluid. Later on Dr. Ord produced artificially the spherular and dumb-bell forms of calcium oxalate in diaphragms of gelatine and albumen placed between solutions of ammonium oxalate and calcium chloride ('Influence of Colloids upon Crystalline Form and Cohesion,' 1879).

On the outer surface of one of the smaller calculi the section disclosed a homogeneous reddish-brown layer, here and there artificially fissured in the radial direction, and presumably due to blood extravasation.

As to the radial striation presented by such calculi, this, as fully discussed by Dr. Ord and myself ("Microscopic Structure of Urinary Calculi," 'Path. Soc. Trans.,' vol. xlvi) is indicative of their crystalline structure. In artificially produced spheres, all gradations are met with between smooth-surfaced radially striated forms and others made up of discrete crystals radiating from a common centre.

The concentric striation is more difficult of explanation. The view which first suggests itself is that this marks periodicity in the increment of the calculus, or a temporary cessation in the deposit, such as might arise from the evacuation of the bladder, or from the daily fluctuations in the composition of the urine which occur even in health, for similar striation obtains in renal calculi even in such as lie in proper renal cysts. Yet the striation is too general and constant to justify such an explanation, for it is met with in the crystalline or subcrystalline spheres produced in artificial solutions, as in Rainey's experiments.

Rainey himself writes, "the direct cause of lamination must be looked for in some influence which interferes with the continuous operation of gravity," *i. e.* with the attraction of the particles towards the centre of the calculus; but he does not suggest any causes for the assumed interruptions.

The concentric striation, however, is so wonderfully regular and

universal that it is, I submit, most reasonable to regard it as of secondary production, and the nearest explanation, perhaps, that can be reached is to view it as of the same nature as the lamination of mica schist. Amongst the different explanations which geologists and petrologists have advanced of this, the one which at present finds most favour is that the cleavage is an example of "dynamic metamorphism," or a change resulting from compression. This agency is supposed to develop a secondary parallel structure in all rocks affected by it, and causes a complex of rocks of different ages and characters to simulate a stratigraphical sequence. "The expression dynamic metamorphism emphasises the fact that work is done upon the rocks in the act of metamorphism, it does not exclude molecular changes by implication, and is generally applicable to local and regional effects" ('Petrography,' J. J. Harris Teall, 1888). The concentric striation of such calculi I submit, then, is an example of this dynamic metamorphosis. Geologists recognise the fact that fissile structure may be that of original deposit, but the cleavage arising from compression occurs in planes perpendicular to the direction in which the rocks have been compressed; if, for example, the compression is from side to side the cleavage is vertical.

Sorby (quoted by Geikie, 'Geology,' 2nd edit.) has artificially produced perfect cleavage in pipe-clay through which scales of oxide of iron had previously been mixed; and Tyndall was able to induce cleavage on bees-wax and other substances by subjecting them to severe pressure. The fission is regarded as due, in most cases, to a rearrangement of original clastic particles.

In the case of the calculi the compressing force is the attraction of the particles towards the centre, *i.e.* in the radial direction, hence the cleavage at right angles to this or in the circumferential. For this reason the general striation in a section is not geometrically concentric but polygonal, each column of crystalline material being accurately fissured at right angles to its long axis.

Petrologists describe a zonal structure in the crystalline constituents of igneous rocks, the crystals being built up of successive zones of material having different optical characters. Zonal structure is taken as an indication of changes in the environment of the crystal during its growth, but the phenomenon has no relation to the present subject. A fissile structure arising from variations in

original deposit is observed in microscopic sections of impure urinary calculi of calcium oxalate. When granular urate is mingled with the crystalline oxalate it is usually found in narrow layers parting the crystalline substance into coarse concentric zones of a different kind from those due to the finer secondary circumferential cleavage; periodic sedimentary deposits of urate have become included in the growing surface of the long crystalline wedges constructing the concretion.

The coloration of the calculi from the pancreatic cyst, where especially marked, is limited to certain zones about the surface, but the whole of the crystalline material is faintly tinted throughout, as in the case of many of the urinary forms. The interior of the cyst was blood-stained, and the source of the coloration may be with safety referred to blood. I was unable to obtain any reaction with hydric chloride and ferrocyanide of potassium, but the amount of material was so small that iron if present would have been in too minute a quantity for recognition.

In urinary calculi of calcium oxalate, microscopic sections at times display collections of hæmatoidin crystals, and the fact that the intestinal calculi (of calcium oxalate) in herbivora may present the same coloration shows that this in the urinary forms is not due to urinary pigment, but probably to hæmoglobin.[1] Heated on platinum foil in the Bunsen flame, the material was converted into carbonate of lime, and when placed beneath the microscope and watched, on the addition of dilute hydric chloride disengagement of carbonic acid ensued; the after addition of a solution of ammonium oxalate gave an abundant white crystalline precipitate of oxalate of lime. When fragments, not incinerated, were treated with dilute hydric chloride, whilst watched beneath the microscope, the opacity slowly disappeared with the solution of the salt, whilst a transparent matrix was disclosed; this retained the form and size of the original fragment, and presented a fibrillation corresponding with the striation of the calculus. In this the calculi also resemble the urinary forms.

Remarks.—The occurrence of such calculi in the pancreas is at present, I believe, an unique observation. Dr. Gregor Brodie has told me that Dr. Lionel Beale once showed him some small colourless salivary calculi composed of this substance; but Dr. Beale, unfortunately, writes to me that the matter has passed from his

[1] Urinary calculi of calcium oxalate may give a marked reaction of iron.

memory, and that the observation was never recorded. No chemist has as yet investigated either saliva or pancreatic fluid for the normal presence of a calcium or other salt of oxalic acid. It is not improbable that in both a trace of oxalic acid is occasionally present, but that is a matter requiring future investigation. I have not yet been able to find any octahedra of calcium oxalate in human saliva (collected from the thoroughly cleansed mouth) after treating this with alcohol and examining the sediment obtained by the centrifuge—a method the best of any for demonstrating the presence of the salt in urine (J. C. Dunlop, 'Journ. of Path.,' January, 1896).

The question may here be raised as to the possibility of the oxalate being a purely adventitious product derived from the action of bacteria which may have reached the pancreatic duct and set up an obstructive inflammation leading to the formation of a retention cyst.

Sheridan Delépine ('Trans. Path. Soc.,' vol. xlii, 1891) in recounting some observations on the growth of *Aspergillus niger*, figures octahedra of calcium oxalate in the glycerine peptone gelatine, and he remarks that the production of oxalic acid was perhaps the most interesting phenomenon associated with the growth of the fungus. Whether the acid was produced by oxidation of the glycerine or of the nitrogenous compounds he does not attempt to say. This formation took place, however, only after the mycelial filaments came to grow beyond the surface; it was distinctly connected with the exposure of the mycelial filaments to the air.

The bacteria of the small intestine in the human subject have been carefully studied by Allan Macfadyen, Nencki and Sieber ('International Congress of Hygiene,' vol. ii, London, 1891; and Macfadyen, 'Journ. Anat. and Phys.,' vol. xxi) from a case of artificial anus in the terminal part of the ileum. All of the seven forms so isolated produced fermentation of a 5 per cent. grape-sugar solution *in vitro*, with the formation of acetic, succinic, and two varieties of lactic acid, alcohol being elaborated by all. Similar acids were present in the intestinal contents, resulting from the action of the above bacteria upon the dextroses produced by the pancreatic ferment.

From the small intestine a bacterium was isolated closely resembling *Bacillus coli communis*. This was shown by Dr. Bischler to differ from the colon bacillus by its action on grape-sugar; both

microbes fermented sugar and produced lactic acid, but that from the small intestine produced ordinary optically inactive lactic acid, whilst the common colon bacillus produced the active dextro-rotatory paralactic acid.

No known bacteria, however, produce oxalic acid. As to the formation of calculi of calcium oxalate in the intestine, these are confined to herbivora and obviously due to the ingestion of oxalates in vegetable food-stuffs.

In streak cultures of *Bacillus coli communis* on nutrient gelatine it is usual to observe a cloudiness which slowly extends into the medium from the line of the culture. I have investigated the cause of this especially to see whether any formation of oxalate took place. A microscopic examination of such turbid jelly shows that the appearance is due to the presence of minute spherules singly and in small aggregates; the spherules may be examined without special preparation by making thin slices of the gelatine, or after staining thin slices with aniline dyes, for they readily take up the colour, and might on a casual inspection be passed by as micrococci. When the jelly slice is treated with dilute hydric chloride, the minute spherules vanish before the advancing acid without any disengagement of gas from them. The appearance here and there of a bubble arises from the carbonate of soda added to the jelly in its preparation; the ordinary nutrient gelatine if warmed and diluted exhibits free effervescence when acidified with dilute hydric chloride. That the spherules in question are calcium phosphate is confirmed by the presence in the same jelly of the common "housetops" of triple phosphate, and at times by the presence of stellar phosphate. The crystalline aggregations of the last named may be visible to the naked eye, and closely simulate non-liquefying colonies. All these crystalline forms disappear before dilute hydric chloride without gas production. The changes, in short, result from the formation of ammonia in the later stages of the growth of the bacillus, and its evolution is readily shown by inserting moistened litmus paper or a rod of white glass dipped in Nessler's reagent, into the atmosphere of the tube; the medium itself is, of course, at this stage strongly alkaline.

The change is similar to that which ensues in urine during bacterial fermentation or on boiling. As I have shown (International Congress of Hygiene and Demography, London, 1891, Part ii, Bacteriology; and 'Trans. Path. Soc.,' vol. xliii, 1892), when urine

is boiled an evolution of ammonia takes place from hydrolysis of the urea, and leads first to the precipitation of normal calcium phosphate, and later to the crystallisation of ammonia-magnesium phosphate. Although this precipitation occurs most readily in alkaline and amphoteric urine, it can always be brought about in an acid sample if the boiling be prolonged for ten or fifteen minutes.

I am not prepared to deny altogether the view that the heating of the fluid is in itself sufficient for a precipitation of normal calcium phosphate, but if true at all it is certainly not so in all cases; an acid urine may remain clear on boiling for several minutes. Nessler's reagent will show the commencement of a disengagement of ammonia whilst the fluid is still clear, but as the disengagement proceeds, the right degree of alkalinity is reached and the fluid grows turbid from the precipitation of normal calcium phosphate.

In the preparation of ordinary nutrient broth and gelatine one may often notice the tubes become turbid when placed in the steam steriliser, and on cooling become again clear, and this on each of the four occasions of a discontinuous sterilisation. The turbidity of the heated liquid at once vanishes on the addition of a solution of ammonium lactate or a trace of hydric nitrate. The media after the addition of carbonate of soda solution are commonly amphoteric, or give an acid reaction with blue litmus paper although made just alkaline enough to give the opposite reaction with the red. Dr. Gregor Brodie has suggested to me that here the heat by precipitating calcium phosphate sets free acid, and that on cooling, this liberated acid suffices to re-dissolve the phosphate.

That the common nutrient media contain phosphate of lime is easily proved by the ordinary tests of ammonium oxalate and nitro-molybdate of ammonia.

The typhoid bacillus, so like *Bacillus coli communis* in most ways, is like it also in this. The turbidity of the jelly slant beneath a culture is due to precisely the same cause, viz. the evolution of ammonia.

In incubated broth cultures of either bacillus the same disengagement takes place, and can readily be shown about the fifth or sixth day by the means already referred to.[1] I have seen similar turbidity

[1] The production of ammonia may be found also in cholera cultures, where it may lead to the formation of triple phosphate in the liquefied gelatin; and it has been long known to occur in *Staphylococcus pyogenes aureus*.

of the jelly arise beneath streak cultures of *Sarcina lutea, Micrococcus citreus agilis*, &c.

The macroscopic collections of stellar phosphate in the nutrient jelly must not be confused with the white sparkling crystalline spheres of sodium carbonate, which may arise in the clear jelly in which micro-organisms are growing, and even when nothing has been sown in it; here the crystallisation is probably due to the loss of water, and the spheres when small are remarkable imitations of bacterial colonies. The effervescence which ensues when dilute hydric chloride is applied to such, shows at once their real nature.

The outcome of this digression is that a bacterial explanation of the formation of these pancreatic calculi must be dismissed, even though the violence were done of supposing the colon bacillus present in the duodenum.

In 1849 Sir Alfred Baring Garrod demonstrated the presence of oxalate of lime in the blood in certain cases, chiefly of gout ('Med.-Chir. Trans.,' vol. xxxii, 1849, London). In the first case, one of chronic hiccough and vomiting, examination of blood taken from the vessels of the head showed traces of uric acid, and a heavy whitish deposit of an immense number of octahedra of calcium oxalate, a few spheres, and some dumb-bells. His method consisted in drying the serum in a water bath, boiling with alcohol, making an aqueous solution, evaporating to the consistency of very thin syrup, and adding acetic acid so as to strongly acidulate the fluid; if oxalic acid is present in the serum, crystals of oxalate of lime will form after the fluid has been allowed to rest for some hours.

There is, thus, no physiological or chemical difficulty in supposing that oxalate may be present in the secretions in general, especially as the evidence goes to show (J. C. Dunlop, loc. cit.) that the whole of the oxalate in the urine is derived from the ingestion of this material in vegetable food-stuffs. In the urine, the chief solvent of the calcium oxalate is acid sodium phosphate, but, as Dunlop remarks, it is not the only one present, although his own observations made with urea and chlorides were negative in result. So in the fluid of the pancreatic cyst the crystallisation of the oxalate probably resulted from the absorption of some second substance necessary to hold it in solution.

The crystallisation of calcium oxalate has been observed in fluids other than pancreatic. Virchow, in his lectures on goitre (Die

Krankhafte Geschwülste), states that octahedra of this substance may not infrequently be found in the fluid of thyroid cysts. The first observation of this was made by Daake ('Zeitschr. für nat. Med.,' 1865), and has been fully confirmed by Virchow himself.

April 21*st*, 1896.

DISEASES OF THE GENITO-URINARY ORGANS.

1. *Atrophy of the kidney from stricture (? congenital) of the ureter. (Card specimen.)*

By G. Newton Pitt, M.D.

History.—The patient was a young adult who gave no history of any abdominal injury and presented no symptoms during life pointing to any renal disease. The urine was normal.

Description of specimen.—The right kidney is seen to be uniform on the surface and normal in appearance, presenting no interstitial changes; but it is only half the size of the opposite kidney, which is slightly hypertrophied. There is a thick dense stricture of the ureter situated about half an inch from its commencement, and the tube beyond is normal. The strictured portion only admits a probe.

Remarks.—In two other specimens I have met with a stricture of the ureter at this spot, and in none was there any history of a calculus or of traumatism. Is the defect a congenital one? It is interesting that there should be no hydronephrosis and only an atrophy of the kidney. *January* 21*st*, 1896.

---

2. *Case of large white kidneys with thrombosis of the renal veins and the inferior vena cava. (Card specimen.)*

By Theodore Fisher, M.D. (per J. H. Targett, M.S.).

History.—A girl, aged 13, was admitted to the Bristol Royal Infirmary on November 28th. About three weeks before admission her legs began to swell, and at the time of admission there was

extreme swelling of the face, body, and legs. No history of scarlet fever. The urine was of sp. gr. 1020, contained 3 per cent. albumen, some blood, and granular casts. The amount of urine during the time she was in the infirmary varied between 15 and 46 oz. in the twenty-four hours. On December 5th it was 24 oz.; on the 6th, 24 oz.; on the 7th, not recorded; but on the 8th, the day before her death, it was 12 oz. The sp. gr. was 1015 on all these occasions, and the amount of albumen 2·2 per cent., 3 per cent., and 1·5 per cent. The pulse was weak throughout. Temperature 96° on admission, rose to 102° the next day, and kept above 100° until the day before death, when it fell to 96°. Bowels constipated. There was some dulness at the base of the left lung. The œdema of the face and body diminished during the time she was in the infirmary, but the œdema of the legs remained about the same. Towards the end the child failed rapidly, and was thought to have died of cardiac failure. She died on December 9th.

Autopsy.—A child of about the average height for her age. There was shortening of the left leg due to old hip disease, and great scarring around the left hip-joint. Considerable œdema of both legs and some general anasarca existed.

Brain not examined.

Thorax: Trachea and bronchi normal. The left pleural cavity contained about 10 oz. of fluid, and the anterior half of the pleural surface of the lung was covered with granular exudation. There was a patch of thicker exudation over the right lower lobe. The lungs themselves were both congested throughout.

Heart: Old adhesions of the pericardium over the auricles and upper part of ventricles, back and front. Recent exudation very limited in position and amount over posterior aspect of right ventricle. All the valves healthy. The heart not markedly dilated. Weight, 4½ oz.

Abdomen contained about 20 oz. of ascitic fluid. Liver 45 oz., slightly fatty. Spleen, nothing noteworthy, 4¾ oz.

Kidneys: Both were well-marked examples of an early stage of the "large white" kidney. They were enlarged and of a rounded shape. The stellate veins stood out markedly on the pale surface. In addition to the stellate veins there was everywhere a fine network of distended smaller vessels. On section the most obvious feature was the great congestion of the bases of the pyramids. The cortex was swollen, pale yellow, and opaque; but the interlobular vessels

were in places still distended with blood, and the glomeruli were everywhere visible. Running between the pelvis of the kidney and the renal substance in the divisions of the renal vein were areas of white clot. This attracted attention to the renal vein outside the kidney, which was found to be thrombosed on both sides.

The vena cava was also thrombosed as far as the bifurcation. Above, this clot did not extend beyond the inferior border of the liver. The cut ends of the vena cava and the renal veins showed the yellowish-brown clot deposited in concentric layers presenting here and there areas of granular softening.

The presence of this thrombosis led to re-examination of the pulmonary arteries, which were slit up to their bifurcations. At the bifurcation of each, thrombi were discovered invading the divisions of these vessels. The clots were partially adherent to the arterial wall, and of a dirty, yellowish-brown colour. They only partly obstructed the lumen, and the main clot on the left side was channelled through its centre.

Microscopic sections of the renal vein showed that the clot in places was rapidly organising. Lying around and between the divisions of the vein were numerous small nucleated cells resembling lymphocytes, and finely granular material. This appeared to be coagulated lymph, and subsequent dissection of the hilum showed that the lymph vessels were distended with coagulum. The substance of the kidney on microscopic examination showed extensive epithelial proliferation. The glomeruli were also affected, and there was much new formation of connective tissue between the tubules.

---

3. *Case of bilateral sarcoma of the hilum of the kidney.* (*Card specimen.*)

By Theodore Fisher, M.D. (per J. H. Targett, M.S.)

History.—The patient was a rather thin girl, aged 2 years. The head presented well-marked Parrot's nodes, the ribs were beaded, and the ends of the bones of the forearms enlarged. No petechiæ over the skin. Palpation of the long bones gave no

evidence of subperiosteal hæmorrhages. There was a doubtful history of syphilis in the mother.

Autopsy.—Head: The cranium when sawn off showed the bone to be of great thickness. It was fully ¼ inch in diameter. On the inner surface of the dura mater, running in two broad bands on either side of the falx cerebri, were effusions of blood which had coagulated and remained more or less firmly adherent to the dura mater. A layer of yellowish transparent exudation lined the inner surface of these hæmorrhages, and from the extent of this exudation, which spread considerably beyond the margins of the hæmorrhagic areas, it appeared to have been deposited upon the surface of the blood and not merely to be a part of the clot. The brain was healthy.

Thorax: Trachea, lungs, and pleura normal.

Abdomen: Liver enlarged, appeared somewhat tough, but microscopically showed nothing abnormal. Spleen enlarged; weight 4 oz.

The kidneys presented a somewhat strange appearance. The extra-renal portion of the pelvis of each was thickened and of a purplish-brown colour. The thickening ended abruptly at the junction with the ureter. On making a section of the kidney, a broad band of tissue, differing in appearance from the kidney substance, was seen between the pelvis of the kidney and the renal tissue. This band was thickest opposite the interpyramidal portions of the cortex, and was absent at the apices of the pyramids, where the pelvis and kidney substance were of necessity in contact. The band of abnormal structure was granular in appearance, and of a mottled purplish-brown colour. Weight of each kidney, 1 oz.

Suprarenals and pancreas healthy.

Stomach and intestines showed nothing noteworthy, but enlarged lymphatic glands were present in the mesentery of a deep reddish colour. As is so often the case in children, in addition to enlarged glands scattered through the mesentery, others lined the whole length of the small and large intestines at their contact with the mesentery and mesocolon. Other lymph glands surrounded the ureters, and larger ones extended from the femoral vessels along the vena cava and aorta to the liver. Above the diaphragm enlarged glands of the same reddish colour were present in the anterior and posterior mediastina. Enlarged glands also surrounded the vessels of the neck and were present below the lower jaw. They were also present in both axillæ. Microscopically these glands showed

nothing noteworthy, unless it was the presence of a considerable number of cells that stained very deeply with eosin.

Microscopical examination of the growth in the kidneys showed that it was a sarcoma chiefly composed of round cells. There were a few oval and spindle cells, with here and there a multinucleated corpuscle. The growth was bounded on one side by the muscular coat of the renal pelvis, and this was partly invaded, so that bundles of unstriped muscle were seen among the adjacent cells of the neoplasm. Where it was in contact with the kidney substance the tumour was limited by a thin fibrous capsule. Hence there was no invasion of the renal tissue.

---

4. *Diffuse symmetrical lympho-sarcomatous infiltration of the kidneys of a child; with deposits in the cæcum, diaphragm, &c.* (*Card specimen.*)

By F. Parkes Weber, M.D.

The specimen is taken from a girl aged 5. A mass about the size of a small cocoanut, attached to the cæcum, should perhaps be considered the primary tumour. At first sight the kidneys resembled very "large white kidneys." Each kidney was symmetrically enlarged to about three or four times the natural size, its substance was pale on section, and the capsule stripped off easily. They gave no iodine reaction for lardaceous disease. A nearer examination showed that they were diffusely infiltrated with some new growth, small portions only of the real kidney substance being distinguishable from the neoplasm, as darker stripes, here and there. In fact, what we at first took to be enlarged kidneys were in reality masses of new growth retaining the form of the kidneys, and containing the renal substance, or the remnants of the renal substance, interspersed in it. There were several wedge-shaped infarcts, probably, as suggested by the resident medical officer, Dr. Luce, due to pressure of the new growth causing obliteration of small arteries.

History.—The child was in the German Hospital only about a week before her death, and the past history is very defective. The

urine examined shortly before her death contained a considerable amount of albumen, a few casts, but no red blood-corpuscles.

The walls of the cæcum and vermiform appendix, the diaphragm, part of the pericardium, and some of the mesenteric and mediastinal lymph glands, were found infiltrated with new growth, but the liver, to the naked eye at all events, appeared unaffected.

The kidneys themselves have unfortunately not been kept. I had, however, some microscopical sections prepared, and my colleague, Dr. Michels, whose case it was, wished me to show them at this Society. The renal tubules and glomeruli are separated from each other by the small round cells and very scanty fine reticulum of the tumour. A wedge-shaped patch of kidney substance, purposely included in one of the portions selected for microscopic examination, will be seen to have escaped the almost general lympho-sarcomatous infiltration. In one of the specimens an infarct may be observed.

The liver is known to be occasionally, though rarely, the site of a diffuse general malignant growth, and a like infiltration with new growth is occasionally found involving one kidney in infants; but a symmetrical diffuse affection of both kidneys is, I believe, very uncommon. Symmetrical malignant disease of both kidneys has been described by Dr. J. Abercrombie ('Trans. Path. Soc.,' vol. xxxi, p. 168), but in his cases there was nothing like the diffuse distribution throughout each kidney, which is the remarkable feature in the present case.

The only apparently similar condition that I can find described, occurred in a seven months' fœtus, whose kidneys where shown by Mr. F. T. Paul at the annual meeting of the British Medical Association at Liverpool in 1883 (see 'Trans. Path. Soc.,' vol. xxxvii, p. 293). Mr. Paul states that each of the kidneys was symmetrically enlarged to a size which would be the normal one in a full-grown man, and that this enlargement appeared to be due to infiltration of the organ with an adeno-sarcomatous growth.

I was at first disposed to class the growth in the present case as sarcomatous, but after showing the specimen to various pathologists, although the opinions expressed by them as to its probable nature were not quite unanimous, I believe that the tumour is more correctly described as lympho-sarcomatous than as sarcomatous. This is the view taken by Mr. Shattock. The diffuse symmetrical distribution of the growth in the kidneys speaks strongly in favour of lympho-sarcoma.

The whole subject of lymphadenomatosis has quite recently been admirably treated by Mr. W. G. Spencer and those who took part in the subsequent discussion at the annual meeting of the British Medical Association ('Brit. Med. Journ.,' January 18th, 1896), and there is no necessity to reopen the question.

The present case is of much interest, not only on account of the rarity of the condition in the kidneys which I have just described, but as affording one of numerous examples where the characters of a lymphadenomatous growth approach closely those of an ordinary small round-celled sarcoma. The resemblance to ordinary sarcoma in this case was shown by the microscopic structure of the tumour, and by the infiltration of the muscular part of the diaphragm. There is, indeed, a very wide difference between such cases as the present one and the more chronic forms of lymphadenoma or Hodgkin's disease, whether they are considered from their clinical or from their pathological aspects. *March 3rd*, 1896.

---

5. *Large sarcoma of the kidney.* (*Card specimen.*)

By J. D. Malcolm.

Description of Specimen.—The specimen consists of a section of the left kidney together with a large spongy new growth springing from one end of the organ. The growth measures 8 inches by 5 inches, and is enclosed by a thin layer of renal tissue as well as by the fibrous capsule of the kidney. At the lower end of the tumour the growth has perforated the capsule and formed nodular masses on the inner side of the kidney. The structure of the tumour has undergone extensive degeneration. Histologically it is a sarcoma composed of round and oval cells with large tracts of degeneration and hæmorrhage.

History of case.—The patient was a girl aged 19, who appeared healthy and well grown, though somewhat anæmic. On the left side of the abdomen there was a large tumour, which extended downwards nearly to the pubes and across the abdomen to the outer border of the right rectus muscle. It had considerable mobility, but could

not be turned out of the left loin. There was a resonant area behind it, and much bowel overlapped it in front, so that less than half its anterior surface was dull on percussion. Two years previously the patient was seized with pain in the abdomen when at work as a book-keeper, and had to go home. Much blood came away with the urine, and in a few hours the pain subsided. These attacks of pain and hæmaturia continued for ten days, and then the symptoms disappeared. A doctor who saw the girl at this time stated that "something" could be felt in the abdomen. Four or five other attacks like that above described occurred at varying intervals during the next two years. The abdomen steadily enlarged.

After I saw the patient no blood and no malignant cells were detected in the urine. In one specimen only was there a trace of albumen; she was under my observation for eighteen days prior to operation.

On June 9th, 1894, the tumour was removed through an incision outside the left rectus muscle. The descending colon lay *outside and behind* the growth. Some loose tissue and glands on its inner side were also removed. The end of the ureter was healthy, and was fixed outside the wound. Convalescence was uninterrupted.

Two months after the operation the patient appeared very well. Nothing wrong was detected except that there seemed to be a slight drag on the scar where the ureter had been fixed, and there was impaired resonance outside the scar.

On October 15th, 1894, there was a large solid mass in the abdomen, stretching right across it, and a less definite mass behind the uterus and connected with the growth in the upper abdomen. There were three enlarged glands in the neck, just above the clavicle on the left side, one being rather larger than a walnut. The patient gradually sank, and died on November 8th, 1894.

Autopsy.—On opening the abdomen the intestines were found greatly distended with gas. There was no peritonitis. Some thick black fluid consisting of broken-down growth and blood welled up from the pelvis. A mass of growth the size of two fists was attached to the great omentum and hung down into the pelvis. It was quite diffluent, and largely composed of blood. After separating the colon, which was adherent beneath the site of the abdominal incision, a mass of soft growth was found filling the loin where the tumour had been, and extending down to the left iliac fossa. Its exact relations could not be defined owing to the diffluent state of the

sarcomatous growth which flooded the peritoneal cavity. Extension downwards was distinctly on the *left* of the mesentery. The glands along the spine were enlarged, and the pouch of Douglas was full of growths. The whole length of the colon seemed free, but contained hard scybala.

Liver showed no secondary deposits.

Through a hole in the diaphragm the heart and lungs were explored. There were no pleuritic adhesions, the lungs collapsed well, and no lumps were felt in the mediastinum to indicate secondary deposits. But there were two moderately enlarged glands in the neck behind the left sterno-mastoid muscle and a little above the clavicle; the larger was about the size of a bantam's egg.

Uterus very small. Right ovary very small, but seemed healthy. Broad ligaments were felt, and seemed free, though bathed by the diffluent growth in Douglas's pouch. A cyst the size of a hen's egg occupied the left ovary. Bladder normal.

Right kidney: Its surfaces were covered with minute abscesses. The capsule stripped off easily, and the organ was much decomposed. On section the pelvis and calyces were found considerably dilated and filled with tenacious muco-pus. Small abscesses were seen in the pyramids, and lines of suppuration in the cortex. A flattened pyriform calculus lay in the pelvis; it was ¾ inch long, and ½ inch at wider end, and apparently was composed of uric acid with a partial covering of phosphates. The ureter was moderately dilated and thickened. At its upper end, where it joined the renal pelvis, its wall was deeply ulcerated, and it looked as if this had been caused by the irritation of the calculus. The excess of mucus in the material in the renal pelvis suggested that the calculus had plugged the ureter.

The tumour is preserved in the museum of the Royal College of Surgeons, and I am indebted to Mr. J. H. Targett for the description of it.

Remarks.—This case teaches that however little inconvenience a sarcoma of the kidney may give in its early stages, an operation should be performed as soon as the lesion is diagnosed. As a rule the diagnosis is not difficult, and it is a pathological certainty that changes go on in a renal tumour which render an operation more dangerous day by day, both as regards its immediate and its remote effects.

May 19th, 1896.

6. *Adrenal tumours of the kidney.*

By J. H. Targett, M.S.

[With Plate II.]

The preparations and microscopic sections exhibited are taken from three adrenal growths found in connection with the kidney.

1. The first consists of a small, flattened, yellowish nodule, about the size and shape of the little finger-nail. It was discovered in the course of an ordinary post-mortem examination when the fibrous capsule of the kidney was being detached. The yellow colour of the nodule and its situation beneath the capsule of the kidney attracted attention and suggested its nature. A vertical section through the fibrous capsule and subjacent renal tissue displayed a shallow depression in the cortex which was filled with the yellow mass above described. The mass was an eighth of an inch thick, and was closely attached to the fibrous capsule over it and to the cortex beneath. On reviewing its position the growth was found to be near the *lower* end of the left kidney and upon its *anterior* surface. The kidney itself was normal, as well as its fellow and both adrenal bodies. Whether the opposite kidney contained a similar nodule was unfortunately not observed; but in two other instances I have found these aberrant adrenal bodies in both kidneys, and they were very symmetrical in shape and position.

Microscopical examination.—The substance of the kidney is normal. Resting upon the convex border of the section is the accessory adrenal body. At the margin of this body the fibrous capsule covering the cortex of the kidney is seen to split into two layers of nearly equal thickness. The superficial layer can be traced continuously from the kidney over the aberrant adrenal to the kidney substance again. The deep layer, however, is imperfect, and there are several large gaps in it through which the adrenal substance has wandered into the renal cortex. Conversely a few convoluted tubules have passed into the adrenal and are seen on section between certain columns of the zona fasciculata. They are easily distinguished by their distinct lumen, their epithelial lining, and the different reaction of the nuclei to stains.

The structure of this accessory adrenal appears quite normal.

The distinction between cortex and medulla is well marked; in the latter one or two large vessels are seen, while the capillary system of the cortex is a striking feature. The cortical cells are large, very granular, and faintly stained in contrast with their nuclei. The specimen, therefore, may be regarded as a typical example of an aberrant adrenal body. The mingling of the renal and adrenal tissues, as well as the imperfect fibrous septum between the two organs, I have observed in other instances of this abnormality, and the same conditions have been met with in a case where the adrenal was situated beneath the capsule of the liver. In the figure given by Schmorl [1] of this specimen, there is a similar layer of connective tissue separating the two organs, the continuity of which is broken by the blending of the hepatic and adrenal tissues. There are also well-defined bile-ducts embedded in the adrenal.

Quite recently a specimen of multiple adrenal bodies in the broad ligaments of a fœtal uterus has come into my hands.

2. The second specimen exhibited consists of a kidney laid open by a coronal section. It measures 3 inches in length by 2 inches in thickness, and seems small for an adult viscus. Projecting from the convex border of the organ is a rounded tumour 2 inches in its chief diameter. On the cut surface of the specimen the tumour is seen to be wedge-shaped, with its rounded base projecting beyond the level of the renal cortex for an inch and a half, and its apex penetrating the renal substance so deeply that it touches the wall of the pelvis of the kidney. The hilum, the ureter, and the renal vessels are normal and quite free from growth. The extreme length of the tumour from apex to base is 2½ inches.

The substance of this neoplasm is separated from that of the kidney by a thin but distinct capsule. Externally it is covered with the ordinary fibrous capsule of the kidney. On removal of this the tumour presents a nodulated exterior, and in one spot it is seen to have perforated the fibrous capsule.

The preparation is preserved in Guy's Hospital Museum, and is without history. From its age the substance of the tumour has become decolorised, but it is friable, and there appears to have been large extravasations of blood in it.

Microscopical examination.—Sections were made from the margin of the tumour, and included the adjacent renal tissue. The capsule which separates the tumour from the kidney is composed of

[1] 'Ziegler's Beiträge,' vol. ix, p. 525.

vascular connective tissue, enclosing a few compressed renal tubules and fibroid glomeruli. Beyond this the kidney substance is infiltrated with small round cells for a short distance from the tumour, and no doubt the fibrous boundary of the latter has been developed from similar cells resulting from the irritation of the growth.

The periphery of the neoplasm is composed of narrow elongated alveoli containing a double row of large granular cells like epithelium. The walls of the alveoli are very thin, and in many places consist of little more than capillary vessels. The arrangement of the cells in double rows, though conspicuous at the margin, is soon lost in passing towards the centre of the tumour, where the alveolation is very imperfect, and the most striking feature is the enormous size of the cells. The appearances of this part of the growth are shown in the accompanying micro-photograph. The faint outlines of the large cells can be discerned, with their round deeply-stained nuclei. There is no true alveolation. What exists is produced by the capillary vessels, whose double row of elongated nuclei (that is, endothelial cells) are easily recognised. The centre of the tumour is entirely necrotic, and will not stain. Around it there are some pigment granules, and these would seem to indicate that the necrotic area was in part the result of extensive extravasations of blood. At the growing margin of the tumour there are vacuoles in some of the cells, which doubtless represent empty fat globules.

3. The third exhibit consists of two microscopic slides which were very kindly given me by Professor McWeeney, of Dublin, and are placed alongside of the preceding for the sake of comparison. They were taken from an adrenal tumour of the kidney, which is fully described and illustrated in the 'British Medical Journal,' 1896, vol. i, p. 323. Having examined these slides with great care, I entirely agree with the description which Professor McWeeney has given, and I venture to quote the chief points in it. "The structure of the tumour consisted of rows and groups of large columnar or cubical cells, obviously epithelial in character, with clear or reticulated protoplasm and a relatively small round nucleus. The rows were usually two cells deep and there was no trace of a lumen. On each side of the rows was a line of delicate endothelial nuclei, evidently forming the wall of a capillary vessel, in which the remains of blood could here and there be traced. Between the cells forming these rows there was no stroma

DESCRIPTION OF PLATE II.

FIG. A illustrating Dr. Rolleston's paper on "Sarcoma of Mamma containing Multinuclear Giant-cells." (Page 267.)

From a drawing in the possession of Mr. MARMADUKE SHEILD.

FIGS. B and C illustrating Mr. Targett's paper on "Adrenal Tumours of the Kidney." (Page 122.)

FIG. B is from a photograph of the kidney, which has been laid open by a longitudinal incision through its convex border. It represents the wedge-shaped outline of the tumour in the cortex, the apex of which touches the pelvis of the kidney. (The specimen is preserved in Guy's Hospital Museum.)

FIG. C is from a micro-photograph of the tumour. It depicts the large size of the cells and their deeply stained nuclei. There is no true alveolation, and the stroma is almost entirely formed by capillary vessels, which are indicated by double rows of elongated nuclei (obj. $\frac{1}{8}$ inch).

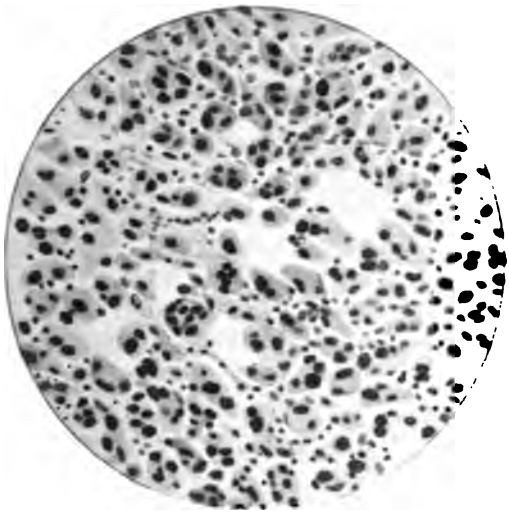

Fig. A.

Fig. B.

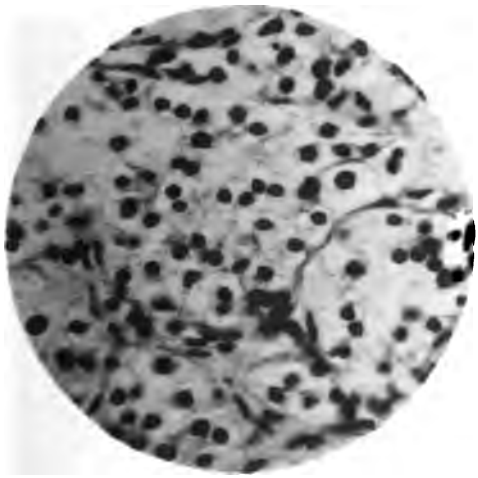

Fig. C.

whatever. In fact, no stroma existed, the tumour cells being placed directly on the endothelium of the capillaries. Distinct fibrous trabeculæ divided the tumour substance into lobules, and supported the larger vessels. All transitions were traceable from lengthy rows or double columns to circular groups of cells."

"The neighbouring kidney tissue showed atrophied or dilated tubules, hyaline glomeruli, thickened vessels, and tracts of connective tissue crammed with nuclei. The capsule which everywhere intervened between the kidney substance and the tumour consisted, on the tumour side, of dense laminated connective tissue, and on the kidney side of atrophied and compressed renal elements. Nowhere could a transition from urinary tubules to tumour tissue be traced."

Remarks.—It will be admitted, I think, that there is a very close resemblance between the microscopical appearances of these tumours, and that they should be placed in the same category. In my Erasmus Wilson lectures, delivered in the spring of 1894, I dealt with the relation of primary adrenal tumours to renal tumours of adrenal origin. In reviewing the mass of literature on this subject which has accumulated since the publication of Grawitz' original paper in 1883, one cannot but feel that not a few writers have been carried away by the ingenuity of the theory, and have been led to refer many ordinary renal carcinomata to this extraordinary class. For that reason especially pathologists are indebted to Professor McWeeney for the thorough and critical manner in which he has treated the evidence derived from his two cases. Briefly stated, the argument is as follows:—It is now well known that bodies identical in structure with the adrenal bodies are found embedded in the cortex of the kidney and beneath its fibrous capsule. The normal adrenal body under rare circumstances gives rise to a primary malignant tumour of a peculiar type. Certain tumours are occasionally met with in the kidney which on the one hand bear a resemblance to the normal adrenal body, and on the other to the rare and peculiar primary tumour which arises in the adrenal body. Therefore, it is concluded that these renal tumours have originated in an aberrant or accessory adrenal body which was previously embedded in the kidney.

Now as these accessory aberrant adrenals are not very frequently seen in the kidneys, even by those daily engaged in *post-mortem* examinations, it follows that renal tumours of this type must like-

wise be rare, though we may suppose that, like other aberrant bodies, they are specially prone to undergo malignant changes. During the past five years I have examined a very large number of renal tumours of various kinds, and I feel certain that the specimen here recorded is the only one in my experience which has presented the features of an adrenal tumour. Hence, while thoroughly accepting the hypothesis of Grawitz as to their origin, I believe that the frequency of this class of tumour has been much exaggerated by some writers.

The cardinal features of the adrenal tumour of the kidney are these:—Firstly, it is distinctly encapsuled where it stands in relation with the kidney tissue, and this boundary may be looked upon as a derivative of that imperfect layer of the fibrous covering of the kidney which is seen in sections of an aberrant adrenal separating the renal from the adrenal elements, as above described. Not that the tumour is rendered innocent by this encapsulation, for in my preparation the growth had fungated through the fibrous sheath of the kidney, and was clearly malignant. In Professor McWeeney's case the neoplasm is described as consisting of "a mass of confluent encapsuled nodules; . . . . the encapsulation of each nodule was perfect and definite."

Secondly, the histological appearances of the adrenal tumour are remarkable and characteristic—the large size of the cells, their arrangement in double rows or columns (at least in the active parts of the tumour), the absence of a lumen in these columns, and the abundant capillary network which takes the place of an ordinary stroma. As in the normal zona fasciculata, the cells seem adherent to the walls of the capillaries.

And thirdly, the cells of the adrenal tumour show the same tendency to fatty degeneration as the cortex of the adult adrenal body. To this may be added the liability to hæmorrhagic extravasations, which may break up the centre of the tumour and lead to its necrosis, or cause orange staining of the firmer parts of the specimen.

There is one argument used by Professor McWeeney which is drawn from a case recorded by Mr. Henry Morris ('Brit. Med. Journ.,' 1893, vol. i, p. 2). It is to the effect that "tumours of precisely similar structure not infrequently originate from the suprarenal capsule, and growing downwards into the kidney cause its destruction." The actual specimen described in support of this

opinion does not, however, I venture to think, bear this interpretation. I have examined it carefully and there can be no doubt that the tumour is primary in the kidney and covered with the ordinary fibrous capsule of the organ. Whether it originated in an aberrant adrenal embedded in the kidney is another question. From my own histological investigations I have not been led to take this view of it. But this particular case apart, there seems to be little evidence that primary tumours of the adrenal body invade the kidney in the manner described, at least in their early stages. They undoubtedly produce considerable flattening of the adjacent part of the kidney as the mechanical effect of pressure, but the two organs remain separated by the fibrous capsule of the kidney in the most definite manner. The relations of that capsule to the various tumours in and around the kidney is one of the most important points in their morbid anatomy. When it is remembered how long the fibrous capsule resists the tension of a new growth within the kidney, it becomes more difficult to believe in its penetration from without by a neoplasm which can readily extend in other directions. Further, the primary adrenal tumour pushes the kidney directly downwards, thereby rendering it unusually prominent; sometimes the kidney becomes stretched like a cap over a part of the tumour. In a case recorded by Cohn ('Berl. klin. Wochen.,' 1894, No. 11) there was an abdominal tumour in the lumbar region, with apparently a considerable enlargement of the liver. But at the autopsy the liver was normal in size, though displaced downwards; and it was suggested that owing to the position of the adrenal tumour at the posterior surface of the liver its enlargement would tend to produce a rotation of the liver on its transverse axis, and thus render its anterior margin very prominent below the ribs. A distinct transverse groove was observed crossing the abdominal tumour, and this was found to mark the junction between the tumour and the kidney—a clinical sign which may possibly be useful in distinguishing adrenal tumours from those of the kidney. Again, the diaphragm, with the liver and vena cava on the right side, speedily become invaded by the primary growth in an adrenal body, and as a rule the growths are not bilateral like the renal tumours of childhood. Clinically the absence of urinary symptoms, the rapidity of growth, and the extensive metastases are important; while a curious overgrowth of hair on all parts of the body has been observed in several instances, both in children and in adults. This hyper-

trichosis is of interest in association with the well-known pigmentation of the skin occurring in Addison's disease of the suprarenal capsules.

The more favourable prognosis of the cases in which the tumour has been removed by operation is an important clinical point. Rupprecht ('Central. f. Gynäk.,' 1890, Bd. xiv, s. 592) records the following very interesting case:—A child, aged 2½ years, was admitted with a tumour in the right side of the abdomen. It had been noticed for six months, and had grown quickly. It was at the back of the abdominal cavity, and extended to the left as far as the middle line. Though solid, the tumour had a semi-elastic feel and a nodular outline. Urine normal. The tumour was removed by operation, and at the end of one year there were no signs of recurrence. Examination showed that the tumour was situated under the fibrous capsule of the right kidney, and formed a well-defined rounded mass the size of a fœtal head. The kidney in other respects was normal. Professor Neelsen, who examined the growth microscopically, reported that its structure resembled adrenal tissue, for it consisted of delicate columns of large finely granular cells like those of the cortex of the adrenal body.

In conclusion, I would submit that adrenal tumours of the kidney and primary tumours of the adrenal body should be studied together, as mutually helpful. Both conditions are decidedly rare, and for that reason every alleged example of these diseases should be critically examined and carefully reported.

May 19th, 1896.

---

7. *Epithelioma of the ureter causing hydronephrosis.*

By Henry Rundle, F.R.C.S. (per J. H. Targett, M.S.).

History.—E. B—, a gardener, aged 46, a weak and emaciated man, was admitted into the Portsmouth Royal Hospital on April 2nd, 1895, under my care. His parents died from old age, but two sisters are stated to have died from cancer. Nearly the whole of his body was affected with psoriasis, which had existed for sixteen years. About a year before admission he noticed a fulness in the right side

of the abdomen, which increased gradually and painlessly. On admission the abdomen was flaccid, except on the right side, where a fluctuating swelling, dull on percussion, occupied the front and lower part of the abdomen; it commenced two inches below the thorax, and extended to the middle line as well as far back into the lumbar region.

Urine clear, freely voided, sp. gr. 1018, no albumen; he had passed blood, but not recently. There was no history of pain and no other symptoms of renal calculus.

On April 19th the swelling was tapped, and 80 ounces of fluid were evacuated. This fluid was alkaline, sp. gr. 1020, and became almost solid on boiling. The sediment obtained from the fluid was found to consist chiefly of blood and large granular corpuscles with a few columnar epithelial cells.

For a fortnight there was no return of the swelling. The man became very emaciated, and so weak that he was unable to sit up in bed. Suspecting malignant disease, it was not deemed advisable to attempt a removal of the kidney. The fluid having slowly re-accumulated, the cyst was tapped on May 29th and 60 ounces of fluid similar to that obtained before were evacuated. He passed into a semi-comatose state, and died from exhaustion on June 4th.

Autopsy.—Numerous secondary deposits of growth were found in the liver, lungs, and abdominal lymphatic glands. Microscopical examination of these deposits revealed a squamous-celled epithelioma, but the central cells of the epithelial processes tended to undergo a granular rather than a keratoid change. Hence there were no cell-nests.

The kidneys, ureters, and bladder were removed and sent to Mr. Targett at the College of Surgeons. He has kindly prepared the subjoined description of these organs.

"The parts submitted for examination consisted of the bladder and kidneys, with the whole length of the ureters. Of these organs the left kidney and corresponding ureter were normal.

"*Right kidney.*—Converted into a thin-walled multilocular cyst by extreme dilatation of the calyces and absorption through pressure of the cortex. The kidney as a whole, while retaining its general outline, was much elongated, so that it measured 6¾ inches in length, after considerable shrinkage from immersion in spirit. The wall of the cyst had an average thickness of an eighth of an inch, and this measurement included the fibrous capsule of the

FIG. 6.

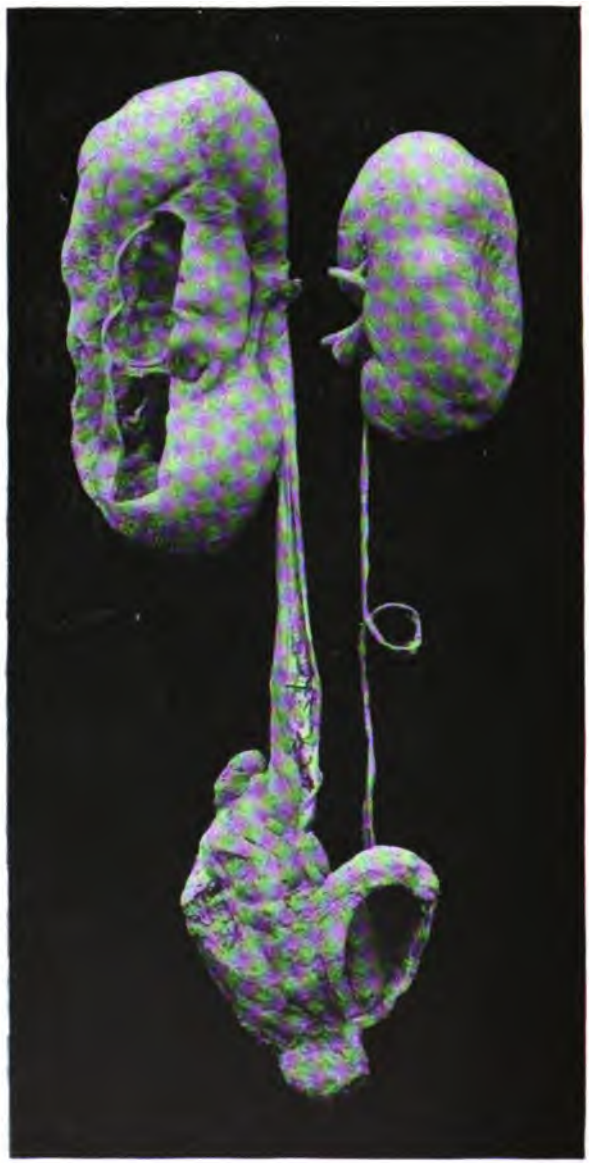

kidney with the lining membrane of the dilated calyx and the entire breadth of the renal parenchyma. So atrophied was this parenchyma that it could only be detected here and there. In contrast with the extreme dilatation of the calyces it is worthy of note that the pelvis of the kidney was barely larger than normal. The hilum and its contents were normal.

"*Right ureter.*—This was fully three inches shorter than its fellow, and markedly dilated, especially in the middle third. The lowest three inches were involved in a large growth behind the bladder, to be subsequently described. The interior of the ureter presented numerous secondary deposits of growth in the mucous membrane, which were arranged in separate nodules or clustered to form prominent ridges. This condition extended to within one inch of the pelvis of the kidney (Fig. 6).

"*Bladder.*—This was for the most part healthy in appearance. Its cavity was small from the action of spirit, but the vesical wall was not hypertrophied nor the mucous membrane thickened. The orifice of the left ureter was normal, and that of its fellow was quite distinct, but through the right orifice protruded a small polypoid tumour the size of a pea. This polypus was made up of a collection of minute warty growths closely applied to one another. Behind the right ureteral orifice and the base of the trigone the mucous surface of the bladder was roughened as if from superficial ulceration. The prostate was normal.

"As previously stated, the right ureter terminated below in an oval tumour situated at the back of the bladder. This tumour measured nearly four inches in its chief diameter, and two inches in thickness. It was firmly attached to the base and posterior surface of the bladder, the peritoneum being partially raised from the bladder in that region. In structure the growth was soft, white, and very friable.

"The relations of the vesiculæ seminales and vasa deferentia were not easily determined, as they all appeared to be more or less invaded by growth. The left vesicula was greatly enlarged, partly by cystic dilatation and partly by a mass of new growth which had formed on its inner (median) side, and was directly continuous with the main tumour. The left vas deferens was embedded in this mass of growth. On the right side the vesicula could not be recognised as such, and the position of the right vas deferens was not certainly made out. Both these organs were involved in the main tumour, and probably infiltrated by it.

"Microscopical sections were prepared from the edge of the neoplasm where it was advancing up the right ureter. These sections showed that the tumour was a squamous-celled epithelioma, and that the muscular coat of the ureter was extensively infiltrated."

From this examination it appeared that the disease began as an epithelioma of the lower end of the right ureter, probably just above the spot where it perforated the muscular coat of the bladder. Thence the growth extended upwards along the ureter, and downwards into the vesical wall, which it invaded without fungating into the cavity of the bladder. Laterally it extended into and absorbed the right vesicula seminalis, and subsequently advanced to the opposite vesicula. If it were contended that the tumour might have originated in the right vesicula, that objection would be met by the structure of the tumour, which was unlike that of a primary carcinoma of the vesicula seminalis. Further, the way in which the right ureter passed into the centre of the tumour, the distension of its calibre by growth, and the infiltration of its wall, were important facts which clearly indicated that the ureter was the primary seat of the disease.

The specimen is preserved in the Museum of the Portsmouth Royal Hospital. *November 19th*, 1895.

---

8. *A case of spontaneous fracture of uric acid calculi.*

By Charles B. Plowright, M.D. (per W. M. Ord, M.D.).

THE spontaneous fracture of calculi in the human bladder is not of very frequent occurrence, but cases every now and again present themselves, and are always interesting, since it seems so contrary to the ordinary sequence of events to find such hard intractable bodies as uric acid calculi falling, so to speak, in pieces of their own accord. Especially so does it strike us who are called upon to crush them artificially, for we know that even when they are caught between the jaws of the lithotrite a considerable amount of force has to be applied before they can be broken. On looking over a fairly extensive collection of calculi, various specimens will probably be found, and it will be evident that spontaneous

fracture has not occurred in all cases in exactly the same way. Various explanations of the phenomena have been suggested, such as the concussion of two or more calculi in the bladder from violent exertion on the part of the patient or from blows or falls, the generation of gas in the interior of the stones, swelling of the nuclei, and the like. In the present case the patient was a man seventy-two years of age, who was admitted into the West Norfolk and Lynn Hospital in the year 1867 with symptoms of stone. He died in the month of April, and the specimens which form the basis of the present communication were removed *post mortem.* They consist of some 240 fragments, weighing 270 grains. Besides these fragments, there were four entire calculi about half an inch in diameter in the act of splitting. Three of these have been cut in halves with a fine saw and the cut surface rubbed smooth upon a hone. Amongst the fragments there are the nuclei of twenty-one calculi, so that each calculus would weigh when entire about 10 or 12 grains.

The reason these specimens have for so long escaped closer attention is a simple one, namely, that they were regarded as being the result of a case of incomplete lithotrity, and with a certain amount of reason, since upon one occasion a lithotrite was passed into the man's bladder and a stone was undoubtedly crushed. At that time I was a pupil of the hospital, and was present at the operation. It will be remembered that in 1867 the operative manipulation in lithotrity was strictly time-limited, two or three minutes being considered as long as it was safe to work with the lithotrite in the bladder for fear of setting up cystitis. Such was the course pursued in this case, but the patient succumbed shortly afterwards. Now, although the operator was skilful and experienced, yet he will hardly lay claim to the ability of crushing twenty-one stones in three or at most four minutes, nor would he be likely to have caught the four other stones, applied to each just enough force to crack them, and leave the fragments *in situ.* I was also present at the *post-mortem,* and distinctly remember the condition of the bladder. The base of the viscus was as unlike what the interior of a bladder usually is as can well be imagined. It was occupied by numerous—ten or twelve—small sacculi, from half to three-quarters of an inch across and about the same in depth. The opening of each sacculus into the bladder was slightly smaller than the body of the pocket, freely admitting the tip of the finger. They

were evidently pouches produced by the mucous membrane bulging, hernia-like, between the reticulated muscular fibres of the bladder. Each pocket held several fragments, some had entire calculi in them, but all were filled to the level of the bladder with muco-purulent urine. Owing to the openings of the pockets being smaller than the pouches themselves, it was found necessary to remove the bladder and turn it inside out into a basin, in order to get all the calculi out. It is obvious that neither the operation of lateral lithotomy nor that of lithotrity would have freed the patient from his disease. His best chance would have been with the supra-pubic, when by turning him on his face and washing out the bladder with a stream of water directed upwards through the wound, many of the fragments might have been got away, but the process would have been tedious and difficult. It has been asserted that with our newly-constructed lithotrites it is hardly possible to catch the mucous membrane, but with such a sacculated bladder as this it would have been hardly possible to catch a stone at all without at the same time catching the delicate walls separating the sacculi.

Externally, the calculi and fragments are of a uniform colour, looking as if they were coated with a layer of pale grey whitewash. On the outside of the larger this is collected into nodular masses, some microscopic in size, others as large as a hemp-seed. These are solid, but there are other rounded elevations of greater dimensions which are hollow beneath. There are others, again, still larger, which are perforated in the centre like volcanic craters. The whitish-grey deposit is freely soluble in caustic potash and insoluble in hydrochloric acid,—at least a fragment kept in the strong acid for a week showed no tendency to disintegrate.

The three divided calculi consist of uric acid, yellowish circumferentially with a large darker nuclear portion. In structure they are very dense, hard, and compact. Many of the fragments are sub-angular segments of spheres, such as Dr. Ord has aptly likened to pieces of an exploded bomb-shell, being convex externally where they correspond to the exterior of the calculus, concave internally where they have been separated from the nucleus, angular laterally where they have been lifted from one another, so that they have a wedge-like or pyramidal contour. In some instances only a few such wedges have been split off from each calculus, leaving the nucleus as a little ball still *in situ;* in other cases the nucleus has fallen away, and remains as a free shot-like body. The outside

of the unbroken calculi is mapped out by slightly elevated ridges indicating the segments into which they are in the process of separating. A section enables us to see how this is being brought about. If this passes through one of the blister-like elevations on the surface of the calculus above referred to, it will be seen that although the outer surface of the blister is smooth, yet the interior of the cavity is lined by an assemblage of rounded nodules or spheres standing side by side, the bases of which are continuous with a greyish white matrix, contrasting strongly in colour with the yellow concentric laminæ of the body of the calculus. In some instances it is evident that this grey matrix has been formed beneath the outer lamina, and as the grey deposit has increased in bulk it has broken away and lifted up the lamina itself, fragments of which rest imbedded in the grey material forming the upper wall of the blister. In fact, the calculus is undergoing a process of disintegration externally, brought about by the deposit of a substance of a very similar composition chemically as the calculus itself, but of a different molecular arrangement. The ridges on the exterior marking out the segments into which the calculi are splitting are also formed of the same grey material; they constitute comparatively thin bridges arching over fissures that extend downwards towards the centre. These bridges vary in height and in width, but on the surface of the calculus they are in all cases considerably wider than the fissure over which they stretch. The grey deposit extends downwards as a thin granular layer upon the fractured surface of the calculus, covering both sides but not filling up the fissure entirely, and it is here in the interior of the calculus that we find its spherical structure best developed. The thickness of this layer varies, but it is always greatest towards the exterior of the calculus just opposite the first or second or third external lamina, from which point it thins off so as to appear in section as a blunt wedge. On its free surface it presents an assemblage of spheres or of bluntly rounded cones or short cylinders, the bases of which become fused into an homogeneous layer applied to the fractured surface of each segment, so that the planes of the two deposits are at right angles to one another. In order to determine the composition of this granular deposit, a minute fragment was chipped off from the segment of the calculus, placed on a microscopic slide, and covered with a thin cover-glass; caustic potash was then run in, and the effect watched under a quarter-inch objective. The

fragment dissolved in a few minutes. A similar fragment was kindly examined by Dr. Ord in the same manner, who used glacial acetic acid, when that very beautiful reaction took place in which the acetic acid gradually broke up the fragment and then caused the deposit of uric acid crystals with lancet-shaped ends, which he has shown[1] takes place when the uric acid is associated with ammonia, so that this grey granular deposit consists of an acid urate of ammonia.

The thick, wedge-shaped mass towards the periphery of the section is evidently the agent that is forcing apart the various segments, and it is here at the most external part of the fissures that the only attachment of the segments exists, in fact each hangs suspended by its external angles like Mahomet's coffin. Some of the fissures have obviously extended from the surface inwards towards the centre, while others have gone in the reverse direction from the centre outwards, as they are wider below than above. The fissures are narrow, and reach inwards as far as the dark nucleus, or, to speak more correctly, the nuclear portion of the calculus from which each segment has been lifted up, the degree of upheaval varying according to the extent to which the disruptive process has gone, but sufficiently far in most cases to allow the insertion of the point of a penknife between the nucleus and the segment. The lower surface of the segments are also covered by the granular deposit, and it is to be found on the nucleus as well.

The manner in which the upheaval of the segments takes place is interesting. A uric acid calculus consists of concentric laminæ differing from one another in colour and varying somewhat in the degree of firmness by which they mutually cohere. But, besides this, there is a tendency to radial cleavage, so that we may regard a spherical calculus as being composed of an assemblage of cones or pyramids having their bases externally and their apices meeting at the nucleus. This is shown by the radial striation figured by Rainey,[2] as well as by the tendency to radial cracking, often seen in museum specimens, from drying. When a stone is crushed by the lithotrite its component parts are separated in both directions concentrically and radially, so that the larger fragments are more or

[1] Ord, W. M., 'Influence of Colloids upon Crystalline Form and Cohesion,' 1879, p. 99.

[2] Rainey, Geo., 'On the Mode of Formation of Shells of Animals by Molecular Cohesion,' 1858, p. 12, fig. 4; p. 58, fig. 4A.

less cuboid in form, but there is also a tendency to the pyramidal contour, most marked, of course, in the largest fragments. In the specimens under consideration the segments have been split off from the calculi by a separation between the pyramids, the force in the first instance acting from the exterior, the inter-pyramidal cleft passing inwards until it comes to a point where the adhesion between concentric laminæ is less strong than the adhesion between the pyramids, so that the force acting along the line of least resistance passes laterally between the concentric laminæ. The direction of the force is, however, influenced by the shape of the wedge, which is an exceedingly blunt one, and acting upon the periphery of the calculus separates the two margins of the fissure, forcing them asunder instead of driving the primary fissure onwards as a thin wedge would. The consequence of this is that after travelling a certain distance, generally less than one third round the calculus, the fissure turns outwards and so reaches the surface again; thus a segment is split off.

The whole process is exactly the same as that by which the trunk of a tree is riven by a hammer and wedge. In fact, the transverse section of an endogenous tree presents many points of similarity to the section of a calculus: the pith corresponds to the nucleus, the bark to the crust, the annular rings to the concentric laminæ, and the medullary rays to the planes of radial cleavage, so that a slice sawn from such a trunk may be employed as an illustration of the phenomenon under consideration. If a wedge be driven from the outside in the direction of the central pith, the log will be split into two halves, provided the wedge has been accurately applied; but if it be only driven in a short distance, it will open a crack wide above but a mere chink below, where it will terminate at one of the annular rings. If the wedge be now pressed sideways parallel to the bark, the crack, instead of increasing downwards, will turn at right angles and follow the direction of the annular rings on the side opposite to that to which the wedge is inclined. If the wedge be further depressed, it will, acting as a lever of the first order, lift out a wedge-shaped piece of wood, a secondary crack passing from the annular ring outwards. This crack will be the converse of the primary, being wider below than above, and is exactly what has happened in the calculus. In the calculus, however, the lateral pressure, by reason of the obtuseness of the wedge, is applied equally to both sides of the primary crack, so that the separation of

the concentric laminæ below often takes place on both sides, although it is more pronounced upon one side than upon the other. When any of the secondary or extrusive fissures reach the surface of the calculus, the wedge-like deposition of the acid urate seems to take place at once, bridging over the crack. At any rate, there are none of the sections without it. Sometimes the granular layer becomes detached from the sides of the segment and remains as a free plate in the fissure. When this happens, the bared surface of the segment soon acquires a fresh coating of granular deposit.

It is evident that the disintegration of these specimens has been caused by pressure from without, by a process of wedging out of the segments, and that the acting agent has been this grey granular deposit of acid urate of ammonia. The same substance which has so evidently lifted up the outer zonal layers of the calculus is responsible for the opening up of the primary or intrusive cracks. In their beginning these were the merest rifts, but the continued aggregation of the deposit soon opened them into sensible fissures, which, by extending inwards in the manner above described, are ultimately responsible for the whole disruptive process. Rainey[1] long ago pointed out, in his work on 'Molecular Coalescence,' the radial striation of the artificial calculi he produced by the action of potassic carbonate on solutions of gum, but he further showed that these artificial calculi tended to disintegrate of their own accord when they were kept in solutions in which the colloid medium was denser than it was in the solution in which the spheres were first deposited.

We have here the probable clue to the case before us. In the man's bladder the pockets in which the calculi were placed were so situated that they never became completely emptied; hence the lower part of the calculi were constantly immersed in muco-purulent urine. The contents of the pouches were stagnant, so that the pus settled to their bottoms and the lower parts of the calculi were therefore bathed in fluid containing a large proportion of colloid, while their upper parts were washed by almost pure urine. Whatever the sacculi may have had to do with the fracture of these calculi, the association of the two conditions is sufficiently close to induce the practical lithotomist to be on his guard when he is called upon to operate on a case of spontaneously fractured calculi.

October 15*th*, 1895.

[1] Rainey, G., loc. cit., pp. 56—58.

9. *Case of congenital deficiency of the abdominal muscles, with dilatation and hypertrophy of the bladder and ureters.*

By Leonard Guthrie, M.D.

History of case.—A male infant, aged 9 weeks, was admitted to Paddington Green Children's Hospital on January 20th, 1896, under the care of my colleague Dr. Sydney Phillips, who has kindly permitted me to record the case. The infant was born at full term, but was weakly at birth, and had wasted rapidly since. A peculiarity about the abdomen had been noticed from the first, and it had remained unaltered in character. The child was extremely puny and emaciated. It was pigeon-breasted, and the costal arch was unusually wide. The movements of the chest wall in respiration were markedly exaggerated. The action of the diaphragm seemed more forcible than usual.

Fig. 7.

The abdomen was generally flaccid, and bulged laterally (Fig. 7). The mid-line corresponding to the position of the recti was marked by a large number of deep vertical grooves in the skin, which could not be smoothed out or obliterated by lateral stretching. Concealed at the bottom of one of these grooves was a white linear cicatrix about half an inch in length. It occupied the normal position of

the umbilicus, and was the only trace left of that orifice. The mother stated that the cord was late in separating, and that when it fell off there was considerable hæmorrhage, which the doctor had to be called in to stop.

Extending from the level of the pubes to that of the umbilical scar could be felt a smooth, ovoid, elastic tumour situated within the abdominal cavity. It was apparently as large as a goose's egg. Shortly after admission the child passed a large quantity of urine, after which it was thought that the tumour had disappeared, and had been merely an ordinarily distended bladder. Some fulness could, however, still be felt below the level of the umbilicus, but this was thought to be formed by the substance of the recti muscles. It was subsequently found, however, that these muscles were absent in this situation, and that the bladder itself had simulated their existence. Outside the area in the mid-line, marked by the longitudinal grooves, there appeared to be little trace of the abdominal muscles. The walls were excessively thin and loose, and seemed to show the convolutions of the intestines clearly beneath them.

The liver, spleen, and kidneys could be easily palpated. The diaphragm could be felt to descend on the finger placed below the ribs. The general appearance of the abdomen is well shown in the accompanying drawing (Fig. 8) made by Mr. G. Lock, house surgeon to the hospital. On either side, slightly above, and in a parallel direction with the assumed position of Poupart's ligament, could be felt a somewhat tense band beneath the abdominal skin. When the child was placed in the erect position the abdominal walls with their contents bulged above this band, forming a kind of double ventral hernia. This condition is not shown in the drawing, which was taken whilst the child was lying down (Fig. 8).

After admission the child continued to waste rapidly, and it died on January 27th of exhaustion. From time to time it passed large quantities of urine, but it was impossible to measure the amount. On several occasions a No. 1 catheter was introduced without difficulty into the bladder, which it appeared to empty. For the last few days of life there was considerable opisthotonos, but no convulsions occurred.

Autopsy (thirty-six hours after death).—Body greatly wasted; appearance of abdomen as during life.

The longitudinal grooves or wrinkles in the mid-line did not disappear, even when the peritoneal cavity was forcibly distended by

air for purposes of dissection. On removing the skin the coverings of the abdomen were found to be almost entirely aponeurotic. Of the recti only the upper two segments as far as the second linea transversa showed muscular fibres. Below this level no trace of

FIG. 8.

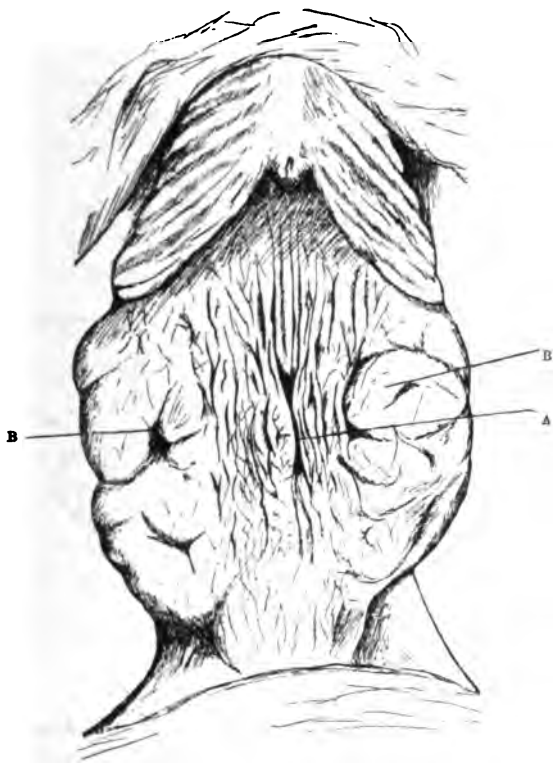

A. Site of umbilical scar. B. Dilated and tortuous ureters resembling coils of intestines beneath the abdominal parietes.

muscle could be discerned. The costal origins of the obliqui and transversalis showed muscular structures for about two fingers' breadth below the ribs. Here they were lost, but reappeared in the iliac regions, forming the tense band noticed above Poupart's ligaments during life. This muscular band was about two inches in breadth, and on careful dissection it was found to be composed of three layers corresponding to the external and internal obliqui and

transversalis. But the latter two muscles only existed as scattered and extremely thin muscular strands. The coverings of the flanks were destitute of muscle until the latissimi dorsi were reached. These were both well developed, as were also the erectores spinæ and other muscles of the back.

FIG. 9.

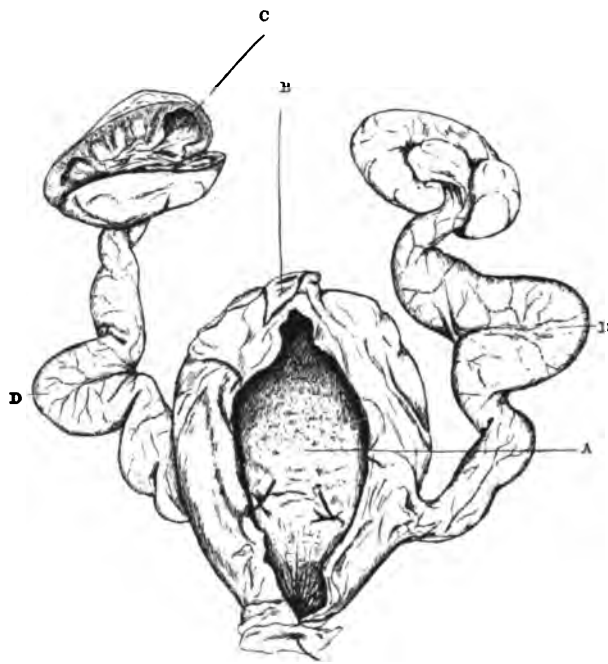

A. Bladder. B. Umbilical cicatrix adherent to summit of bladder. C. Abscess cavity in right kidney. D. Dilated and tortuous ureters.

The quadratus lumborum on each side was normal in origin and insertion, but extremely small and rudimentary. The muscles of the thorax and extremities were fairly well developed.

Urinary organs.—On opening the abdominal cavity the bladder was found high up, with its apex so closely adherent to the inner surface of the scar which marked the site of the umbilicus, that it could not be removed without the scar and adjoining portions of the abdominal skin. It was not adherent to the abdominal wall

below this level. Its walls were from one quarter to half an inch in thickness; its cavity was dilated to the size of a hen's egg. It contained two or three ounces of slightly turbid urine, and when emptied was as large as a goose's egg. The mucous surface was studded with small petechiæ, and was generally congested and inflamed. Between the summit of the bladder and the umbilicus externally there was no trace of the urachus, but the site of the latter, inside the bladder, was marked by a slight dimple or depression.

The right hypogastric artery was very large and tortuous, and pervious throughout the greater portion of its extent. This may have accounted for the hæmorrhage which occurred on separation of the cord.

The ureters were dilated to the size of the small intestines of an adult. They were remarkably tortuous. Each of them was folded on itself about halfway down, the contiguous surfaces of the folds being firmly adherent. They exactly resembled after death, and at first were taken to be, portions of distended small intestine, as they were thought to be when seen through the weakened abdominal walls during life. The orifices of the ureters into the bladder admitted a blow-pipe with ease, and the ureters were not obstructed elsewhere. There was no stricture of the urethra, and no phimosis.

The kidneys were not enlarged, and appeared normal externally, but on section they were found to be much inflamed. They showed scattered patches of purple congestion amongst the pyramids, with here and there beads of pus. The right was more affected than the left, and contained a ragged pea-sized abscess in its lower extremity. The left pelvis was more distended than the right, but not apparently inflamed (see Fig. 9).

Liver and spleen normal, but freely moveable. *Intestines, heart, and lungs* normal. No Meckel's diverticulum. *Diaphragm* well developed.

Remarks.—Cases of congenital deficiency of the pectorales, sterno-mastoidei, and some other muscles are not rare, but with the exception of Mr. R. W. Parker's case described in the 'Transactions' of the Clinical Society (vol. xxviii, p. 201) I have not been able to discover another instance in which absence of the abdominal muscles has been recorded.

Mr. Parker's case strongly resembles the present. In both of them there was deficiency of similar muscles.[1] In both cases there

[1] Mr. Parker informs me that on microscopical examination of the

was a hypertrophied bladder occupying the fœtal position high up in the abdomen; and in both there was great dilatation of the ureters without obstruction of their orifices into the bladder, and without stricture of the urethra or phimosis. In Mr. Parker's case the bladder was closely attached to the wall of the rectum at the apex of the trigone. In my own case the summit of the bladder was firmly adherent to the umbilical scar.

The association in two cases of deficiency of the abdominal muscles with a hypertrophied bladder occupying the fœtal or abdominal position, and accompanied by dilatation of the ureters, cannot be a mere coincidence. The muscular deficiency of the abdominal wall and the high position of the bladder are alike dependent on arrest of development during intra-uterine life.[1] But the hypertrophy of the bladder and dilatation of the ureters are purely secondary and morbid conditions.

In my own case the bladder, being firmly connected with the umbilical cicatrix, has been unable to contract downwards and thus to empty itself completely. In its efforts to do so it has become hypertrophied and dilated; urine has accumulated, causing backward pressure in the ureters, and has led to their dilatation. There is no obstruction to the outlet of the bladder which would otherwise account for the condition.

In Mr. Parker's case no mention is made of the urachus, but since the bladder was placed high up in the abdomen, as in my case, the probability is that in his also there was shortening of the urachus, and thus the same sequence of events occurred. The adhesion of the bladder to the rectum at the site of the trigone may also have contributed towards this difficulty in complete evacuation.

The longitudinal wrinkles present in my case in the mid-abdominal lines may have been produced by the constant traction of the bladder upon these parts in its effort at evacuation. It was thought during life that they might have been due to subsequent contraction of the skin after distension produced by ascites *in utero*, or hydronephrosis; but the necropsy revealed no signs of disease such

abdominal walls in his case, no trace of muscular structure was found at the sites where it was apparently absent, thus proving that the muscles were actually not developed, and not merely atrophied.

[1] "In the fœtus the bladder is placed on the anterior wall of the abdomen, and it is not until the pelvic cavity develops that the organ sinks from its earlier place" (Macalister's 'Anatomy,' p. 385).

as would have produced intra-uterine ascites, and there was no hydronephrosis.[1]

I have to express my thanks to Mr. G. Lock for his excellent drawings of the case, and also to Mr. Stroud Hosford, senior house surgeon at the North-West London Hospital, for valuable assistance in the dissection. *February 4th*, 1896.

---

10. *Case of lymph-scrotum.*

By JOHNSON SMITH.

[With Plate III.]

HISTORY.—An ordinary seaman, aged 21, was admitted into the Seamen's Hospital, Greenwich, on April 7th, 1896, with inguinal swellings, and enlargement and tenderness of the scrotum. The patient was born in London, his parents were both English, and he was taken abroad at the age of twelve months. He first lived in Antigua for three years, then for the next eight years in Trinidad. When twelve years old he went to sea, and has followed the calling of a seaman up to the time of his admission. He has noticed slight swellings in the groins since childhood. During the past five years these have increased rather rapidly in size, and for some months have caused much pain and inconvenience. Since 1892 he has been troubled during the hot months of each year (July and August) by an irritating discharge of yellow fluid from the surface of the scrotum.

At the time of his admission, though not a well-developed or very muscular man, he seemed to be in good general health. He com-

[1] Dr. Dawson Williams ('Trans. Path. Soc.,' vol. xxxix, p. 152) has described as "congenital hydronephrosis" a case which may have some bearing on these. His patient, a boy aged 5½ years, was admitted to hospital with symptoms of uræmia. He died some weeks later, and after death the bladder was found to be greatly dilated and hypertrophied, and the ureters were dilated to the size of the ileum. The kidneys were enlarged, and their pelves presented the appearance of having been much distended. There was no obstruction to the outlet of the bladder or to the inlet of the ureters into the bladder. No mention is made of the urachus.

plained much of a dull pain in each groin, and of tenderness of the testes and scrotum. When standing up he presented in each groin a prominent swelling which was very soft and compressible, and felt like a large vascular growth (Plate III). That on the right side was the more prominent one, whilst that on the left covered a larger area, spreading over the saphenous opening. Each of these swellings disappeared almost entirely after the patient had rested on his back for a short time, but returned at once when he stood up, and then soon enlarged to such an extent as to cause much uneasiness and a painful sensation of fulness. There was no marked impulse on coughing. The scrotum was much swollen, the right half being larger and more pendulous than the left. The epidermis was rough and thickened, but not nodulated. The cord on each side was much swollen, and both testes were also slightly enlarged. There was extreme tenderness of the surface of the scrotum, and much pain was caused by even slight compression of the testes and cord.

On microscopical examination of the blood, living and very active specimens of filaria were almost invariably found in drops taken after 6 p.m. The blood taken by puncture in the daytime seemed to be quite free, but in small quantities taken from spurting arteries during an operation for the removal of one of the inguinal swellings and a portion of the scrotum on the afternoon of April 28th, some few of the embryo worms were found in a living state.

May 19*th*, 1896.

---

11. *Diffuse interstitial syphilitic orchitis.*

By H. Betham Robinson, M.S.

The child from whom the specimen was taken, was brought to me at the Children's Hospital, Shadwell, on May 1st, 1894, aged 10 weeks. He was said to have snuffled at birth, and his scrotum was then enlarged. At five weeks a rash over the buttocks was noticed, which afterwards came on the hands and feet.

On examination he had a very marked "old man" appearance, with skin shrivelled and wasting. There was fissuring at the angles of the mouth and sores about the face and buttocks. He had a

DESCRIPTION OF PLATE III.

Illustrating Mr. Johnson Smith's paper on "A Case of Lymph-scrotum." (Page 145.)

It represents a lobulated swelling in each groin, and considerable enlargement of the scrotum.

From a photograph.

PLATE III.

hydrocele on the right side, and both testes were of stony hardness, enlarged but quite smooth.

He was one of seven children, six of whom were dead; five of these were said to have died of teething, and one from diphtheria. They all snuffled. The mother had had one miscarriage.

During the month he did not improve; there was more wasting, and the ulceration round the mouth had increased. His soles and palms were peeling. His testicles were about the same in size. He was admitted into the hospital on June 5th, and improved considerably for a time under mercurial treatment. In the middle of July he had a severe attack of diarrhœa, to which he succumbed.

The testicles, on removal, proved to be both uniformly enlarged, smooth on the surface, and much firmer than normal. There was some fluid in both vaginal sacs.

Histologically there is very marked thickening of the tunica albuginea and of the septa. Instead of the loose areolar structure usually seen surrounding the tubes, we have a diffuse cellular infiltration arranged generally in circles around the tubes. In some places this may be seen to have developed into laminæ of firm fibrous tissue, with almost complete dwindling of the glandular structure from compression. The vessels are in parts abnormally enlarged. In the epididymis the same change is to be seen; the increase of fibrous tissue is even more developed than in the testis. The change is evidently one of a diffuse fibrosis throughout the gland and epididymis.

The above described condition, to which attention was first drawn by Virchow, seems in this case to be occurring very early. Dr. Wilks[1] brought a similar case before this Society in 1865, in which the disease was present in a child of five months, who ultimately recovered. This interstitial form has been of late years observed frequently in older children. As recovery is usual, I have taken the opportunity afforded by this fatal case of showing undoubted specimens to the Society. *March 3rd*, 1896.

[1] 'Trans. Path. Soc.,' vol. xvi, p. 189.

12. *A dermoid tumour of the testis.*

By J. Jackson Clarke, M.B.

The description I have given in the Catalogue of St. Mary's Hospital Museum of the specimen to which the following remarks relate is as follows:

"A right testis containing a dermoid cyst, which is everywhere surrounded by the tunica albuginea. The interior of the cyst is occupied by a central projection, which is attached by a broad pedicle in which are some small cystic spaces. The tumour is about the size of the adult testis. Examined with the microscope, the tunica albuginea stretched over the testis was found to be normal in its structure. The wall of the cyst consists of dermal elements, and the intra-cystic projection is covered by skin containing hair-follicles, sebaceous and sweat glands. The cystic structures at the attachment of the intra-cystic projection appear to be remains of the epididymis. No remains of the tubules of the testis could be found in the loose tissue which occupies the space between the tunica albuginea and the wall of the dermoid." The specimen was presented to the museum by Surgeon-General Giles, who removed it in India from a child aged one year.

Remarks.—A specimen which appears to have resembled this is described in the 'Trans. Path. Soc.,' 1887, vol. xxxviii, p. 224, by D'Arcy Power. "The tumour was everywhere enclosed by the tunica vaginalis." In English surgical literature, Jacobson,[1] speaking of the more complicated forms of dermoid tumours, writes: "The cyst appears often to be outside the testicle itself, adhering to the tunica vaginalis near the junction of the testicle and epididymis. But though apparently separated, the connection between the cyst and the testicle is usually, in reality, close and intimate." This would apply to dermoids differing slightly in their relations from that described by D'Arcy Power and from the present specimen.

Lannelongue and Achard ('Kystes Congenitaux,' 1886, p. 41) appear to consider scrotal dermoids in the male to be homologous with those of the ovary in the female. They have written: "Though these tumours almost always appear to be independent of

[1] 'Diseases of Male Generative Organs,' 1893, p. 429.

the parenchyma of the testis, they have, in most instances at least, intimate relations with this gland. In the majority of cases when these relations are definite, the tumour is found to lie between the tunica vaginalis and the testis, to which the cyst is attached by more or less loose connective tissue. Occasionally the tumour is attached to the integuments; but in that case the adherence is explicable as the result of inflammation, suppuration, and the formation of fistulæ." In support of this view they quote Velpeau and Bœckel. The same authors, in their "Index bibliographique" (ibid., p. 249), give a list of twenty-three cases of scrotal dermoids published between the years 1679 and 1884. In the majority of the cases cited, cartilage and bone appear to have been encountered. The more ancient observers saw in the osseous parts of these tumours definite parts of the skeleton, such as ribs, orbits, femora, &c. Nerve-fibres and ganglia have been described in more recent cases.

In discussing the pathogenesis of ovarian dermoids ('Diplogenèse par Inclusion'), Lannelongue and Achard (ibid., p. 127), adopting the view of Is. Geoffroy St. Hilaire (1850) (the inclusion theory), write: "An accident of development determines the inclusion of part of the epiblast in the rudiment of the Wolffian bodies, whilst the latter are still close to the ectoderm, that is in the early period of embryonic life. With some of the component elements of other parts of the embryo, for instance, some of the protovertebræ, or even some of the hypoblast, may be involved with the epiblastic tissue in the inclusion within the Wolffian body, since the parts are still rudimentary and packed within a small space, so that they are more likely to be involved simultaneously in the same error of development." This applies only to complex dermoids. Is. Geoffroy St. Hilaire admitted the possibility of superficial origin of some kinds of dermoids.

The authors recognise that such arguments are merely hypothetical. The scrotal tumours were regarded by some (Cruveilhier, Igokalski, Pigné) as always of subcutaneous origin, whilst others regarded them as arising within the testis, and descending with the latter from the abdomen into the scrotum. Others, again, thought both modes of origin obtained in different cases. Lannelongue and Achard consider it probable that all scrotal dermoids are homologous in their origin with those of the ovary, and they base this opinion chiefly on two cases: first, that of Prochaska, in which a dermoid was found in connection with an ectopic testis; and, secondly, that

of Panu, who found in an animal an abdominal testis containing a dermoid tumour.

Bland Sutton ('Tumours,' 1893, p. 382) inclines to the opposite view, recalling that of Lebert in 1852 (see Lannelongue, ibid., p. 98.) "There are a good many reasons for believing that the majority of dermoids reported as arising in the testicles were really scrotal in origin." Sutton appears to refer ovarian dermoids to the Graafian follicles as the place of their origin, explaining the dermal structures by a transmutation of mucous membrane into skin.

In the specimen which I have described above, the tumour lies entirely within the tunica albuginea, and so must be regarded as homologous with an ovarian dermoid, whatever the real origin of the latter may be. It is the only specimen that has come under my observation, and in so far supports the view expressed by D'Arcy Power to the effect that scrotal dermoids are rare ('Trans. Path. Soc.,' 1887, vol. xxxviii, p. 224). *November 5th*, 1895.

---

13. *Malignant tumour of the spermatic cord (carcinoma ?).*

By John H. Morgan.

The tumour was removed by operation from a man aged 39. Previously healthy, he first observed the swelling ten weeks before admission, subsequent to a strain due to slipping on a piece of orange peel, which caused some pain in the hip and back.

At first no pain was noticed in the swelling, but subsequently there was a small amount after long standing.

On admission to Charing Cross Hospital there was a large swelling in the left inguinal region, parallel with Poupart's ligament, lying above and internal to it, and approaching the mid-line. It was wider above than below, and about 2½ inches broad at its centre. Its length was about 5 inches, extending about 1½ inches above the middle of Poupart's ligament, and projecting below about 1 inch outside the external abdominal ring downwards into the scrotum. This lower end was very clearly defined, projecting like the terminal phalanx of an index finger, and free from attachments. The upper end was also sharply defined, but wider and deeply

attached. The limits on the outer and inner margins were also definite. There was no redness or heat, and the skin over it was normal and freely moveable. The tumour was exceedingly hard, giving the idea of an enchondroma. Palpation gave no pain, and no fluctuation could be detected. When the spermatic cord was pulled upon, the tumour moved to a small extent.

The left spermatic cord was normal at its lower part, below the tumour, and the left testis was more flabby than its fellow.

Neither before nor after the appearance of the tumour had the patient any trouble with his urine or bowels.

The tumour, together with the testis, was removed by an incision over the inguinal canal, and prolonged into the scrotum. The external oblique was cut through, and the tumour exposed. It was attached to the spermatic cord, which was ligatured and divided at a point which appeared free from disease. A portion of the external oblique which was adherent to the growth was removed with it. No glandular involvement could be detected.

The patient recovered, and left the hospital at the end of a month with the wound closed.

Dr. Hunter reports that attached to the spermatic cord in front is a sausage-shaped tumour, measuring 4 inches in its long diameter and 1½ inches through its upper end, where it lay within the inguinal canal. The part in the scrotum is rounded and smooth lower down, where it was free. The mass is firm in consistence, and presents on section a spongy appearance. At the upper part the spermatic cord occupies a groove in the posterior aspect of the tumour. Lower down it blends with the more rounded mass of the tumour. The growth affects only the portion of cord containing the blood-vessels. The vas deferens, although running in a deep groove at the back of the tumour, is found, on dissection, to be only embedded in it. The testis and epididymis are not affected. Microscopically, the tumour is found to be a spheroidal-celled cancer, the cells occupying the meshes of a trabecular network. The thickening of the cord is due to extensive infiltration of lymphatics with cancer cells.

The tumour appears to have arisen somewhere within the inguinal canal, and to have extended downwards along the cord, affecting the latter secondarily.

Remarks.—In the 'Transactions' of the Society there are only two cases of tumours arising from the cord of an adult recorded, and

neither has a close analogy to the one presented this evening. One was exhibited by Mr. Pepper, from a man aged seventy-five, which had been observed for ten months, and had arisen in the near proximity of the testis, but had not apparently sprung from it or from the cord, which were both readily separable from it. The microscope showed it to be a sarcoma with some admixture of cartilage cells. The second specimen was shown by Mr. Mansell Moullin, and was a spindle-celled sarcoma of rapid growth removed from a patient aged thirty-two, but its exact origin was not described. A specimen of myxo-fibroma from a healthy man of forty-five, which had been observed for three months only, was exhibited by Mr. Gay. Beyond these, and two specimens in the Museum of the Royal College of Surgeons, in each of which the testis is unaffected, and one described by Mr. Spence, of Edinburgh, I can find no record of any specimens which at all resemble that now exhibited to the Society. *March 3rd*, 1896.

Report of the Morbid Growths Committee on Mr. Morgan's specimen of malignant tumour of the spermatic cord.—We are of opinion that this tumour has the structure of a carcinoma. The individual cancer cells are large and polyhedral, but the growth is not a columnar-celled carcinoma, such as might have originated from a vas aberrans. We can merely suggest that it is an endothelioma arising in connection with the peritoneum.

W. G. Spencer.
J. H. Targett.
S. G. Shattock (*Chairman*).

---

14. *Case of glandular enlargement of the prostate; excision of both testicles eight months before death.*

By N. Davies-Colley.

The patient from whom this specimen was taken was a man aged 73, who was admitted into Guy's Hospital under my care in October, 1895.

He had suffered from frequency and occasional difficulty of micturition for four years. In July, 1894, he had been for a short time in the hospital with retention of urine from enlargement of the prostate. This was relieved by catheterisation, and the cystitis from which he was then suffering was also considerably diminished.

In the March of last year he again suffered from difficulty of micturition, and he had to come in a second time with acute retention. The bladder was aspirated by a supra-pubic puncture, and the next day I introduced a catheter under chloroform. The urine was alkaline, and contained phosphatic deposit. The condition of his bladder improved under treatment, but his rest was continually broken by the necessity of micturating eight or nine times in the night.

On April 16th, 1895, both testicles were removed. At the same time I examined the prostate, which I estimated to be 2½ inches broad, and 2 inches from above downwards, that is, in the line of the prostatic urethra. The projection into the rectum I set down as an inch in elevation. The swelling was firm and smooth like an orange, and I could not say that any portion was enlarged more than the rest.

Healing took place rapidly. Two days after the operation he was quite comfortable, and had only needed to pass water three times during the previous night. A month after the operation he was discharged. He was then free from cystitis, and was able to pass his water without difficulty. *Per rectum*, however, I could detect little if any improvement in the condition of the prostate. A month later the frequency of micturition and some cystitis had reappeared. When he was again admitted under me in October, he complained that he had to pass water nine or ten times every night. I found four ounces of clear residual urine in his bladder. The prostate was, as far as I could judge, in the same state as before. He could not bear the daily introduction of instruments, so a gum-elastic catheter was tied in. This gave him for some time great relief. He then began to suffer from fever and bronchitis, and finally sank on December 20th, 1895. His death was found to be due to extensive pyelonephritis.

The bladder was small and thick-walled, its mucous membrane being acutely inflamed. The prostate was firm and smooth externally, measuring 2½ inches in breadth by 2 inches in depth and from before backwards. The enlargement was chiefly due to hypertrophy

of the right lobe, which, besides forming a considerable diffused projection into the bladder, had pushed the prostatic urethra to the left.

The verumontanum could hardly be made out, and the openings of the ejaculatory ducts were not visible. There was no stricture of the urethra.

I am indebted to Mr. Targett for the following account of the microscopic examination of sections taken from "widely different parts of the prostatic tumour."

"Both pieces show a considerable amount of glandular tissue, the acini of which are distended with shed epithelium. Some of the ducts are obviously dilated. The hypertrophy, therefore, is largely adenomatous."

Remarks.—The chief interest of the case lies in the absence of any change in the size of the prostate during the eight months which followed castration.

The measurements made *post mortem* are the same as those which I wrote down on the day of the operation. At the same time it is interesting to observe that for a time the patient's condition was considerably improved by the removal of his testicles.

February 4th, 1896.

---

15. *Carcinoma of the prostate.* (*Card specimen.*)

By R. G. Hebb, M.D.

The specimen came from a man aged 55, the principal symptoms being difficult and painful micturition. The prostate is scarcely if at all, enlarged, and though harder than normal, it is not markedly indurated. There is hypertrophy of the bladder, and cystitis, with a patch of sloughing.

There are no extensions of the growth, and no metastatic deposits.

Microscopically the prostatic tissue is infiltrated with cubical or stumpy epithelioid cells. The cell nucleus is large, and the cytoplasm tenuous. There are no degenerative appearances.

In many places there is a distinctly gland-like arrangement of the neoplastic cells.

April 21st, 1896.

16. *Diverticula of the bladder, associated with vesical growths.*

By J. H. Targett, M.S.

[With Plates IV, V, VI.]

The object of this paper is to describe a remarkable series of cystic tumours of the urinary bladder, associated with or dependent upon the presence of malignant and other forms of new growth in that viscus. Three specimens will be described in detail, and notes of other preparations preserved in the London museums will be added. The probable explanation of these different forms of cystic tumour must then be attempted, and their pathological bearings discussed.

Case 1 (Preparation in Guy's Hospital Museum).—A man, aged 63, was admitted to a hospital for hæmaturia. He had always enjoyed good health until the onset of his present illness, though he had been troubled with a double inguinal hernia for the last ten years. Four months before admission he began to pass blood at intervals, and continued to do so until he came under observation. There was occasional pain, especially before micturition.

On admission.—The urine was of a smoky red colour, with an abundant deposit consisting of blood-clots and pus. Reaction neutral; no sugar; albumen in large quantity (14 grammes to the litre). Under the microscope blood and pus cells were seen in abundance, also triple phosphate crystals, but no particles of growth.

During micturition it was noted that the patient first passed urine tinged with blood, then one or two blood-clots, and finally clear urine, or urine mingled with pus. The pain amounted to an aching in the hypogastric region when the bladder was full, which was relieved by micturition; and there was usually a sharp pain at the cessation of the flow. Abdominal palpation revealed a swelling above the pubes to the left of the middle line, which extended upwards nearly halfway to the umbilicus. Both lobes of the prostate were enlarged. Nothing abnormal was detected by sounding.

On the third morning, as the patient was passing almost pure

blood, an unsuccessful attempt was made to wash out the bladder. The following day he died quite suddenly, while conversing with his friends.

Post-mortem examination.—When the abdomen was opened, some old adhesions were observed between some of the coils of the small intestine; the large sacs of the inguinal herniæ were empty on each side. Occupying the position of the bladder was a somewhat bilobed mass, the left lobe of which extended about 3 inches above the level of the symphysis pubis, while the top of the right lobe was slightly below that line. It was afterwards shown that the latter represented the true vesical cavity, and the left lobe was formed of a large cyst, communicating with the bladder. In the line of constriction, which gave an hour-glass appearance to the outline of the viscus, a new growth was situated involving the lower end of the left ureter.

The right kidney was enlarged, and presented lines and foci of suppuration in the cortical substance; the pelvis and ureter were markedly injected, but not dilated. Subsequent dissection showed that the right ureter opened freely into the bladder. The left kidney was smaller than its fellow, yet its pelvis was considerably enlarged, and the corresponding ureter was dilated to the size of the little finger owing to obstruction of the vesical extremity. On section the glandular tissue was much wasted from interstitial nephritis, but there were no abscesses in the cortex, and the lining membrane of the pelvis was not inflamed. The prostate was moderately enlarged, notably the central lobe; otherwise healthy. The heart weighed 11 oz. The coronary arteries were exceedingly atheromatous, but no fibroid degeneration was discovered in the muscular tissue of the organ. Aortic and mitral valves thickened. Other viscera normal.

Description of the preparation (Plate IV, fig. A).—The specimen consists of a moderately hypertrophied urinary bladder with an enlarged prostate. A thick mass of new growth, having a shaggy and villous surface, occupies the whole of the left lateral wall of the bladder, and extends to the anterior wall of the organ. Immediately to the left of the bladder is a large, smooth-walled cyst, 5½ inches in its chief diameter, and nearly 3 inches in the shorter measurements. This cyst is firmly attached to the left wall of the bladder, the area of attachment corresponding with that of the vesical growth; its cavity is even larger than that of the bladder,

DESCRIPTION OF PLATE IV.

Illustrating Mr. Targett's paper on "Diverticula of the Bladder associated with Vesical Growths." (Page 155.)

Fig. A is from a photograph of a preparation in Guy's Hospital Museum. See description on p. 156. The orifice of the right ureter is marked with a black rod.

Fig. B is from a photograph of a preparation in the Royal College of Surgeons Museum. See description on p. 162.

Fig. C represents the right lateral aspect of the preceding preparation. The position of the right vas deferens upon the diverticulum is indicated by rods placed beneath it. The corresponding vesicula seminalis and ureter are displayed.

Fig. C.

Fig. B.

Fig. A.

with which it communicates by a ragged opening in the middle of the growth. The partition between the two cavities measures 1¾ inches thick, and seems entirely formed by the neoplasm. The posterior and superior surfaces of the cyst are covered with peritoneum which has been stripped off from the left side of the bladder and pelvic cavity. In like manner the left ureter, left vas deferens, and left vesicula seminalis have all been stripped off the bladder by the formation of the cyst, and lie upon its posterior wall. A transverse section through the tumour exhibits an extension of the growth upon the inner surface of the cyst-wall. Within the cyst it may be noted that the growth has a shaggy surface, and a raised everted margin precisely similar to that in the bladder.

The left ureter is considerably dilated, owing to the obstruction of its orifice by the tumour which invades it. The right ureteral orifice is quite free. The vesical mucous membrane away from the growth is not pigmented, and shows no signs of chronic cystitis, but in the recent state the bladder was full of the most tenacious mucopus, and its lining was injected.

Histologically the tumour is a squamous-celled epithelioma. The wall of the cyst is composed of wavy bundles of fibrous tissue, much condensed, and has *no* lining of mucous membrane. Examination of different parts of the wall leaves it doubtful whether any unstriped muscle fibres are mingled with the fibrous tissue, but the absence of mucous membrane is quite definite.

Remarks.—The mode of formation of this cyst is a question of much interest. That the cavity has originated beneath the recto-vesical fascia is certain, because the left vas deferens and vesicula seminalis have been stripped from their connections with the bladder, and lie upon the wall of the cyst.

I have previously demonstrated the fact[1] that the well-known pelvic hydatid cyst which is usually placed between the bladder and the rectum, takes its origin in the loose cellular tissue between the muscular coat of the bladder and its sheath of recto-vesical fascia. In consequence of this situation the gradual enlargement of the hydatid cyst displaces the vas and vesicula seminalis from the bladder, owing to their close union with the recto-vesical fascia. These organs, therefore, rest ultimately on the wall of the hydatid cyst, and not on the wall of the bladder. Further, the recto-vesical fascia

[1] 'Trans. Path. Soc.,' 1891, vol. xlii, p. 203; 'Brit. Med. Journ.,' 1893, vol. ii, p. 218; and 'Proc. Roy. Med. Chir. Soc.,' 3rd S., vol. vii, p. 129, 1895.

can be readily separated from the muscular coat of the bladder by a simple experiment. For these reasons we are justified in believing that the cystic tumour now under consideration has originated from the bladder, and gradually pushed back the recto-vesical fascia on the left side, carrying with it the left vas deferens and vesicula seminalis. Hence the accidental communication of any adventitious paravesical cyst or cavity with the bladder itself is definitely excluded. The two most probable explanations of the nature of this vesical cyst are:—1. That the cyst has begun as a diverticulum or sacculus proceeding from the vesical wall. 2. That the space was first formed beneath the recto-vesical fascia in association with or as a consequence of the malignant disease, and that it underwent secondary changes whereby it was converted into its present form. The former explanation must be considered first, inasmuch as it is the easier and confessedly the more probable.

Large lateral diverticula of the bladder are well known. They begin usually as herniæ or pouches of the mucous coat in the vicinity of the orifices of the ureters, and in the course of formation obtain a more or less complete covering of muscular tissue from the wall of the bladder. When the cyst attains a large size it is not always easy to demonstrate the presence of muscle-fibres. They probably disappear or are thrust aside by the distending pouch. Under such circumstances the wall of the diverticulum will consist of mucous membrane, and a tough layer of fibrous material derived from the cellular tissues around the bladder. The points in favour of regarding this specimen as a diverticulum of the mucous coat are its situation and smooth interior. But, on the other hand, the tumour has stripped off the recto-vesical fascia in a manner quite unlike the behaviour of the common diverticulum. There is microscopical evidence that the cyst does not possess a mucous coat, and it is also very doubtful if muscular tissue exists in the wall. My own view of its development may be stated thus: The cavity or space alongside of the bladder is due to distension of the recto-vesical fascia by fluid accumulating between it and the muscular coat of the bladder. In consequence of the epitheliomatous growth, the vesical wall has become infiltrated, ulcerated, and ultimately perforated, thus permitting the extravasation of foul urine outside the bladder, but within the recto-vesical sheath. This extravasation would be much aided by the high intra-vesical tension which existed, as shown by the enlarged middle and lateral lobes of

the prostate, the hypertrophied bladder, the dilated right ureter, which was not involved in the growth, and lastly by the very large inguinal hernia on both sides of the body.

The condition of the kidneys is worthy of remark in passing. The right kidney exhibited the usual features of ascending pyelo-nephritis in addition to those due to backward pressure from enlarged prostate. But on the left side, though the obstructive effects on the kidney were more marked, yet there was a complete absence of acute inflammatory changes, because infective organisms were prevented from entering the ureter. The lower end of the left ureter must have been virtually occluded by the surrounding malignant growth. Indirectly, therefore, the specimen bears testimony to the truth of the view that the infective process in the so-called " urgical kidney" travels from the bladder by way of the ureter.

Case 2.—The specimen from this case was presented to the Royal College of Surgeons Museum by Mr. Hurry Fenwick, and I am indebted to him for his kind permission to make use of it. The parts consist of a male urinary bladder and a large cyst attached to its apex (Plate V, fig. B).

The *bladder* is much dilated, and its wall is generally hypertrophied, sacculated, and fasciculated. The inner surface of the entire right half of the vesical cavity is affected with a flat ulcerated new growth. This growth, however, is not limited to the right half, but extends beyond the median line upon the anterior wall of the bladder, and involves the base with the trigone as far as the *left* ureteral orifice. Further, three or four discrete nodules of growth, one third of an inch in diameter, are seen upon the left lateral wall of the bladder. Hence the amount of mucous surface unaffected by the neoplasm is comparatively small. The firmer parts of the growth present the naked-eye and microscopical features of a squamous-celled epithelioma. It has a raised, everted, overhanging edge, and a depressed nodular centre. Upon the right lateral wall, where the growth appears to be of oldest date, the surface is deeply excavated by sloughing, and the muscular coat extensively invaded. At the trigone and base of the bladder the appearance of the growth suggests that it began as a series of separate deposits in the mucous coat, which ultimately coalesced. Hence the epithelioma has here a well-marked sinuous outline.

The *prostate* is moderately hypertrophied, especially as regards its

median lobe. This projects into the vesical cavity as a pyriform swelling, the surface of which is much ulcerated, if not actually invaded by the epitheliomatous growth in the bladder.

The *vesiculæ seminales* and vasa deferentia are healthy, but were surrounded by much dense tissue consisting of inflammatory material, and deposits of growth in the lymphatics. This was particularly the case on the right side, where the lymphatic glands, extending from the bladder along the right internal iliac vessels, showed extensive infiltration with secondary deposits of epithelioma. The *rectum* was normal, but two or three nodules of growth were found in the peritoneum at the bottom of the recto-vesical pouch. The peritoneal coat on the posterior wall of the bladder is unevenly raised by deposits of growth beneath it.

The *ureters* are much dilated on both sides, the right being somewhat the larger, and their vesical orifices are surrounded with growth. It is clear that the obstruction is due to pressure from without upon the walls of the ureters.

The *cyst* is placed at the summit of the bladder, and has the following boundaries and measurements. After immersion in spirit it measures 3¼ inches from above downwards, 3 inches from side to side, and 2 inches from before backwards. In front it is bounded by the recti abdominis muscles, and their fibrous sheaths, together with a layer of fatty tissue. Posteriorly the wall of the cyst appears to be formed out of a piece of great omentum, but further examination shows that this omentum is firmly adherent to the peritoneum detached from the deep surface of the anterior abdominal wall. The upper limit of the cyst is completed by the junction of its anterior and posterior walls, and has a mass of great omentum attached to it. Lastly, the base or inferior limit is formed partly by the fundus of the bladder, and is partly occupied by a wide aperture, through which the cyst communicates with the interior of the bladder. The inner surface of the cyst is smooth and white, but has no definite lining membrane (Plate V, fig. B).

The aperture of communication with the bladder is placed to the right of the median line, and involves practically the right half of the fundus of the bladder. It is oval in shape, two inches in its chief diameter, and transversely placed. The margins of the aperture are covered with projecting masses of growth, which diminish its calibre, and by protruding towards the cavity of the cyst must have tended to close the aperture like a valve.

DESCRIPTION OF PLATE V.

Illustrating Mr. Targett's papers on "Sarcomata of the Bladder and their Classification" (page 291); and on "Diverticula of the Bladder associated with Vesical Growths." (Page 155.)

FIG. A is from a photograph of a preparation in Guy's Hospital Museum. It represents the left half of a bladder extensively affected with sarcoma. See description on p. 299.

FIG. B is from a photograph of a preparation in the Royal College of Surgeons Museum. It depicts a large cyst communicating with the bladder at its apex. See description on p. 159.

Fig. A.

Fig. B.

Fig. A

Fig. B.

Remarks.—Before discussing the nature of this cyst, the following points in the clinical history must be considered. The patient was a man aged 62. Two years before death he had a sudden discharge of foul pus in the urine, and it was thought probable that he had a sacculus of the bladder, especially as the median lobe of the prostate was enlarged. He was at once catheterised, and continued the use of the instrument up till the time of death. The cyst displayed in the preparation formed very rapidly, and presented itself clinically as a swelling the size of an ostrich egg in the supra-pubic region. This occurred about three months before death. The swelling was painless, and was not diminished by the use of the catheter. Moreover, no rise of temperature or rigors had been noticed. At the *autopsy* the cyst was found full of pus and urine, and the aperture leading from it into the bladder was blocked with masses of an epitheliomatous growth.

On comparing the anatomical characters of this vesical cyst with those of the preceding case, it will be noted that, except for the situation of the cyst, there is a very close resemblance between the two specimens. That being so, it is natural to suppose that they have been formed in the same way. In spite of the clinical history, which points to the existence of an apical diverticulum or sacculus of the vesical wall, I venture to think that the cyst seen in this specimen is not a true sacculus, or at least not in its entirety. There is no proper lining membrane to any part of the cyst-wall, and the irregular outline and thinning of that wall is unlike the usual structure of a sacculus. There can be little doubt that the cyst is really secondary to the epithelioma, as in the preceding instance. The wall of the bladder at the apex becomes weakened by infiltration with the new growth, and in course of time destroyed. The intravesical tension is considerably raised in consequence of the enlarged prostate, as shown by the fasciculated and hypertrophied wall. Rupture takes place at the weakest spot, and there is a sudden extravasation of urine into the cellular tissue between the peritoneum and the abdominal wall at the apex of the bladder. As the recto-vesical sheath is not present over that portion of the viscus, the rapid formation of the swelling in the supra-pubic region which was observed during life may be explained. By inflammatory condensation of the surrounding tissues the wall of the cyst is produced, and the omentum becomes adherent to it. Finally, the cyst is converted into a virtually closed sac by the protrusion of

masses of growth into its orifice, which block it up in a valvular manner.

CASE 3. (Preparation in R. C. S. Museum.)—The clinical history of this case has been fully recorded.[1] The patient was a man aged 48, who died of a sloughing epithelioma of the urinary bladder. The autopsy revealed an ulcerated growth upon the base of the bladder; almost the whole of the posterior wall was destroyed by ulceration, and in its place was seen a large, wide-mouthed pouch filled with diffluent growth (Plate IV, fig. B). The wall of this pouch was composed of peritoneum from the back of the bladder and the subjacent recto-vesical fascia, both of which were merely pushed backwards off the bladder, and thus a space was enclosed. As might have been expected, the detachment of the recto-vesical fascia meant the displacement of the vas and vesicula seminalis, and in the specimen now exhibited both vasa deferentia and vesiculæ seminales are seen lying upon the convexity of the pouch (Plate IV, fig. C). The preparation is chiefly valuable in that it supplements the descriptions already given of the specimens from Cases 1 and 2. Here both the cause and the constitution of the pouch cannot be questioned. Its mouth is a perforation of the posterior wall of the bladder caused by the ulcerating epithelioma, and its cavity is a space between the recto-vesical fascia and the level of the wall of the bladder. The growth which filled the pouch was almost fluid, and of course had not originated there, but had drained into it from the interior of the bladder. The edge of the mouth of the pouch was covered with epitheliomatous growth which had not been destroyed by ulceration. This is shown in the photograph (Plate IV, fig. B).

CASE 4. (Preparation in R. C. S. Museum.)—The history of this patient has been recorded,[2] and the following is an abstract of it:—A man, aged 61, was admitted to a hospital for a tumour in the right iliac and hypogastric regions with bladder symptoms. Except for an inguinal hernia of long duration, and winter cough, he had enjoyed good health previous to his present illness, which began with a severe rigor a year before admission. This was followed by great difficulty in micturition, though he found that he could pass

[1] 'Trans. Path. Soc.,' 1894, vol. xlv, p. 98.

[2] 'Clin. Journ.,' 1893, vol. iii, p. 49.

water much easier when lying down. Eight months ago the urine first became thick and very offensive; no hæmaturia, but occasional passage of gravel. These symptoms continued, and during the last few weeks before admission the patient noticed a swelling in the lower part of the abdomen.

On admission this swelling extended upwards about three inches above the pubes, to the right of the median line, towards the right iliac region. It was well defined, with a smooth rounded outline, slightly moveable, tense, and not fluctuating.

The urine on admission was acid and free from pus; but eight days later there was definite pyuria, and the upper part of the swelling was then soft and fluctuating. The urine also became very foul, and was mixed with an abundance of mucus. Rectal examination showed no enlargement of the prostate, and the swelling could not be felt. When a sound was introduced it was found that the instrument was pressed towards the patient's left side by something in the wall of the bladder, and there was a gritty sensation along the right wall of the bladder. Abdominal palpation some three days later revealed the fact that the swelling had rapidly increased to nearly double the size it was on admission, so that it now reached almost to the umbilicus, and across the middle line into the right iliac fossa. It was also noted that after the bladder had been washed out pressure upon the swelling somewhat increased the flow of pus, suggesting an indirect communication between the swelling and the cavity of the bladder.

The patient died, and at the autopsy a very large succulus of the bladder was found, the cavity of which was distended with decomposing urine. A tumour grew into the sacculus, and projected like a valve over the orifice of communication between the sacculus and the bladder (Plate VI, fig. B).

Description of the preparation.—The specimen consists of a bladder and prostate; with the former is connected a large cyst containing a solid tumour. Each of these parts will be described separately.

The *prostate* displays considerable enlargement of both lateral lobes, and a vertical section shows that there has been retention and suppuration in the glandular tissue of the left lobe of the organ.

The *bladder* is moderately dilated and hypertrophied, and there is well-marked fasciculation of its posterior wall. Immediately behind the inter-ureteral bar there is an oval pouch placed trans-

versely; it is the size of a large walnut, and protrudes from the base of the bladder between the two vasa deferentia. The left vas deferens and vesicula seminalis are much displaced outwards by the sacculus, but otherwise are normal. In the recent state the pouch contained a small calculus like a piece of candy-rock. Both ureters are somewhat dilated, though their vesical orifices are normal. The mucous membrane on the posterior wall of the bladder exhibits a series of flat ulcerated nodules and lines, which seem to be the result of chronic cystitis. At the fundus of the viscus is an oval aperture, 2½ inches in its chief diameter, which forms a communication between the vesical cavity and a very large cyst situated above the bladder (Plate VI, fig. B).

The *cyst* measures 6 inches from side to side, and 4 inches from above downwards as well as from before backwards. The wall of the cyst is thin but tough, and is covered posteriorly with peritoneum which has been stripped from the fundus of the bladder and the back of the anterior abdominal wall. Superiorly a large piece of the great omentum is firmly adherent to the cyst, while in front the cyst-wall has been detached from the tissues of the anterior abdominal wall. There is now no complete lining membrane to the cyst, but examination shows areas of mucous membrane which have ulcerated margins, or are continuous with that of the bladder through the oval aperture above mentioned. Hence it may be concluded that the cyst was originally provided with a mucous lining, and that the membrane has been subsequently destroyed in part by suppuration and distension of the cyst. Where the mucous membrane has disappeared the interior of the cyst is ragged and uneven.

The *growth* forms a spherical mass within the cavity of the cyst, and measures about 3 inches in diameter. It is entirely *outside* the vesical cavity, and springs from that portion of the cyst wall which is in contact with the fundus and front of the bladder, as well as from the anterior part of the cyst which is in contact with the abdominal wall. On careful examination of this rather complicated origin it is found that the tumour arises chiefly and primarily from the front of the cyst, and therefore not in direct relation with the bladder. But in addition to this the tumour has contracted a secondary adhesion to, or has extended towards, the margin of the aperture in the bladder on its outer surface. Thus a flattened space or chink (covered with normal mucous membrane) exists between these two attachments of the tumour. On section the

DESCRIPTION OF PLATE VI.

Illustrating Mr. Targett's paper on "Diverticula of the Bladder associated with Vesical Growths." (Page 155.)

Figs. A and C are from photographs of a preparation in St. Bartholomew's Hospital Museum. They represent the front and back views of a bladder, and a large diverticulum attached to its posterior surface. See description on p. 167.

Fig. B is from a photograph of a preparation in the Royal College of Surgeons Museum. See description on p. 163.

Fig. C

Fig. B.

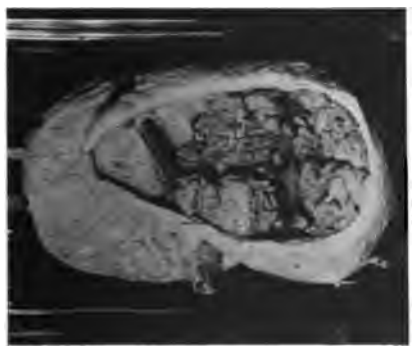

Fig. A.

tumour has a spongy appearance and is firmly adherent to the wall of the cyst, but does not appear to have invaded it. The attachment to the cyst-wall is distinctly constricted; hence the margin overlaps considerably. The convex surface of the growth is deeply excavated and fissured from sloughing of the tissues. Histologically the growth is a squamous-celled epithelioma.

Remarks.—In this preparation there can be no doubt that the cyst at the fundus of the bladder represents a large diverticulum or sacculus of the mucous coat, and that its wall (which is an extension of the tissues of the bladder) has become the seat of an epithelioma. The situation of the cyst is interesting. Large apical sacculi of the bladder are not common, and have been erroneously regarded as cysts of the urachus. Their relation to that structure, however, is somewhat accidental; for it is owing to the disarrangement of the fibres of the muscular coat at the apex, and the imperfect felting which results from the urachus passing through the bladder wall, that a protrusion of the mucous coat in the form of a sacculus is permitted. Anything which perforates the muscular coat of the bladder must necessarily weaken it, and it is a significant fact that the large sacculi are always found near the ends of the ureters, or the attachment of the urachus. Microscopical examination of the wall of such a cyst shows a layer of mucous membrane and submucous tissue. Outside these the structure varies. There may be a distinct muscular coat with its fibres arranged in interlacing bundles; sometimes merely a tough fibrous capsule is found, which probably represents the recto-vesical fascia thickened by chronic inflammation. That the mucous lining of a sacculus so constituted should under certain circumstances become the seat of a new growth is not to be wondered at. In the present instance the growth is malignant (squamous-celled epithelioma), but in the next specimen it appears to be a simple villous papilloma.

Case 5. (Preparation in St. George's Hospital Museum.)—The bladder has been opened in front, and shows a small sacculus upon its left lateral wall. The mouth of the sacculus is a little above the orifice of the left ureter. A sessile fimbriated papilloma springs chiefly from the wall of the sacculus, but has extended from the sacculus over the adjacent vesical wall for a short distance. The naked-eye appearance of the growth indicates that it is of an innocent type.

The only record preserved of this case states that symptoms of disease of the bladder had existed for many years, and that there had been occasional attacks of hæmorrhage, the source of which was not discovered during life. An enlargement of the prostate was present, and this was doubtless the primary cause of the sacculus. Whether the retention of foul urine in the sacculus acting as an irritant determined the papillomatous outgrowth from the mucous lining or not, is an open question. But it is interesting to compare the situation of this growth at the mouth of the sacculus with that of the common villous tumour which so frequently springs from the lips of the orifices of the ureters. One cannot but believe that the constant passage of possibly acrid urine is a powerful factor in the production of the simple papilloma from the mucous membrane at the latter site.

Case 6. (Preparation in Middlesex Hospital Museum.)—The history of this case has been already recorded.[1] The patient was a man, aged 62, who was under treatment for a swelling in the hypogastric and left iliac regions with urinary symptoms. He died of suppurative pyelo-nephritis. The bladder is thus described: "The walls of the bladder were hypertrophied, and its mucous membrane was of a slaty colour. The prostate was moderately hypertrophied. About an inch above the orifice of the left ureter was a rounded opening the size of half-a-crown, which led into a diverticulum considerably larger than the bladder itself. This contained a soft fleshy growth, which was attached by a broad base to that end of the diverticulum furthest from its opening into the bladder. The bladder and its diverticulum contained a considerable quantity of purulent foul urine mixed with sloughy shreds from the diseased parts."

The growth is described as a sarcoma, but that is probably incorrect. As seen in the preparation, it has extended from the primary seat along the wall of the diverticulum to the aperture in the bladder. Indeed, the margins of this aperture are affected, and the growth has spread downwards in the bladder so as to involve the orifice of the left ureter. In consequence of this obstruction, the left kidney, pelvis, and ureter were much dilated, but *not* inflamed. On the other hand, the right kidney was in a state of advanced suppuration, and its ureter was patent. The condition of the kidneys was pre-

[1] 'Trans. Path. Soc.,' 1883, vol. xxxiv, p. 152.

cisely like that of Case 1 (see p. 159), and was doubtless brought about in the same manner.

CASE 7. (Preparation in St. Bartholomew's Hospital Museum.)—The specimen consists of a bladder which is much hypertrophied and fasciculated in consequence of a general enlargement of the prostate. There is a large mass of new growth springing from the mucous surface of the posterior wall of the bladder and the trigone. To the back of the viscus is attached a cyst almost as large as the bladder itself, and filled with a lobulated growth which is directly continuous with that inside the bladder. The cyst has a distinctly constricted attachment to the exterior of the bladder over an area which would normally include the termination of the right ureter. As a matter of fact, the right ureter opens into the cyst upon its median wall, or that part of it which is nearest to the left ureter. Before opening into the cyst the ureter is firmly adherent to its wall for a distance of nearly an inch. The right vas deferens is significantly placed on the median side of the cyst, and cannot be seen in the photograph. But it is entirely detached from the bladder, and incorporated with the wall of the cyst. Both vesiculæ seminales have been cut away, but one or both must assuredly have been displaced by the cyst from relationship with the bladder. The catalogue further describes the cyst as situated between the muscular coat of the bladder and the peritoneum covering its posterior wall (Plate VI, figs. A and C).

The clinical history of the case states that the patient had difficulty in passing urine and occasional retention during two years. In the last attack of retention the prostate gland was pierced by a silver catheter, as shown in Plate VI, fig. C. But the withdrawal of the urine did not reduce a swelling felt above the pubes, which was produced by the bladder being pressed forwards by the cyst, which was distended with new growth.

Remarks.—From the relation of the right ureter to this cyst behind the bladder it might be argued that the cyst was due to dilatation of the lower end of the ureter, the vesical orifice of which had become blocked by extension of the new growth from the bladder along its canal, as is sometimes seen. The detachment of the right ureter from the bladder disproves this view, as already explained in reference to Case 1, p. 157.

Again, the cyst cannot be due to perforation of the vesical wall by the epithelioma, and escape of urine beneath the recto-vesical fascia,

as in Cases 1, 2, and 3. For the front view of the specimen (Plate VI, fig. c) shows that the cyst has a small orifice, and is therefore flask-shaped like the large sacculi or diverticula of the bladder. The most probable explanation would seem to be that a basal sacculus of the bladder was caused by the urinary obstruction (enlarged prostate), and that when an epithelioma developed upon the trigone it gradually extended into the preformed cyst. It has been pointed out that large sacculi are commonly met with where the ureters perforate the vesical wall. As a consequence their orifices may become so shifted that they are ultimately placed in the wall of the cyst or sacculus and not in the bladder itself. And I would submit that such a change has taken place in this specimen. That the cyst is in reality a sacculus of the mucous coat is proved by the fact that those parts of the cyst wall which are not invaded by the epithelioma have a distinct lining of mucous membrane. *March 17th*, 1896.

---

17. *Primary colloid carcinoma of bladder.* (*Card specimen*)

By H. C. Sharp, M.D. (per J. H. Targett, M.S.).

History of case.—From a man aged 55, whose illness began with pain and frequency of micturition two years previously. During the last six months of life he had incontinence of urine and continuous hæmaturia, though confined to his bed the whole time. He stated that these symptoms were due to the passage of a sound which made him bleed, and there was constant hæmorrhage afterwards. He rapidly became exhausted and sank. It is worthy of note that at the age of twenty years the patient had lateral lithotomy performed on him, and a large vesical calculus was removed. He completely recovered from the operation, and was quite well and strong up to the onset of his final illness at the age of fifty-three, or two years before death.

The autopsy was somewhat incomplete, but there were no enlarged pelvic glands, and the prostate, peritoneum, and intestinal tract were normal. The left kidney was simply hypertrophied, while the right showed dilatation of the pelvis from obstruction of its ureter, but there were no signs of suppurative nephritis.

Description of specimen.—The preparation consists of the right half of the bladder divided in an antero-posterior plane. The cavity is very small in consequence of great thickening of the vesical wall, which has a semi-translucent appearance on section. The mucous surface is very rough from ulceration. The right half of the bladder is uniformly thickened, and its edge measures three quarters of an inch. The left portion has not been preserved, but it was similarly though less extensively affected.

Microscopically, the submucous tissue and nearly the whole thickness of the muscular coat are infiltrated with colloid material arranged in small rounded alveoli. In a few of these alveoli the bloated outlines of the original cells may be discerned, but in the majority of instances all traces of cells have disappeared. The mucous membrane has been removed by ulceration, and the surface of the growth is covered with granular exudation and sloughy tissue. Primary colloid carcinoma is very rarely met with in the urinary bladder. *May 5th*, 1896.

---

18. *Case of primary sarcoma of the vagina in a child, associated with multiple polypi.*

By D'Arcy Power, M.B.

Primary sarcoma of the vagina is a rare condition both in children and in adults. The following case came under my care at the Victoria Hospital for Children. The full clinical details are published in the 'St. Bartholomew's Hospital Reports,' vol. xxxi, p. 121, so that here it need only be stated that the child was two years and four months old. She was admitted for retention of urine, caused by a tense swelling in the vagina. Her illness was said to date from an attack of measles fourteen months previously, which had left her with a purulent vaginal discharge. Five months before she came to the hospital it was seen that she had polypi projecting from her vulva. Some of these had been removed. She never had any trouble in passing her motions. She died with symptoms of uræmia. The autopsy, made thirty-three hours after death, showed that there were no secondary deposits in any part of the body.

The kidneys were congested, but were otherwise healthy. The ureters were not dilated.

The pelvic organs which I exhibit this evening, and which are now in the museum of St. Bartholomew's Hospital, No. 3030A, were hardened in Foa's solution, and afterwards preserved in alcohol.

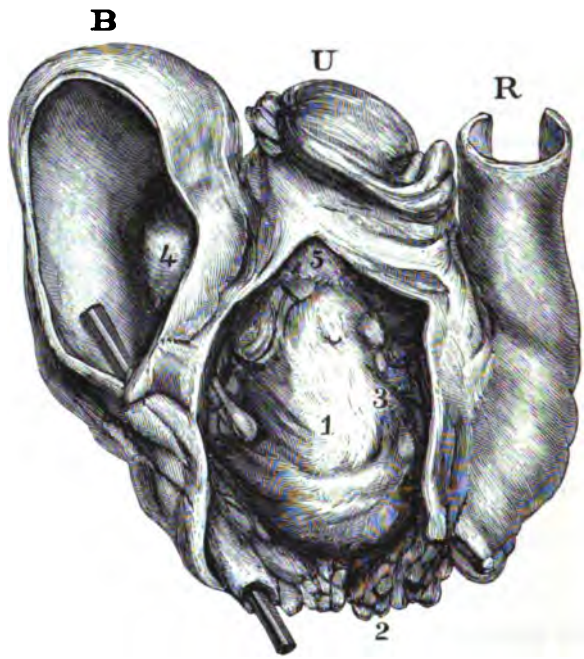

FIG. 10.—The pelvic organs of a child affected with primary sarcoma of the vagina. The dilated vagina is exposed by the removal of its left wall. A rod has been passed through the urethra. B. The dilated bladder. U. The uterus and its appendages. R. The rectum. In the vagina, 1 is placed upon the projection of the right wall caused by the mass of new growth seen in Fig. 11. This mass terminates at 5 as a lobulated growth situated just below the os uteri. 2. The polypoid masses at the ostium vaginæ. 3. The pedunculated growths at the upper part of the vagina. 4. The projection of the anterior *cul-de-sac* into the bladder.

They show that the bladder is greatly enlarged, and that its walls are thickened by the hypertrophy of its muscular coat. The upper part of the dilated vagina has projected into the bladder just above the trigone and upon its left side. The vesical mucous membrane is perfectly healthy. The urethra, too, is healthy, though it is much

elongated. It opens upon the anterior wall of the vagina somewhat higher than usual, and well above the point at which the vagina has been divided in removing the organs from the body.

The uterus is enlarged, but it does not seem to be diseased. The ovaries and the broad ligaments are normal in every respect.

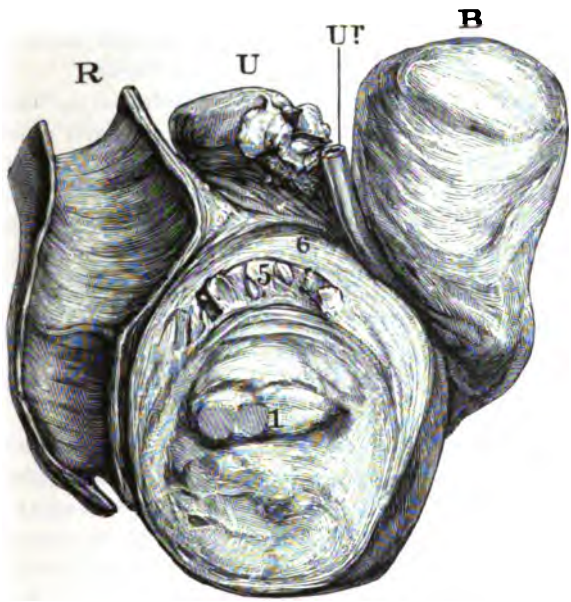

FIG. 11.—Sections through the right side of the pelvic organs from the same case as Fig. 10. R. The rectum. U. The uterus and its appendages of the right side. Ur. The right ureter embedded between the vaginal wall and the bladder. B. The bladder. 1. The circular mass of new growth projecting upwards at 5 to form a coronet of polypoid tumours which project freely into the upper part of the vagina. 6. The vaginal wall bounding the posterior *cul-de-sac*, which has been laid open in making the section, and is represented by the space between the rounded top of the new growth and the line marked by 6. The space is filled with the polypoid growth.

The vagina has been laid open by cutting away its left wall, which was covered with warty growths. The whole vaginal canal is enormously dilated, but its walls are not proportionately thickened. It is pouched in its upper third, so that it projects into the bladder anteriorly, and into the recto-vaginal space posteriorly, and it is divided vertically by a mass of new growth which is covered with

normal mucous membrane. This mass projects from the right wall, and is more prominent at the upper than at the lower part of the vagina. It is most prominent immediately below the anterior lip of the os uteri, where it stands out as a lobulated mass, like a cock's-comb, and it is of much the same consistence. A longitudinal section taken through the preparation to the right of the vagina shows that this projection, which appears to be cylindrical in the vagina, is in reality the side of a circular mass of new growth developed in the connective tissue on the right side of the vagina. It has grown until it has compressed the rectum on one side and the bladder upon the other. This mass of new growth is still well circumscribed except at its upper part, where it has become lobulated to form rude polypi. The circumscribed portion of the growth is almost exactly circular, and measures two inches across. It consists of denser masses embedded in soft gelatinous tissue. The right side of the posterior cul-de-sac of the vagina has been so greatly distended that the lateral section has cut away a part of the vaginal wall, and it is thus seen how the polypi project into the cavity of the vagina. The right ureter is wedged into a narrow channel between the top of the growth and the base of the bladder.

The whole mucous membrane of the vagina is studded with hundreds of polypi, varying in size from the smallest pin's head to a large pea. The polypi are obviously of two kinds: some, less numerous, sessile, and denser than the rest; others, more numerous, pedunculated, and gelatinous. The pedicles of the latter variety are often very long and slender, so that the polypi float freely in the vaginal cavity. They are most numerous about the ostium, and again in the upper third of the vagina, where they are packed so tightly as to form a mosaic in the hardened specimen.

A microscopical examination of the vaginal wall shows that its serous and muscular coats are healthy. The submucous connective tissue is very soft and gelatinous. It is increased in quantity, and the thickening is not uniform. The submucous tissue is infiltrated with numerous small round cells, and aggregations of these cells, covered with vaginal epithelium, have grown into the lumen of the vagina to form the soft gelatinous polypi which are so conspicuous a feature in the specimen. Even the most rudimentary of the polypi thus formed has a constriction at the level of the vaginal mucous membrane, showing that it would eventually have become pedunculated. These polypi must be classed as myxo-sarcomata.

The denser polypi and the circumscribed mass of growth springing from the side of the vagina are small round-celled sarcomata containing a great deal of fibrous tissue. These denser masses are, therefore, rather of the type of fibro-sarcomata than of myxo-sarcomata. None of the growths examined contained striped muscle-fibres in their substance other than those which could be accounted for as belonging to the normal tissue of the parts involved.

A somewhat similar specimen was shown by Mr. Howard Marsh in 1874, and is described in the twenty-fifth volume of the Society's 'Transactions.' The condition is well known in Germany, but it has hitherto excited but little attention in this country.[1]

October 15*th*, 1895.

---

19. *Uterus unicornis with congenital malposition of the right kidney.* (*Card specimen.*)

By Arthur Voelcker, M.D.

Description of specimen.—The left portion of the uterus alone is developed. The right ovary and Fallopian tube are present, but have no connection with the uterus. There is no trace of the right half of the uterus.

The cervix is single, and the left ovary and Fallopian tube are normal.

The right kidney is situated in the right iliac fossa, and the right renal artery arises from the right common iliac artery. It is interesting to note that the right supra-renal body occupied its normal position in the abdominal cavity.

From a woman aged forty who died from the effects of a fracture of the skull. *October* 15*th*, 1895.

[1] For a further account of this subject, with woodcuts and a bibliography, see 'St. Bartholomew's Hospital Reports,' vol. xxxi, pp. 121—135.

VI. DISEASES, ETC., OF THE ORGANS OF LOCOMOTION.

1. *Traumatic separation of the epiphysis of the great trochanter. (Card specimen.)*

By J. Hutchinson, jun.

This specimen was obtained by Dr. Daniells, of British Guiana, from the body of a lad aged 13, who died from internal injuries two weeks after he had fallen from a tree to the ground, a distance of some twelve feet. The great trochanter is separated from the rest of the femur, in great part exactly through the "epiphysial line." Owing to the fibrous connections of the trochanter, however, the detached portion was held somewhat in place, and the lad was able to stand on the affected limb, and to raise it from the bed. The exact lesion was not diagnosed during life.

December 3rd, 1895.

---

2. *Old injury of humerus from an Egyptian mummy.*

By J. H. Targett, M.S.

The skeleton to which the specimen belongs was presented to the College of Surgeons' Museum by Mr. J. Willoughby Fraser. It was taken from an Egyptian mummy of the 6th dynasty, or about 3000 B.C. The specimen is a right humerus measuring 261 mm. The lower extremity and lower half of shaft are practically normal, but the head and upper half of the shaft are much deformed. The head has almost disappeared, and in its place is a broad, rough, concavo-convex surface, which has articulated with the scapula. This articulating or glenoid surface, as it may be called, has prominent margins, especially below where it projects downwards upon the posterior surface of the humerus for some distance. It measures nearly three inches vertically, and two inches from side to side. The centre of this glenoid surface is raised, and is placed much below the usual level of the head of the

humerus, being fully one inch *below* the superior border of the greater tuberosity. The outer aspects of the two tuberosities allow them to be recognised, but the top of the bicipital groove is filled up with a nodular outgrowth of bone.

The upper half of the shaft shows two curves, one with its convexity outwards in the direction of the pull of the deltoid muscle, the other with its convexity directly forwards. The posterior surface of the shaft is deeply grooved in its upper half, the cause of which is not apparent unless it be the effect of longitudinal torsion as mentioned below. There is also a well-formed deltoid impression, and a distinct musculo-spiral groove.

The head of the scapula is altered by conversion of the glenoid fossa into a saddle-shaped surface, with much lipping of its anterior and posterior margins by osseous deposit. When the humerus and scapula are articulated the anterior border of the former looks almost directly outwards, and the front of the elbow-joint must have been correspondingly displaced. When the upper end of the humerus is placed in its normal position as determined by the bicipital groove and outer surface of the great tuberosity, then the lower end of the bone seems to have undergone torsion in the long axis of the shaft through an angle of fully 60° from within outwards in a horizontal plane. The clavicle, radius, and ulna of the right side are certainly smoother and more slender than their fellows. There is also a diminution of 3 mm. in the circumference of the right clavicle at the centre of its shaft when compared with the left.

The spine shows synostosis of the fourth and fifth lumbar vertebræ, and a little lipping on several other centra. The facets for the ribs upon the vertebræ and sternum are deep and well defined. The pelvis, which is not damaged, has male characters. It measures eight inches between the anterior superior iliac spines, while between the tubera ischii it is barely four inches. The sacrum is straight.

There is an oval facet on the front of each cervix femoris, placed just outside the articular surface of the head. At first sight this appeared to be due to the pressure of the margin of the acetabulum owing to the thighs being fixed in a position of marked flexion with adduction. But it was found that the limbs would not fit in that attitude. Moreover there was no corresponding facet on the acetabulum. Hence it was concluded that these symmetrical depressions in the femora were due to pressure of the ilio-femoral ligaments, which may have contained ossific deposits.

The measurements (in millimetres) of the principal long bones of this skeleton are—

	Right.	*Left.*
Humerus	261	335
Clavicle	151	157
Radius	264	260
Ulna	286	284
Femur	462	467
Tibia	392	393

Remarks.—In forming an opinion as to the pathology of this osseous lesion we are met with the difficulty of deciding in the first place whether it is due to traumatism or to disease. The nodular outgrowths of bone on the upper end of the humerus and the glenoid fossa of the scapula are of an osteo-arthritic type, but they are clearly secondary and the result of mechanical causes. Arthritis in early life may be excluded by the absence of any attempt at ankylosis, and of all evidence of necrosis or periostitis about the shoulder-joint.

As regards traumatism, there is no sign of fracture of the surgical neck, or of the shaft of the humerus below that level. The extreme shortening of the humerus, and the slender character of the clavicle, radius, and ulna on the right side may be attributed to impaired growth resulting from a separation with displacement of the upper epiphysis of the humerus, and associated possibly with paralysis of the limb in early life. It is true that the outlines of the tuberosities and the intervening bicipital groove seem to have been preserved, and this would imply that the upper epiphysis of the humerus had not been separated in its entirety. This objection may be met by supposing that the head with its centre of ossification became detached from the nucleus of the greater tuberosity during the fourth or fifth year of childhood, that is, before these nuclei had united to form the upper epiphysis of the humerus. Inasmuch as growth takes place chiefly at this epiphysis, the remarkable dwarfing of the bone would be accounted for. Lastly, the curvature and twisting of the diaphysis may be explained by the muscles acting upon soft, imperfectly formed osseous tissue.

A specimen in Guy's Hospital Museum closely resembles this one, and is accompanied with abundant clinical evidence that its arrested development is due to separation of the upper epiphysis of the humerus in early life. *October 15th*, 1895.

3. *The pathology of hypertrophic pulmonary osteo-arthropathy.*

By WILLIAM THORBURN and F. H. WESTMACOTT.

[With Plate VII.]

THIS rare disease was first described in 1890 by Marie ('Revue de Médecine,' 1890, p. 1), who then differentiated it from acromegaly, but it was apparently not recognised in England until one of us (Thorburn, 'Brit. Med. Journ.,' 1893, vol. i, p. 1155) published a report of three cases in 1893. Of these cases the first, a lad, T. H—, aged 21, was the most fully described, and photographs of his limbs illustrate the paper already referred to. From that time T. H— remained under observation until his death on September 13th, 1895, and in Mr. Thorburn's absence the *post-mortem* examination was then carried out by Mr. Westmacott. For all statements of fact relating to the *post-mortem* appearances we are jointly responsible, but the former of us is alone to be held accountable for the theoretical considerations which conclude this paper.

The clinical history and symptoms of this patient, having been already fully recorded, may here be briefly summarised. At the age of sixteen he suffered from an affection which was apparently regarded as a patellar bursitis, but which is shown by the *post-mortem* examination to have been ostitis of the head of the right tibia; as a result of an operation then performed, he had scars on either side of the insertion of the right ligamentum patellæ. Shortly afterwards the patient developed spinal caries, with a lumbar and psoas abscess on the right side, and, having again been operated upon, he retained a discharging sinus in the right loin and a marked angular curvature at the dorso-lumbar junction. Enlargement of the hands and feet was first noticed by T. H— in 1891, when he was eighteen years of age, and he came under observation in the beginning of 1892. In addition to the spinal condition and the scars about the right knee there was now evidence of a vomica at the apex of the left lung, general anæmia, and the specific condition of enlargement of the limbs which constitutes hypertrophic pulmonary osteo-arthropathy. The knee-joints were occasionally painful and swollen, with

permanent thickening of the synovial membranes and effusion into their synovial sacs whenever the patient was not kept in bed. The feet were symmetrically and greatly enlarged, the swelling extending downwards from a point about five inches above the ankle-joint over the entire ankle and foot; the malleoli were very prominent. The bones of the affected regions were clearly the seat of hypertrophy, the soft parts being little if at all affected, and the shaft of the left tibia was thicker than that of the right. In the upper limbs, enlargement extended symmetrically downwards from about three inches above the wrist-joints over the lower part of the forearms, the wrists, hands and fingers; here also the bones were clearly enlarged; the ends of the fingers were slightly bulbous. All the extremities were pale, and free from any appearance of congestion or œdema. Photographs taken at this period and published in the 'British Medical Journal' differ in no way from the later illustration annexed to this paper (Fig. 12).

From the time of the report of this case in 1893, until the patient's death in 1895, no marked changes occurred; the lad became gradually feebler and more anæmic, diarrhœa and extreme exhaustion ensued, and on September 13th, 1895, he died with the usual symptoms of amyloid disease.

As negative points we may note that chest symptoms were never prominent; the thyroid gland, larynx, and features were normal, as were the optic discs, and there was never any indication of disease in the shoulders, hips, or elbows. The accompanying photograph was taken only a week before death, and illustrates the clinical appearances (Fig. 12).

The autopsy was performed after some delay, and the weather being intensely hot it was impossible to obtain any tissues in a condition for bacteriological investigation, nor was any complete histological examination practicable; but we were able to examine and retain most of the bones and joints, which are now fully illustrated.

The following changes were found in connection with the *viscera*. The right pleura presented recent adhesions over the entire lung, except on its posterior border, where these adhesions were older and firmer; on the left side there were firm pleural adhesions throughout; neither side of the chest contained any fluid. The right lung was somewhat emphysematous, especially at its anterior border, and near the base in the axillary line it contained a hard

FIG. 12.

nodule of about the size of a pea, which presented the histological appearances of chronic pneumonia, but in which no distinct tubercles were found. The left lung was small, bound down by the already mentioned adhesions, and containing at the apex a puckered funnel-shaped cicatricial depression, of such a size as might have been produced by indentation with the tip of the little finger, this being the only trace of the cavity detected in 1893; here also no tubercles were found. The bronchial tubes on both sides contained a small amount of frothy fluid, but were free from marked dilatation. The bronchial glands were of normal size and deeply pigmented, containing iron, which was also found throughout the lungs. (The patient's occupation had been that of an iron turner.) In the pericardium were a few ounces of fluid, but the heart and great vessels were normal, as was the thyroid gland.

The brain and meninges were normal, except that the pituitary body was of cartilaginous hardness, and of about the size of the kernel of a hazel-nut; on the choroid plexuses were non-tubercular granulations. The dorso-lumbar region of the spine showed the changes of old healed caries, the anterior parts of the bodies of the lower four dorsal and upper three lumbar vertebræ being united by a strong buttress of bone; the sinus in the right loin was patent externally, but did not reach to the spine, being lost in a mass of cicatricial tissue behind the kidney.

The liver was very large and hard, weighing 130 ounces, and presenting the usual macroscopic and microscopic appearances of advanced amyloid disease with fibrous degeneration. The spleen, weighing 19½ ounces, and 7 inches in length, was also hard and fibrous with marked amyloid degeneration. The kidneys were normal. In the intestines were traces of extensive catarrhal inflammation, the retro-peritoneal glands being healthy. The left supra-renal capsule was normal; that on the right side, which lay in close proximity to the lumbar sinus, was somewhat enlarged, very firm in consistency, and studded with perfectly typical giant-celled tubercular granulations.

To this we may add that in front of the right tibia, at the site of its upper epiphysial cartilage, there was a rough bony prominence underlying the cutaneous scars already mentioned, and clearly due to a bygone focus of inflammation.

The visceral changes were thus those of amyloid disease, with cicatrices in both lungs, probably of tubercular origin, healed caries

in the spine and right tibia, and typical tubercles in the right supra-renal capsule. There was no active tuberculosis, and no decomposing bronchial secretion or purulent accumulation.

The *skeletal changes* were far more extensive than had been indicated by the patient's condition during life. The skull presented a smooth external surface, but was rough internally, especially on either side of the longitudinal sinus; it was extremely dense, and contained no diploë, while its thickness, as observed in the usual *post-mortem* section, was increased to a quarter of an inch at the pterion and three eighths of an inch in the occipital and frontal bones. The sternum, ribs, lower jaw, and facial bones were not removed or cut into, but they presented no abnormality, and no change was detected in the temporo-maxillary or sterno-clavicular joints, which were laid open.

Passing now to the limbs, we found almost universal changes in the bones and joints, the osseous lesions being essentially those of periostitis with some sclerosis, while the joint changes consisted in a remarkable series of symmetrical erosions of the articular cartilages with occasional evidences of synovitis. The erosions to which we shall have to refer consisted in a thinning of the cartilages without loss of polish, this thinning commencing from the surface; thus in many places the cartilage presented a distinct shallow hollow, well seen in Figs. 14 and 16, whereas in other regions where the process was more advanced the subjacent bone was quite exposed. The cancelli thus laid open were perfectly normal in appearance, presenting no trace of superficial eburnation, and there were no articular ecchondroses or osteophytes. These changes were almost perfectly symmetrical on the two sides of the body, and there was also a strong family likeness between the hips and shoulders on the one hand and the knees and elbows on the other. The subperiosteal deposits on the bones consisted of a very loose friable sheath, more marked at the attachment of muscles and tendons, and therefore more evident in the shafts than at the ends of the bones; on this deposit the markings of surface vessels and nutrient foramina were very prominent. In no case was there the slightest bending of the bones.

The *right hip-joint* contained a small quantity of glairy straw-coloured fluid; completely surrounding the cartilage on the head of the femur was a narrow ring of erosion, exposing the bone, and

extending more widely on the anterior aspect of its head, so as to approach the summit of the articular surface; the ligamentum teres was detached from the acetabulum, and at the bottom of the latter the bone cancelli were again exposed; the synovial membrane and capsule presented no change. The *left hip* contained rather more fluid than its fellow; around the cartilage of the head of the femur was the usual erosion, with a wider extension anteriorly, symmetrical with that of the right side; the ligamentum teres was in this case detached from the femur, and the acetabulum was healthy the

FIG. 13.

synovial membrane was again normal. The shaft of the *right femur* (Fig. 13) was covered with a friable sheath of new bone, and its

medullary cavity was somewhat encroached upon by a loose cancellous tissue. The *left femur* presented a similar subperiosteal sheath and was densely sclerosed, almost ivory-like in consistency, and with a medullary cavity of the diameter of a lead pencil.

The *right shoulder* contained a large amount of serous fluid; the cartilage on the head of the humerus was eroded down to the bone in a narrow ring which completely surrounded its margin and extended more widely on the anterior aspect of the head; the glenoid cavity and synovial membrane were healthy. The *left shoulder* was absolutely identical except that it contained a still larger amount of fluid (Fig. 14). The shafts of the *humeri* presented no changes.

FIG. 14.

The synovial membrane of the *right knee-joint* was villous and somewhat gelatinous throughout, having an average thickness of about half an inch; over the condyles of the femur the cartilage was thin, and presented irregular wavy depressions, resembling the lines caused by stroking soft wax with the back of the finger nail; at the inner margin of the internal condyle the bone was completely exposed (Fig. 13). On the cartilage of the patella were also hollowed streaks, but erosion was not complete at any point; on the head of the tibia was a figure-of-eight shaped line of erosion completely exposing the bony margins of each lateral facet; the semilunar cartilages were healthy; the anterior aspect of the patella was covered with the usual sheath of newly formed bone. The *left knee* was so absolutely symmetrical in its appearances and in the

distribution of its erosions that no detailed or separate description is required.

The *right tibia and fibula* presented extensive deposits of sub-

FIG. 15.

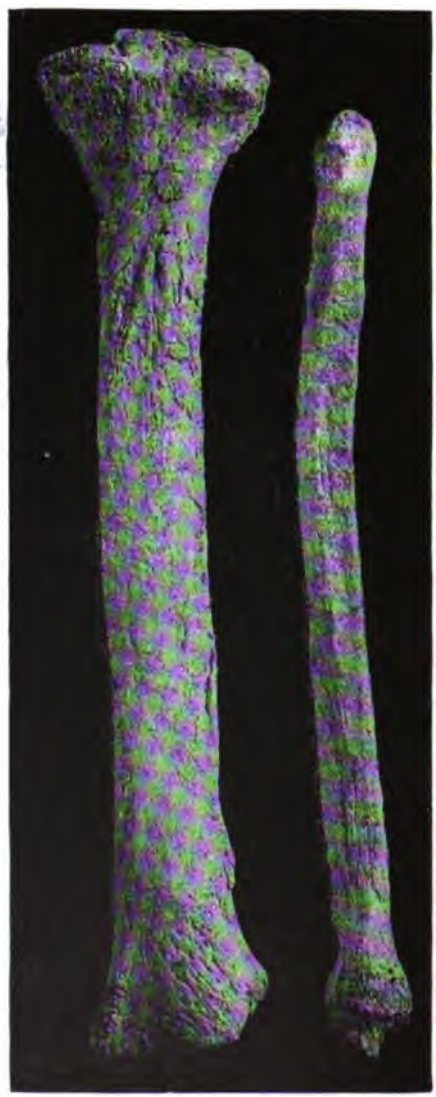

periosteal bone formation, the sheaths being considerably thicker than those of the femora; the *left tibia and fibula* presented the same changes in a still more marked degree, all the bones of the left lower limb being thickened to a greater extent than the corresponding bones of the right side (Fig. 15). The changes at the head of the right tibia, which form no part of the specific appearances of osteo-arthropathy, have been already mentioned.

The *ankle-joints* were free from synovial effusion or alteration of the synovial membrane, but each presented a ring of erosion around the edge of the articular cartilage of the tibia, with a small area of the same erosion on the anterior part of the upper articular facet of the astragalus. All the tarsal, metatarsal, and phalangeal bones of the *feet* presented a subperiosteal sheath of new bone, which was, however, less marked on the proximal phalanges than elsewhere, and small erosions of cartilage of the usual type were found in all the articulations of the feet.

The *right elbow-joint* contained a slight excess of fluid, its synovial membrane being apparently healthy; the cartilaginous surface of

FIG. 16.

the humerus was eroded down to the bone at the edges of the trochlear surface, and a transverse band of erosion nearly three-quarters of an inch wide ran across the great sigmoid cavity of the ulna; in the superior radio-ulnar articulation the ulnar cartilage had entirely disappeared posteriorly, its erosion being thus continuous with that of the great sigmoid cavity, while the cartilage on the head of the radius had disappeared on its outer aspect, but was unaltered on the inner aspect of its circumference; the humeral aspect of the head of the radius being normal. The *left elbow* was exactly symmetrical (Fig. 16). In the *inferior radio-ulnar* articulations of each side the erosions were incomplete, causing thinning of the cartilages without exposing the osseous tissue, and in each case this thinning was marked at the centre of the radial cartilage and at the extremities of that on the ulna, so that the affected areas were not opposed but alternating. The shafts of the *radii* and *ulnæ* presented marked periosteal deposits; the lower epiphysis of the right ulna became separated during maceration (Fig. 17).

Finally the carpal, metacarpal, and phalangeal bones of the *hands* were covered with the usual sheath of new bone, which was most marked at the carpus and at the base of the metacarpus, and small erosions were found in most of the joints of the hands. (Plate VII.)

Remarks.—Two previous *post-mortem* examinations of cases of hypertrophic pulmonary osteo-arthropathy have been made by Lefebvre ('Thèse de Paris,' 1891), and Rauzier ('Rev. de Méd.,' 1891, p. 30) respectively, but both of them are very incomplete, and in a third case (Springthorpe, 'Brit. Med. Journ.,' 1895, vol. i, p. 1257) there was no examination of the bones and joints. The appearances formerly described are, however, clearly similar to those met with in our case. Lefebvre, describing the radius, states that the diameter of the diaphysis was increased by the subperiosteal deposit of friable layers of new bone, and that "the articular surfaces of the radio-ulnar joint present a slight loss of polish, and at the level of the outer border of the scaphoid is found a slight erosion of cartilage corresponding to the radio-carpal joint." In the same case the metatarsal bones and the upper row of phalanges were unaltered, but the terminal phalanges showed some rarefaction. Histologically, the bones of the forearm presented changes of rarefactive ostitis with periosteal thickening, and chemically they yielded

DESCRIPTION OF PLATE VII.

Illustrating a paper by Messrs. W. Thorburn and F. H. Westmacott on "The Pathology of Hypertrophic Pulmonary Osteoarthropathy." (Page 177.)

From a photograph. It represents a subperiosteal deposit of bone, especially about the bases of the metacarpals and on the more distal phalanges.

an excess of fat with too small a proportion of lime salts. In the articular cartilages were a few "vacuoles." Rauzier describes

FIG. 17.

similar changes in the bones, erosions at the margins of articular cartilages and slight synovial effusion into the elbow, wrist, knee, and carpo-metacarpal joints. Bamberger ('Zeitschr. für klin.

Med.,' 1891, p. 193) also records several *post-mortem* examinations of the bones of persons affected with bronchiectasis which showed widely-spread subperiosteal deposits, and, in one case, sclerosis, several of his figures resembling most closely the bones which we have been describing, but he found no changes in the joints. There can be no doubt that some of his cases are examples of the disease under consideration, but his paper refers also to other conditions arising from the congestion of heart disease, and he writes without detailed reference to Marie's description of hypertrophic pulmonary osteo-arthropathy.

We may now safely state that the condition which we have described is one of very extensive periostitis of an extremely chronic type, accompanied by articular lesions of which the most prominent feature is an atrophy of the articular cartilages, this atrophy giving the impression of a chemical solution rather than of any active cellular changes.

The pathology of the condition is, however, highly obscure. Marie, reasoning from the clinical appearances, attributes it to the decomposition of secretion in dilated bronchi, or of pus in the cavities of empyemata, followed by absorption of the resulting toxines, and he suggested that these toxines then excited a periostitis or arthritis, owing to their having an "elective action" upon the bones and joints. He compares the disease to the pseudo-rheumatism of Bouchard and to gouty intoxication. Bamberger adopts a similar explanation of his cases, and compares the periostitis with that shown by Wegner and Gies to result from the action of phosphorus and arsenic, that variety being a direct result of chemical intoxication. It is interesting to note also that Bamberger found no evidence of similar bone lesions in cases of tuberculosis, and that he endeavoured to prove by bacteriological examination of the sputum that none of his patients were tubercular. He further traces a connection between the date of onset of fœtid sputum on the one hand, and of osseous pains on the other, and he attempted, without success, to produce bone changes in animals by the rectal injection of the fœtid sputum of bronchiectasis. On the other hand, the well-marked amyloid changes which we have described, and which have been clinically observed in other cases, indicate profound chemical changes, and it is not inconceivable that the periostitis and amyloid lesions may be joint effects of a common cause, or that the chemical disturbances resulting from amyloid disease

may lead to the production of a poison capable, under certain circumstances, of causing periostitis. In our case the theory of absorption and toxic periostitis is met by the difficulty that we had no large decomposing accumulation, and even if we take the view that the entire condition is one of septic inoculation rather than of septic intoxication, we must admit that the effect appears out of all proportion to the possible cause.

The remarkable symmetry of the lesions and the absence of clinical symptoms in joints so extensively altered, as well as certain general resemblances to other neuropathic affections of the bones and joints, suggested a possible nervous origin for the condition, but in the absence of any positive evidence in its favour this idea was at once rejected. That mere congestion cannot cause the changes described appears sufficiently obvious from the facts that they are not met with in association with the congestive clubbed fingers of many cardiac and lung diseases, and that in our case there was neither an obvious cause for congestion nor any clinical evidence of the existence of such a condition.

Syphilis is excluded, on the one hand, by the absence of penile cicatrix or other manifestations of the acquired disease, and on the other, by the absence of any changes in the teeth, nose, lips, corneæ, or elsewhere, which might suggest a congenital condition. The disease differs so widely from osteo-arthritis, osteitis deformans, or any other well-recognised condition that no further discussion of its autonomy is necessary.

In the paper previously referred to, one of us suggested the possibility of a widely-spread tuberculosis of low intensity, a condition occupying a relationship to the classical tubercular lesions of bones and joints, similar to that which lupus or Bazin's disease occupies to "tubercular ulcers" of the skin. Like many cases of lupus, osteo-arthropathy is widely spread and symmetrical, as well as being extremely chronic, and the affected regions very closely resemble in their clinical appearance those attacked by ordinary strumous joint disease.

In the present case we have evidence of a tubercular infection such as might be competent to produce the required conditions. The visceral lesions were widely disseminated, but had all healed, in spite of the fact that the general condition became progressively worse up to the time of death, and there can be no reasonable doubt that these lesions were tubercular. The periosteal inflammation is

one which the tubercular virus is competent to produce, and closely resembles the periostitis often found on the shafts of bones affected by tubercular epiphysitis. The changes in the synovial membranes of the knees were also of the type of tubercular disease, but the other joints were further removed from this type, and all that can be said of them is that they suggest the action of a chemical poison rather than of an organised irritant. While, therefore, the suggestion that osteo-arthropathy is a diffused tuberculosis is far from receiving satisfactory confirmation, it still remains as a possible explanation of the changes met with, the objection that not all recorded cases have been associated with tubercular disease of the lungs applying equally to all other theories yet advanced, none of which are competent to include all the reported cases.

Finally, we may mention as a purely tentative hypothesis the suggestion of Springthorpe (loc. cit.) that the conditions found might result from mal-oxygenation—a suggestion which finds no support from our case. *May 19th*, 1896.

---

4. *Case of osteitis deformans.*

By F. J. Fielder (per J. H. Targett, M.S.).

History of Case.—The patient was a woman aged 45. She was first seen in June, 1894, complaining of great pain in the limbs, which was always present, but worse at night. She had had twelve confinements; six children were living and six were dead, two of them from (?) tuberculosis. Her husband suffered from choroiditis, probably due to syphilis. The patient was in needy circumstances, being separated from her husband, and having to work hard to support herself and family. She began to notice her legs were getting broader, and becoming bowed, some two or three years previously, but was unable to fix the date more exactly. At first there was little pain, but it had steadily increased, and was described as of a dull, boring character, with exacerbations at night, when it waked her up with the sensation of something shot through her. She was three to four inches shorter than formerly. Heart,

lungs, and urine normal. No enlargement of liver or spleen. Menstruation regular.

On examination the bones of the head were found to be very regularly enlarged, though the right frontal eminence projected further than the left. She stated that her head was affected after the legs. The face bones were natural. The ribs were crowded together, and the breathing was entirely diaphragmatic. The spine was curved in the upper dorsal region. The limbs as a whole were considerably bent, and the disease seemed to be chiefly situated in the neighbourhood of the shoulder- and knee-joints. The right side of the body was more affected than the left. There was no tenderness on pressure over the bones.

Various drugs were given to relieve the pain, but with little effect; the best results were obtained from a mixture containing arseniate of soda and iodide of iron. The patient wasted while under observation. In July, 1895, œdema of the left foot supervened, and a tumour was felt in the left iliac fossa. The pain from the pressure of the tumour became very great, while that in the bones subsided.

The patient died on September 20th, 1895, of pneumonia.

Autopsy.—The body measured 5 feet in length. There was a soft, friable growth in the left iliac fossa, weighing 6¼ lbs. It extended from the left kidney downwards beneath Poupart's ligament for three inches into the thigh, and internally into the left broad ligament. On the outside it was bounded by the abdominal wall, and its circumference was about 22 inches. The growth was covered in front with the peritoneum. There were no secondary deposits in the liver, and the left kidney, though much displaced upwards, was healthy. Histologically the tumour was a sarcoma composed of round and spindle-shaped cells.

The skeleton is preserved in the College of Surgeons' Museum. The *skull* before drying weighed 5 lbs. 3 oz., but afterwards it was only 3 lbs. 3 oz. Its capacity is 1110 c.mm.; its greatest circumference is 24 inches (in life 25¾ inches); and the greatest thickness of the calvarium is 1¼ inches. The bones forming the base of the skull, including the basi-occipital, are very slightly affected. The *spine* shows ankylosis of the fifth and sixth, and the eighth, ninth, and tenth dorsal vertebræ, with curvature to the left side.

Upper extremity.—The left clavicle measures 133 mm. in length, and 40 mm. in circumference; the right 135 mm. and 64 mm.

respectively. The sternum is 160 mm. long, and 52 mm. at widest part. The upper half of each humerus is thickened, and the whole diaphysis is curved forwards. The *pelvis* shows great thickening of the iliac crests; the following measurements were taken:

Between tuberosities of ischium . .	116 mm.
„ spines „ . . .	104 „
„ anterior superior spines . .	245 „
True conjugate diameter	106 „
Right oblique „	128 „
Left „ „	108 „

There is much erosion of the inner surface of the left ilium and the adjacent edge of the sacrum produced by the abdominal tumour. The width of the right femur at the centre of the shaft is 26 mm., that of the left femur is 46 mm.

The following parts of the skeleton are unaffected, or very slightly so:—the hands and forearms, the feet, fibulæ, patellæ, ribs, and scapulæ except their spinous processes. On the other hand, the parts most affected are:—Entire length of left femur and upper half of left tibia, lower half of right femur, and upper three-fourths of right tibia, right clavicle, both humeri, calvarium, and lower jaw especially on the right side. *May 19th*, 1896.

DISCUSSION ON NON-SUPPURATIVE ANKYLOSIS OF JOINTS.

(*February* 18*th*, 1896.)

Introduced by WILLIAM ANDERSON.

IT has probably appeared to most of us that the pathology of the joint lesions which lead to ankylosis is still incomplete. Mr. Howard Marsh, in his valuable paper read before the British Medical Association in July of last year, has led the way towards a better knowledge by recording a number of instances in which bony ankylosis had occurred independently of suppuration, some dependent upon rare conditions which have as yet received little attention, some upon tubercular and other lesions of a more familiar nature. It is in this manner we must look for advance of knowledge, and we must look in all directions.

Ankylosis is commonly regarded as a question of purely surgical interest, but it should not be so; for some of the most interesting contributions towards a new and broader study will come from physicians, whose experience brings them in contact with cases, often of great complexity, which may never reach the surgical ward or consulting room. If we are to learn the subject as a whole, our survey must be as wide as possible, and we must record with especial care every example that appears difficult to understand. When the accumulated material is sufficiently large we may hope to fill up many, if not all of the gaps in our pathological knowledge.

It is not desirable to separate fibrous and osseous ankylosis in our inquiry, because the same causes may lead to either, or the first may undergo conversion into the second; moreover, it is difficult to diagnose between the two until the parts are examined under an anæsthetic, or exposed by the knife.

I shall venture to offer a tentative classification of the group of non-suppurative ankyloses, with some remarks under each heading. It leaves much for subsequent addition and correction, but it may serve as a basis for present discussion.

We may define "true" ankylosis as a more or less complete suppression of the normal mobility of a joint, due either to union of the opposed articular surfaces of fibrous or osseous tissue, or to changes in the capsular structures, or to a combination of these two conditions. Suppuration may play a part in any of the groups, but it is only with cases in which no evidence of pus formation is present that I propose to deal on this occasion. Conditions of "false" ankylosis, dependent upon causes lying outside the joint structures, will also be omitted from consideration.

It must of course be understood that the degree of limitation of movement that justifies the use of the term "ankylosis" is still unfixed; for while in the first group bony ankylosis leads to complete annihilation of motion, and fibrous ankylosis may be little less absolute, in the second group certain changes in the capsular structures may induce every possible degree of interference with the normal range of mobility, from a scarcely perceptible diminution to a complete suppression, and there must necessarily be a point at which the surgeon would cease to employ the word "ankylosis" at all. The difficulty, however, is rather academical than practical, and may be neglected.

1. THE INFLAMMATORY FORMS may be grouped according to their causation as follows:—(α) due to mechanical injuries; (β) due to local irritation set up by toxic elements conveyed by the circulation; and (γ) due to various affections of the nervous system. In the first and second groups, evidence of suppuration may or may not be present; the third is essentially non-suppurative.

(α) *From mechanical injuries.*—The injuries include severe contusions of joint surfaces, fractures into a joint, a variety of other accidental lesions that need not be specified, and lastly, surgical operations.

Cases of ankylosis from simple contusion are comparatively rare; but it is certain that such an injury, even in a comparatively healthy subject, may set up changes which may end in fibrous or even in bony union of the articular surfaces. Mr. Howard Marsh has related a case of bony ankylosis of the temporo-maxillary articulation caused by a heavy fall upon the chin, and the following case

may be taken as a type of a condition of fibrous ankylosis, which in the hip may closely simulate the osseous form.

The patient, a boy aged 18, was admitted into St. Thomas's Hospital in September, 1894, with a contusion of the right hip, caused by a fall from a height of ten feet upon the trochanter. He appears to have been a fairly healthy subject before the accident.

On admission the joint was painful and swollen, but freely moveable, and there was some febrile disturbance, the temperature reaching a maximum of 101°, but fluctuating considerably. At the end of thirteen days the symptoms subsided, and he left the hospital apparently well except for a slight limp on walking. After his discharge the imperfection of gait persisted, and the joint remained subject to occasional attacks of pain, which, however, did not prevent the patient from following his occupation; but gradually the stiffness increased, and at the end of a twelvemonth the joint had become absolutely rigid. He was readmitted on the 13th of February last. There was neither pain nor swelling about the articulation, but the movements, voluntary and passive, were completely lost, and the joint surfaces appeared to be united by bone. The thigh was fixed in a position of adduction (30°) and flexion (15°). Under an anæsthetic it was found that the ankylosis yielded to strong manipulation, and the thigh could then be moved to a limited degree in all directions. The gain, however, was not preserved, although persevering efforts were made to keep up the movements by manipulation, aided from time to time by chloroform, and at the present time the fixation of the hip is to all intents and purposes as complete as though an osseous ankylosis had occurred. In this case arthritis had been set up by the contusion of the surfaces, and the movements of the articulation, being painful, had been unconsciously suppressed by the patient until the two opposed surfaces had become firmly united by fibrous adhesions; adaptive changes had simultaneously taken place in the capsular structures, and the function of the joint was permanently destroyed. It is possible that the fibrous uniting material may eventually become bony. In a similar case, two years ago, it was necessary to perform osteotomy in order to rectify the inconvenient position assumed by the limb, and the consequent spinal deformity.

(β) Both suppurative and non-suppurative ankylosis may be set up by the local action of toxic elements conveyed by the blood.

They may arise from various *septicæmic conditions* in connection with typhoid fever, scarlet fever, &c. *Gonorrhœal arthritis* may also lead to a permanent ankylosis. I have now under observation a patient whose elbow is rigidly fixed at right angles as a result of gonorrhœal "rheumatism," in spite of repeated efforts to restore the function of the joint by passive movements. *Rheumatism* is a well-known and potent cause of non-suppurative ankylosis which may end in bony union of the surfaces. Mr. Bennett's case of osseous ankylosis of the temporo-maxillary articulation, brought before the Clinical Society a few years ago, may be taken as a type of the condition; but it is possible that many cases of ankylosis preceded by joint effusions of a very different origin have been wrongly assigned to the great "universal provider" of joint pains. *Gouty ankylosis* is better known to the physician than the surgeon, as few cases apply for surgical treatment. *Tubercular arthritis* is the most common cause of ankylosis preceded by suppuration, and, as Mr. Howard Marsh has shown, it may lead to complete bony union of the joint surfaces without any evidence of pus formation. I have notes of three cases of the kind. It must, however, be remembered that pus formation is not always accompanied by visible signs of its presence or followed by external discharge. Lastly, a *syphilitic arthritis* must be accepted as a possible cause of ankylosis, but the termination is a rare one, and I have not yet been able to find records of any examples of it.

(γ) Ankyloses of inflammatory origin due to affections of the nervous system are less familiar than those of the preceding groups. *Charcot's disease* is said to give rise to bony ankylosis without suppuration, but the specimens that have been shown, all of foot bones, leave it doubtful whether the changes may not have been induced by pyogenic organisms admitted through a perforating ulcer. In a case under my own observation, where ankylosis had undoubtedly occurred, the integuments appeared to be entire, but on close examination the scar of a perforating ulcer was found under the metatarso-phalangeal joint of the great toe, and the first phalanx of the toe had become almost completely removed by a quiet process of disintegration and absorption that had not even attracted the attention of the patient.

In *chronic osteo-arthritis* (accepting this as a disease of nervous origin) ankylosis undoubtedly happens, but only, I believe, in an indirect way, by a process of ossification extending along the liga-

ments, or more rarely by fusion of osteophytes. A joint embarrassment which may simulate ankylosis is not infrequently induced by contact of osteophytic growth from opposed bones, but the growths seldom fuse. In the vertebral column, however, both processes, ligamentary ossification and fusion of osteophytes, may be met with, and as a secondary process the intervertebral discs may be replaced by bone.

The *division of a nerve* may possibly lead to joint effusions and ankylosis. Mr. Bowlby reports a case of section of the median nerve in which the joints became contracted and stiff, and one of the interphalangeal articulations was obliterated by bony union of the opposed surfaces. This occurrence is so exceptional, that one is tempted to attribute the ankylosis to some intercurrent disease of different origin, but the evidence offered by the case to be presently quoted tends to support the other view.

Acute peripheral neuritis may apparently induce arthropathic troubles not unlike those just related. A case was brought before the Medical Society by myself in 1894,[1] which can scarcely be explained on any other hypothesis. Its main features are as follows.

The patient, a boy of fifteen, was attacked, after a hard day's skating, with fever, accompanied by severe pains in the legs and effusion into all the joints of both lower extremities, from the hips to the toes, those of the rest of the body remaining intact. The acute signs were followed by ankylosis of the affected joints, the toes becoming fixed in a position of flexion at the phalangeal joints, the rest of the articulations in extension. A few weeks later it was seen that the joint lesions were accompanied by a well-marked atrophy of the skin of the lower limbs, with transverse *lineæ atrophicæ* and extreme degeneration of certain groups of leg muscles. There were no signs of cardiac disease, and no history of rheumatism in the patient or in his family. Under long and persevering use of massage, galvanism, and passive movements, the joints slowly regained the greater part of their mobility, and the patient made a fairly complete recovery without disablement, but not until more than two years after the beginning of the attack.

I believe that the pathology of this condition is best explained on the hypothesis of an acute peripheral neuritis determined by the combined influences of the lowering of temperature in the limbs by cold, and the functional overtax upon the neuro-mus-

[1] 'Transactions of the Medical Society,' vol. xvii, p. 104.

cular apparatus by the prolonged exertion in skating. This view is supported by the limitation of the affection to the joints of the lower limbs, the presence of atrophy and impaired sensation in the skin, and the wasting and degenerative reactions of certain groups of muscles. The contraction, effusion, and ankylosis bore considerable resemblance to the changes in Mr. Bowlby's case, and it is probable that the ankylosis would have eventually become bony in some of the joints had not energetic local treatment been adopted.

2. THE DEGENERATIVE FORMS of ankylosis may depend upon ossification of ligaments, and upon forcible and long-continued pressure of opposed articular surfaces against each other.

(α) *Ossification of ligaments* may be seen in the vertebral column, and in the tarsal and carpal bones. It is usually a result of chronic osteo-arthritis, but sometimes occurs in cases where there is no evidence of this complaint. Most of the preparations in our museums show osteophytic formations, and it is from these that the ligamentous degeneration appears to start; but in a few there are no osteophytic prominences, and we are left in doubt whether they have ever existed, or whether they have disappeared by absorption as a natural result of the loss of movement in the articulation. Dr. Hilton Fagge's case, recorded in the 'Transactions of the Pathological Society' (vol. xxviii, p. 203), was probably an example of ossification of ligaments, and the softening of the bones noted as a special feature of the condition may have been only secondary to disease.

(β) Forcible and long-continued *compression of opposed articular surfaces* against each other may lead to the disappearance of cartilage and fusion of bones. Mr. Arbuthnot Lane has described cases of ankylosis of the cervical vertebræ in porters who carry weights on their heads; and Mr. Bland Sutton refers to analogous conditions in oxen which are yoked by the horns. The ankylosis taking place in extreme *lateral curvature* along the concave side of the spinal column is probably of the same nature, and is a sequel to the absorption of cartilage and direct contact of bony surfaces.

(γ) With these we may, perhaps, include as a degenerative process the adaptive rigidity of joints developed as a result of long-continued immobilisation, which also complicates joint diseases of an inflammatory nature.

3. Lastly, there are various obscure conditions, possibly of neurotic origin, which cannot at present be classified. The experience neces-

sary for a better comprehension of the group can only be arrived at by a publication of all examples with which we may be thrown into contact, and it is as a contribution to this record that I bring forward the following case.

The patient, who is in attendance for examination, is a man aged 30, of nervous temperament and slender configuration, free from any signs of inherited disease. He has been the subject since the age of ten of a series of subacute articular lesions arising without apparent cause, and terminating in fibrous or osseous ankylosis of the joints attacked.

During the first ten years of his life he was strong and active, and had suffered only from the ordinary illnesses of childhood. There was no history of gout, rheumatism, tuberculosis, or syphilis in his family.

At the age of ten his right wrist became swollen and painful without apparent cause. The symptoms, however, were of little severity, and unattended by constitutional disturbance. After some weeks of treatment at a neighbouring hospital the swelling subsided, leaving an ankylosis of the radio-carpal articulation, but free intercarpal movement. A year later the right knee was similarly attacked, and after a long course of unavailing treatment it became contracted and rigidly fixed at an angle of 50° by bony ankylosis involving the femur, patella, and tibia. In the following year (at the age of twelve) the right ankle and tarsal joints were affected, leaving very slight movement in the former, and apparently consolidating the whole of the tarsus and the bases of the metatarsal bones. About the same time the right middle finger became partially paralysed, and ceased to grow in proportion to the rest of the hand. At the age of thirteen the left elbow was affected, and at fifteen the right elbow, leaving in both cases fibrous ankylosis (at right angles) with only 5 to 10 degrees of movement, but not interfering with radio-ulnar rotation. At sixteen the left wrist followed suit, the radio-carpal joint apparently undergoing bony union, while the intercarpal joins remained intact.

At the age of eighteen an eversion of both great toes was noticed, the right toe eventually forming a right angle with the metatarsal bone, and this distortion seems to have occurred independently of mechanical compression, as the patient says that his boots had always been roomy and square-toed. In the next year the right shoulder succumbed after a slight overstrain in carrying a heavy

trunk, and bony ankylosis followed. Since that time he has suffered only from lesser manifestations, but is perhaps not yet at the end of his troubles. The first phalangeal joints of both ring fingers became affected (the right at the age of twenty-three, and the left at twenty-eight), losing, however, about 10° of movement, and a few months ago tenderness and swelling appeared in the first phalangeal joint of the left little finger, but no ankylosis has yet set in. Finally, during the past fortnight the right shoulder has become painful and tender. In addition to the more recent joint lesions, about two years ago signs of vaso-motor paralysis appeared in the right leg, and the limb has since been perspiring profusely, and is very susceptible to changes of temperature.

The man was sent into St. Thomas's Hospital in March, 1895, for amputation of the useless left leg, deformed by the contraction of the knee and a severe hallux valgus. The knee was, however, straightened by a cuneiform osteotomy, and the toe by a resection of the head of the metatarsal bone, and the limb is now a useful one.

The angular piece of bone removed from the knee included the patella, and the osseous texture was noticed to be unnaturally hard and resistent to the saw. No sign of the original joint fissure was apparent.

The ankylosed joints are free from tenderness or swelling; they present no osteophytic formations, and the slight movement possible in some of the affected articulations is quite painless. The muscles acting upon the joints are of course atrophied in proportion to the degree of suppression of function. The patient shows no ataxic symptoms, and all the functions apart from locomotion appear to be normal.

Here, then, is an example of a disease affecting several joints at varying intervals extending over a period of twenty years, each attack beginning with a moderate degree of swelling and pain in the articulation, but without constitutional disturbance, and always (excepting the joints most recently affected) terminating in fibrous or bony ankylosis. No clue has been found to the origin of the inflammatory process. There is no evidence of inherited disease, and although the onset of each attack bore some resemblance to subacute rheumatism, it would be unsafe, in view of the history, course, and termination, to assume that the affection was truly rheumatic. There are, moreover, certain elements in the patient's condition

pointing to a neurosis as a possible cause, such as the semi-paralytic and stunted finger, and the vaso-motor paralysis of the right leg, and to these may be added the nervous excitability of the patient; but I can only ask the help of the Society in deciding the nature of the case. The sole recorded example I have been able to trace that bears any resemblance to it is one quoted by Mr. Howard Marsh from notes lent to him by Dr. Griffiths of Cambridge. It is to be hoped that we may have the advantage of hearing more of this case from Dr. Griffiths.

Sir GEORGE M. HUMPHRY said: I shall limit my remarks to those instances of osseous ankylosis without suppuration occurring around the joints. The form of ankylosis which results from ossification extending from the exterior of the joint may be termed *external* ankylosis, as distinguished from *internal* ankylosis, in which the disease spreads from the inside of the joint. This external ankylosis, which consists of the ossification of the ligamentous tissues, is dependent evidently on some abnormal and excited condition of the bone cells occupying the intervals between the fibres of the ligamentous attachments to the bones. These periosteal corpuscles are liable to undergo abnormal action. Their normal action varies a good deal at different periods of life. It is due to the action of these corpuscles that we have the ridges, the irregularities, and processes of bone which occur at the points of attachment of ligaments and tendons. These ridges are well marked in the anterior inter-trochanteric line, in the surface of the bone at the attachment of the masseter on the lower jaw, and in the ridges on the ventral aspect of the scapula. This condition, causing irregularity and ridging, is continued sometimes to an abnormal extent, and may result in bony processes passing between, or among, or into the ligamentous tissues at the attachment of tendons and ligaments to the bone, such as is seen in that remarkable specimen at the Royal College of Surgeons, in which there is ossification of the fibrous and muscular tissues spreading from the bones, and having origin doubtless in these bone corpuscles owing to some peculiar condition or set of conditions. Now this condition of osseous union of the fibrous tissues on the exterior of the joint has its normal occurrence under developmental laws in the case of the sacrum, where the several vertebræ are united together by means of this process. It is also present in the normal ankylosis

occurring in the pre-sphenoid, the post-sphenoid, and the spheno-occipital centres. This process is regulated by developmental laws, and it very rarely goes beyond its normal limits. It is the extension of this condition that is so liable to affect the whole or parts of the vertebral column, and these specimens described by Dr. Griffiths are in almost all cases instances in which the bone corpuscles at the margins of the vertebræ have spread through the connecting fibrous tissues and have united the vertebræ. He has also mentioned the frequency of union of the neural arches, and that is a very remarkable fact. It is a matter of common occurrence in the instances which he has mentioned, viz. in a large number of lateral curves; and in antero-posterior curves you often find the arches united, and probably also the articular processes. Now these arches are united obviously by the spread of this ossifying process through the ligamenta subflava from arch to arch. Why this should so often affect the arches I am unable to say. It is usual to see it where the fibrous structure is subject to some amount of stretching, as in antero-posterior curves, where the ligamenta subflava are put somewhat on the stretch; and this stretching probably stimulates the bone corpuscles on the lines of the attachment of the arches, and causes the ankylosis to take place. This external ankylosis, therefore, of joints is only part of a very large and wide subject; it is only a part of the result of the general tendency of bone corpuscles to spread through fibrous tissues under various circumstances and in various parts of the body; and if I have to give a name to it I will call it "fibrous ossification," *ossificatio fibrosa*, not limiting the name of this process to joints, but regarding this affection of the joints as part of a general tendency in the various fibrous tissues attached to bone. Now the process by which the actual ankylosis of the joint takes place in this affection is interesting. The first change which takes place is the spread of ossification along the margins of the articular surfaces on the opposite sides across the joint, fusing and uniting the opposite margins together and constituting a bony bond of union. When this union has taken place (and the changes are well shown in this specimen of ankylosis of the foot which Dr. Griffiths has shown),—when this has taken place, and when the joint therefore is entirely useless, with the articular surfaces fixed immoveably to one another, then, as is usually the case, the articular cartilages, having no longer any function, disappear. By what process they disappear I do not know,

but, disappearing, they leave the layer of cartilage-bone which subtends their structure. You now have the joint bound together on the surface by ossification of the ligaments, and you can see that the interior of the joint is free, and that it is lined internally by a layer of this articular lamella or cartilage-bone. The next process is that this lamella gradually undergoes absorption and disappears at points; through these points shoot up little bone-processes from the subjacent cancellous tissue, and these meeting on opposite sides coalesce, and in this manner gradually the articular lamellæ are entirely removed, and their places in the joint are occupied by the cancellous tissue formed from the bone-processes which have shot across the joint and have established a continuity between the cancellous tissue on the two sides of the joint, in some instances so complete that the original line of the joint is scarcely discernible. Thus the *internal* or direct articular non-suppurative ankylosis is a natural sequence of the *external* ankylosis or fibrous ossification, and is commonly a result of it, and is also commonly associated with ossification of the fibrous tissues near by, and, indeed, in various parts of the body. What may be the cause that leads to this abnormal and excited condition of the bone corpuscles, which produces in some instances so much evil, I am unable to say; it seems to have a more near relation to a rheumatic affection than to any other. I cannot think it has any relation to Charcot's disease, and I cannot see any reason for attributing it under ordinary circumstances to nerve affection, there being, as a rule, no nerve affection present; and as far as I know there is no certain indication that nerve affection of the spine stimulates to this condition. I think the neural tendency is at present a little too strong upon the pathologist, who I think is on the whole not allowing sufficiently to the other tissues of the body the power of originating disease in themselves. Of course every process normal and morbid has its relation to nerve change, but I do not think that these cases have any more important relation to nerve change than have many other varieties of maladies.

Mr. Howard Marsh said: At various times cases have come under my observation in which, following chronic changes and without any sign of acute inflammation, and entirely apart from suppuration, osseous ankylosis has taken place.

(1) In illustration of ankylosis occurring without suppuration,

I would ask your attention to the case of a girl aged about fourteen, whose elbow-joint had gradually become stiff; there was no acute inflammation, and there was certainly no suppuration; but as the joint was fixed, and the limb was in a position of inconvenient extension, Mr. Walter Roughton of New Barnet excised it, and found, as will be seen in the specimen I hand round, that the olecranon and the humerus were fused together by healthy-looking bone. This appearance was confirmed by microscopical examination, which showed complete synostosis between the two bones. The case, I believe, was tuberculous, and as such it seemed to me one of some rarity; and I should like to ask Mr. Anderson if he has many similar specimens that he can show. A few months ago I had a patient under my care with tuberculous disease of the ankle-joint; there was pulpy degeneration of the synovial membrane, but no suppuration.

As the joint was disorganised, it was decided to perform a Syme's amputation. This was done, and when the specimen was afterwards examined, a section having been made through the tarsus, it was found that the astragalus and os calcis were absolutely fused together by bony tissue, except that a small part of the *tarsi canalis* was left unaffected by the process. Here is a specimen that is of some interest. It consists of the axis and the next cervical vertebra, and they are absolutely fused together in regard to their neural arches; the two bodies appear fused, but a longitudinal section having been made, it is seen that the intervertebral disc is not involved, and that fusion is due to ossification of the anterior and posterior ligaments only. These two vertebræ are fused together without any evidences of destructive disease or suppuration, the bodies are perfect in outline, and there is no sign of erosion. The specimen is without history, and I leave it to the Society to say what was the probable nature of the case, but I venture to think myself that the disease was probably tuberculous.

(2) Bony ankylosis without suppuration occurs not rarely in gout.

(3) It also is met with in gonorrhœal rheumatism.

(4) And in some cases of septicæmia.

(5) As to how often bony ankylosis occurs from contusion of a joint, I have no specimens to show, but I may mention a case in which a person fell on her chin, and, after much pain had been experienced in the temporo-maxillary articulation, the case ended by

the joint becoming perfectly stiff. I am inclined to think that in all probability bony ankylosis followed from the effect of the mere contusion, and I think it is a very important point. We are told that bony ankylosis sometimes follows rest, but I have always been at a loss to understand how that result can happen. It may be that in cases where a joint has been kept at rest, and ankylosis has followed, there has been an overlooked or forgotten contusion.

(6) These specimens I now show, one from the Royal College of Surgeons of England, and two from the museum of St. Thomas's Hospital, prove that in some cases of scoliosis there occurs a buttress of bone in the concavity of the curve, which seems to be similar to that which is formed in curved rickety bones; and I suppose the same cause may be alleged,—that compression of the bone causes irritation with the consequent inflammation and bony formation here shown.

(7) As regards the question of ankylosis without suppuration in Charcot's disease, examples can be produced in which bony ankylosis has occurred. But in such cases has the ankylosis followed suppuration connected with a perforating ulcer, or has it been developed without suppuration, and as a direct result of changes in the nervous system?

I myself have no case to show proving that ankylosis occurs in Charcot's disease without suppuration, but Charcot himself has described a tabetic foot in which the bones of the tarsus were the seat of this change. Between the tarsal bones there was osseous ankylosis, and also between the first and second metatarsals and the internal and middle cuneiform bones. Charcot expressly states that neither traumatism nor suppuration had been acting as a cause, and he remarks that we can only accept these changes, and also the ankylosis, as definite articular lesions following tabes. I think, with this evidence before us, we are justified in saying that very rarely Charcot's disease may lead to bony ankylosis without suppuration.

(8) Next as to cases of multiple ankylosis without suppuration. Some years ago a groom, 22 years of age, was in St. Bartholomew's Hospital, whose original illness occurred some four years previously, when he was said to have had acute rheumatism. At any rate, it was some acute illness, for it confined him to bed thirteen weeks, and left him very stiff and crippled. At first, when he became convalescent, he could walk about a little, but his power of locomotion gradually failed, and he became bedridden. On admission to

the hospital his thighs were flexed on his trunk, his knees were flexed, and his toes were pointed. The right knee-joint was excised, and the result will probably be accepted as a good one, for although the bones were in such a soft state, firm union, as the specimen shows, took place. I performed osteotomy of the right ankle, and in doing so found the joint was fixed by bone. Osteotomy below the trochanter of the right femur was subsequently performed. The patient was weakly and anæmic; and in the absence, at the time the case occurred, of an efficient antiseptic method, suppuration took place, and was followed by lardaceous disease, of which he died. On *post-mortem* examination it was found that all six of the large joints of the lower extremities were the seat of complete bony ankylosis. The specimens are here on the table. I have no explanation to offer of this case, and I shall be glad if any light can be thrown on its probable nature by subsequent speakers.

(9) Then here are some specimens of arthritic spondylitis. It seems to be quite agreed that bony ankylosis of the spine is not rare in elderly people. The anatomical appearances differ in different instances. There are several specimens here in which the bony union has been formed by the ossification of the anterior common ligament. But here is a specimen in which ossification has occurred in the ligaments between the neural arches and between the spines; ossification, however, has not occurred in the intervertebral discs. They have completely disappeared during maceration of the specimen, and the spaces between the vertebræ which they formerly occupied are clearly seen. I may say in conclusion that on microscopical examination ankylosis was proved to have been formed by the development of true bone in all the classes of cases I have mentioned.

These various cases may be grouped according to their causes, and I had intended to show that sometimes you might have as the cause an irritant such as the tubercle bacillus, or an infective micro-organism, as in gonorrhœal rheumatism and after parturition. In gout there must be some irritant acting as the cause, and I believe that there are some cases in which contusion is followed by bony ankylosis. Further, there seem to be other causes, such as Charcot's disease, and nerve injuries in which the nervous system is at fault. Finally, there are other groups in which ankylosis occurs without suppuration, the nature of which is at present obscure.

Mr. DAVIES-COLLEY said: One of the causes of ankylosis which Mr. Anderson has given is contusion. In relation to this I may mention the following case. A short time ago I had as a patient a boy, nine years of age, with stiffness of the lower jaw. The history he gave was that two years before he had been kicked by a horse under the chin, and that this had been followed by much pain in the jaw. When he came under my notice he was only able to separate his teeth half an inch, and I found the whole power of moving the jaw laterally and from before backwards was lost. I inferred, therefore, that ankylosis had taken place in the part of the temporo-mandibular joint above the fibro-cartilage, while the compartment below the cartilage had escaped.

The chief form of ankylosis without suppuration, however, to which I wish to call attention is that which occurs as the result of gonorrhœal rheumatism. There is a form of gonorrhœal rheumatism which seems to have escaped the notice of most observers. It is an acute form in which it would appear that the joint generally is not so much affected as the ligaments of the joint. The evidence of the restriction of the inflammation to these ligaments is the great redness and œdema over the joint which accompany this form of inflammation, showing that it is superficially situated. This kind of gonorrhœal rheumatism is quite different from the chronic form usually described by the authors who have written on this subject. It is found equally in both sexes, and whenever it occurs it produces much stiffness in the joint attacked. I allude to it now because I believe that the rare cases described as spondylitis deformans are generally the result of gonorrhœal rheumatism. The case shown to this Society by Dr. Fagge about twenty years ago was probably one of that nature, and if you will allow me I will pass the specimen round. It is from the museum of Guy's Hospital, and more directly illustrates the subject we are now considering. The patient was a young man of about thirty-four years of age, who came into the hospital with a round back and complete ankylosis of the dorsal spine, and he finally died from bronchitis. You will find that all the ligaments connecting the spines, the neural arches, and the articular processes are affected, but not the anterior and posterior common ligaments. I have looked up the history, and find that Dr. Fagge pointed out the absence of any signs of osteo-arthritis, and left the cause an open question, giving no opinion on the pathology of the case. My own opinion is, from

cases I have seen, from the history of cases of spondylitis deformans published in the proceedings of the Clinical Society, from the part of the spine affected, and from the age of the patient, that the ankylosis was probably due to gonorrhœal rheumatism. It is not stated in his history whether the man had gonorrhœa or not, but in nearly all the cases of spondylitis deformans, cases with ankylosis of the spine in the bent condition occurring in comparatively young people,—in nearly all these cases there is a history of gonorrhœa. Two such cases have come under my notice. One man I showed to the Society eleven years ago. He was about thirty-two years of age, and came to me with complete ankylosis of the ribs, the spine bent forward, no movement in the dorsal region, and little in the cervical region. Ten years before, this patient had been exposed to remarkable variations of temperature, being engaged in some cement works, where his duty was to take out the dried cement, after which he used to cool himself in the cold air outside. He was also at that time suffering from gonorrhœa. Severe pains came on in his back, and the disease gradually progressed until it culminated in this ankylosed condition, in which he came under my care. Two years ago another patient came under my care, having been sent to me as a case of caries of the spine. He was a man between thirty and forty years of age, and he was in almost precisely the same condition, with the characteristic round immoveable back; there was nearly complete immobility of the ribs, the dorsal spine was bowed, and there was a good deal of pain about the dorsal muscles running into the back of the neck and occiput, probably referable to pressure on the nerves passing through the intervertebral foramina. On inquiring into the probable causes of his condition, I found that he had been exposed to very great vicissitudes of temperature, to cold and damp, having had to lie out in the woods at night for weeks at a time, with his clothes dripping with dew when he awoke in the morning, and all this in a hot country. Bearing in mind those cases of spondylitis deformans of which I had heard and read, I asked if he had had a discharge, and he said that at that period he was constantly suffering from attacks of gonorrhœa, one after the other. The ankylosis in these cases appears to be in the posterior parts of the vertebræ, but the records of *post-mortem* examinations are scanty. I think there can be little doubt that gonorrhœa forms a considerable factor in the causation of this peculiar ankylosis of

the vertebræ, which is spoken of as spondylitis deformans. It should also be mentioned with respect to these two cases, that in one the father suffered from acute rheumatism, and in the other the father died from gout. It seems to me, therefore, that there are several factors concerned in the production of this form of ankylosis of the spine, the first in importance being probably gonorrhœal rheumatism. The second is a strong family tendency to arthritic disease. Thirdly, as far as I can judge from the two cases I have mentioned, another factor may be exposure to damp and extreme vicissitudes of heat and cold. The disease once started appears to progress after the gonorrhœa, which is its primary cause, has disappeared.[1]

Dr. GRIFFITHS (Cambridge) first remarked upon the frequency with which bony ankylosis without suppuration took place in the axial skeleton after injury. In one specimen shown, which was removed fourteen years after fracture dislocation, three vertebræ were united in their bodies, articular processes, and laminæ. Specimens illustrating fusion of atlas and occipital under like circumstances were also shown.

He next showed specimens illustrating bony ankylosis of the vertebræ in elderly persons. In some of these the bodies were held together by bridges and plates of dense, ivory-like bone; in others the opposed margins of the bodies had grown over and joined with one another; and in others still the intervertebral discs were completely converted into bone, or the cancellous tissue of one body had grown through the intervertebral disc to meet a similar growth from that opposite. In other specimens the articular processes were firmly ankylosed, and there was ossification of the *ligamenta subflava* and the interspinous ligaments. Thus each part except the pedicles of the vertebræ might become in elderly persons ankylosed to one another.

In lateral curvature it was, he said, not usual to find actual fusion of the distorted bodies, although there were frequently marginal growths on the bodies forming the concave side of the curve. In one specimen of extreme lateral curvature four of the lower dorsal vertebræ were completely fused by growth from one

[1] I ought to mention that I owe to Mr. Jonathan Hutchinson, who saw my first case when I showed it at the Pathological Society eleven years ago, the suggestion that it was due to gonorrhœal rheumatism.

body to another across the intervertebral disc—one of the discs being, however, independently ossified.

What he, however, specially wished to draw attention to was the occurrence of multiple bony ankylosis without suppuration. This condition was illustrated by specimens of hands and feet. Those of the hand showed complete fusion of several or of all the carpal bones joined above to the radius, and below to the bases of the metacarpal bones. On section through one of the specimens it was seen that the separate bones were so fused that the cancellous tissue of the one was directly continuous with that of the other. In the moist specimens shown some of the intercarpal joints were not yet obliterated, and in them the articular cartilage was very thin; the joint surfaces closely approximated and joined together here and there by delicate bands apparently composed of fibrous tissue. There were no changes in these joints that in any way resembled those observed in chronic rheumatoid or osteo-arthritis disease. In the specimens of feet which were exhibited, the intertarsal as well as several of the tarso-metatarsal and phalangeal joints were ankylosed by bone. On the exterior at the lines of the several joints there were ridges of spiculated bone which were more pronounced where the bony union was in progress. Where the union was quite complete the external outgrowths of bone gradually disappeared, until at last the line of junction of two adjacent bones was left completely smooth. On longitudinal section through one of the feet, including os calcis, astragalus, scaphoid, internal cuneiform, and the first metatarsal, it was seen that the process of union takes place at first near the periphery of the joint, and gradually this extends centralwards as the articular surfaces themselves become approximated from the thinning and absorption of the articular cartilages. Having pointed out the peculiar features of this arthritic disease—features that are unlike any hitherto described disease—he suggested that it might be called ossifying arthritis (arthritis ossificans).

After this he briefly referred to cases that he had then under his care of this peculiar arthritic affection, and said that although they were all very chronic in their nature, and insidious in their mode of onset, attacking almost every joint in the body, yet there were some in which disease ran a subacute course. In cases that run a subacute course the joint becomes swelled, very painful, and fixed; after six weeks or so the swelling gradually diminishes, leaving the

joint fixed—the joint being completely obliterated, and the two articular ends grown into one another. In the chronic cases the joint becomes fixed and painful until the bones grow together, and the joint is obliterated. Doubtless the condition known as *spondylitis deformans* is closely allied to, if not identical with, that met with in the above class of cases.

In conclusion, he showed several specimens of the natural form of bony ankylosis without suppuration that takes place between the second and terminal phalanges of the little toe of middle-aged persons. The process by means of which the ankylosis occurs here is probably identical with that seen in ossifying arthritis.

Mr. D'Arcy Power said: I show as my contribution to this discussion the bones of a right elbow-joint in which there has been complete and smooth bony ankylosis. The specimen (No. 643) has been for a long time in the museum of St. Bartholomew's Hospital, but it is unfortunately without a history. The elbow is flexed at an angle of 120°, and the bones of the forearm are somewhat inclined to pronation, as if the arm had been kept in an angular splint supported by a sling, with the thumb pointing towards the body.

The head of the radius is partially displaced outwards, so that its outer edge is a little more prominent than the external condyle of the humerus, but this displacement I believe to be a secondary change. The ulna maintains its normal relation to the humerus. There is complete bony union between the humerus, the radius, and the ulna, the radius and the ulna being themselves firmly united together by bone. The deposit of bone is perfectly smooth, and is of uniform density. It has not been associated with any suppuration, nor has there been any irregular osteoplastic periostitis. The bony change is limited to the articular surfaces, and has not extended over the whole area covered by the synovial membrane, for the olecranon fossa is normal. The diaphyses of the bones consist of good compact bone, and the markings of the muscles are well defined.

I have also seen a case of multiple ankylosis like that described by Dr. Joseph Griffiths and other speakers. It occurred in the wife of a gentleman in good position. At the age of thirty her joints gradually began to stiffen until, when she died at sixty, every joint, with the exception of her lower jaw, appeared to be firmly

ankylosed. There was not the slightest reason to suspect that this case was gonorrhœal in origin; her husband was under my care for the treatment of a hydrocele, and I am indebted to him for the following details of the case.

L. G— was married at 28, and was delivered of two healthy children in due course. She suffered during her third pregnancy, when she was about thirty, from general "rheumatic pains." These increased, and the joints of her fingers became swollen, tender, and stiff, so that it was soon impossible for her to write, whilst her finger-nails became so long and curved that they were unsightly, painful, and brittle. Similar changes then occurred in her feet, whilst her legs and ankles became so stiff that she had great difficulty in getting up and down stairs. The shoulders and elbows afterwards became involved, whilst the movement of the jaws was greatly impeded. Her teeth remained good, and she never lost any.

The progress of the disease was extremely slow, and from year to year the only obvious change was an increasing amount of flexion at the joints and increasing limitation of the movement. The movements of the head were greatly impaired, and she suffered for a long time before her death from an urgent desire to live upon a hill-top. This desire I attribute to a deficient aëration of the blood caused by defective movements of the thorax in respiration. Pain was a constant and very severe symptom during the whole course of the disease, and it was greatly aggravated by movement. During the later years of her life there was marked ulnar deflection of the hands, whilst the fingers became twisted one over the other. The feet were distorted into a condition of varus, the soles looking towards each other. Both feet were greatly enlarged, apparently as a result of a chronic lymphangitis, and they were always intensely painful. There were many signs of trophic disturbance in addition to the "craggy" nails. The skin over the affected joints was glossy, and five or six years before her death the cornea of the right eye was infiltrated with pus, whilst the left eye was watery and congested. Both eyes eventually melted away, and for four or five years before her death she was quite blind, losing even perception of light. She was hard of hearing, but was never quite deaf, and she had great difficulty in articulation. She preserved her sense of taste, and her appetite and digestion remained good, for she always had her meals sent to her from the general dinner-table.

Her mental faculties remained clear and were unimpaired until the moment of her death, which occurred from syncope about thirty years after the commencement of her illness.

The lady was an orphan, and no details are forthcoming about her family history, except that her father, who retired from business rather early in life, was an invalid for many years before his death, and she remembered that his joints were rubbed with various embrocations. Her brother, though delicate and sometimes suffering from pains in his joints, is able to do his life's work. Her children, five in number, are all strong and healthy, with the exception of one daughter who died at the age of twenty years after a few months' illness of Bright's disease, due to no assignable cause.

Mr. C. A. Morton referred to an obscure case of multiple ankylosis which had been under his care. The patient was a woman aged thirty-one. She was free from any joint troubles until the age of twenty-three, when some of the joints began to swell and pain her. The first joints affected were those of the fingers and ankles, and they were attacked simultaneously. All the joints affected later became so within six months of the onset of the joint trouble. All the joints in both upper limbs and the knees and ankles in the lower limbs were attacked. They became swollen and very painful, and then the stiffness came on a year after the commencement of the pain and swelling, first in one joint, then in another. For seven years before admission she had been unable to dress herself. For four years the knees were very much flexed and fixed, so that until three years ago (when they were straightened under an anæsthetic) she was also unable to walk. The right leg had remained straight, but the knee was ankylosed; on the left side there was free movement in the knee-joint. She could walk from room to room, but could not do more than this on account of pain in the hips and left ankle. She could not use crutches because she was unable to grasp them with her arms. She could feed herself and could write, but got aching pain in the arm after the latter. From the age of two to seven years she suffered from disease of the bones of the third finger of the left hand, and the finger was amputated when she was seven years old. From this time until she was twenty-one she suffered from a skin disease in the same forearm and arm, which has left large scars in the skin (? lupus). There was no family history of any form of joint disease.

When seen by Mr. Morton there was considerable pain in the joints of the fingers and thumbs of both hands and the right shoulder. There was very marked grating in many of the joints of the fingers, but movement in these joints only gave rise to slight pain. A tendency to hyper-extension existed at the joints between the first and second phalanges in the two middle fingers. Both little fingers were hyper-extended at the metacarpo-phalangeal joints, so that the head of the metacarpal bone was felt prominently in the palm, as the phalanx was partly dislocated backwards. The middle joints of the affected fingers were slightly enlarged. Small osteophytic nodules could be felt on the base of the second phalanx of the middle finger and on the dorsal surface of the base of the first phalanx of the thumb of the right hand. The fingers of both hands were markedly deviated to the ulnar side.

Condition of upper extremities.—Right side: muscles of hand, forearm, and arm much wasted, especially those of thenar eminence. No movement possible in wrist. Elbow could be almost fully flexed, but not extended beyond a right angle. Forearm fixed in position of semi-pronation; further pronation was almost, and supination quite, impossible. Marked grating over radio-humeral joint. The shoulder-joint was completely ankylosed, all movement at the shoulder being scapular.

Left side: movement in wrist very limited, and accompanied by marked grating. Elbow completely ankylosed at a right angle to upper arm. Shoulder also completely ankylosed. Complete pronation was possible, but supination was very limited. There was marked grating over the radio-humeral joint.

Temporo-maxillary joints unaffected, though six years ago she had pain in them on mastication.

Lower extremities.—Free painless movement in hips. Knees: right, extended and completely ankylosed; left, free painless movement. Both ankles stiff, with grating on movement, but only pain on movement in the left. After walking the left foot became hyperflexed at the ankle-joint, so that she could not continue to walk.

There was marked grating in the joints of both great toes, and the heads of the metatarsal bones were enlarged, and the last two joints hyper-extended. There had been a frequent painful shedding of the nail of the left great toe.

On January 11th, under ether, the adhesions in the left wrist,

elbow, and shoulder were broken down. Complete flexion and almost complete extension became possible at the elbow (which before was fixed at a right angle). The adhesions broke with a loud snap. The joint then grated very much, and lateral movement became possible, but no actual dislocation occurred.

A month later (February 8th) the joints in the upper limbs were dealt with in the same way. Adhesions were felt to give way slowly in all, and the possibility of movement in all directions was restored.

Although movement was continued both with and without anæsthesia in all the joints, they very quickly became as fixed as before; the only improvement which lasted was in the left wrist.

Mr. Jackson Clarke showed a specimen of commencing ankylosis of the ankle and tarsal joints in a foot which had been œdematous for four years. He said: The specimen[1] to which I would beg attention is of the simplest character, but it has the advantage of possessing a definite history. It comprises the astragalus and calcaneum of a right foot. The tibial surface of the astragalus shows a patchy denudation of the articular cartilage, the exposed bone being rarefied as if by caries. In the recent state the bared patches were joined to corresponding areas of the tibia by fibro-vascular tissue. The remaining portions of the articular cartilage on the tibial and malleolar surfaces of the astragalus are somewhat roughened, and in the recent state were covered with a thin layer of soft granulation tissue. The articular cartilage of the posterior astragalo-calcaneal joint presents a central portion which is thinned and riddled by minute close-set perforations. In the recent state these perforations gave passage to granulations which joined the bones together. The remaining tarsal joints contained each a thin plate of lymph which intervened between the articular surfaces. Thus the specimen shows that there has been in the ankle-joint early fibrous ankylosis, and in the astragalo-calcaneal joint an earlier step in the process which leads up to fibrous ankylosis; moreover in the remaining joints the lymph derived from coagulation of plastic effusion may be taken as an indication that the conditions for the production of ankylosis had been in operation in respect to them also.

The history is briefly this: The bones were removed from a foot

[1] St. Mary's Hospital Museum, No. 399.

and lower part of the leg which had been amputated by Mr. Edmund Owen. The patient was a strong middle-aged man, who was well until he sustained a comminuted compound fracture of both bones at the middle of the right leg. About three inches of the tibia underwent necrosis and came away. At the end of six months there was only fibrous union, although the limb was fixed with back and side splints. During this time and the rest of the course of the case there was persistent œdema of the leg and foot below the seat of injury, owing in all probability to thrombosis of the deep veins. The limb was next put up in plaster, and this treatment continued for two years, but still with the same result. The fracture was then exposed, the adjoining surfaces of the tibial fragments were freshened, and immobilisation kept up for another year, at the end of which there was still no bony union. The patient was then sent to St. Mary's Hospital, and admitted under Mr. Owen, who excised a portion of the fibula, freshened the ends of the tibia, and joined the latter by a thick silver suture after drilling the fragments. This operation was found at the end of six months to have failed, and since the limb was still œdematous, painful, and useless, it was removed.

The specimen shows what has occurred in the joints of the ankle and tarsus after four years of immobilisation of joints in a congested and œdematous state owing to venous obstruction. There was never any suppuration or cellulitis of the foot during the course of the case, nor on examination of the amputated limb was there found any change in the soft parts of the foot beyond a general firm œdema.

Mr. Targett showed the following specimens from the Museums of the Royal College of Surgeons, and of Guy's Hospital. They illustrated rare forms of non-suppurative ankylosis of joints.

No. 1922 (R. C. S. Museum).—Ankylosis of a carpal joint from Charcot's disease of the wrist.

There is destruction of the wrist-joint and extreme wasting of the carpal bones. The os magnum is firmly ankylosed to the base of the middle metacarpal bone, but there is no new formation of bone. It was taken from a bedridden woman aged 60, who presented the characteristic features of Charcot's joint disease in most of the large articulations. The symptoms of disease had existed eight years, and there was no evidence of past suppuration about the joints.

No. 1949 (R. C. S. Museum).—Osseous ankylosis of the left temporo-maxillary joint, which had existed for more than fifty years.

There is complete obliteration of the left joint, but the suture between the great wing of the sphenoid and the squamosal persists. Beside deformities of the teeth, there is a long process of bone on the site of the genial tubercles.

Nos. 1011 and 1070 (Guy's Hosp. Museum).—Bilateral ankylosis of the jaw with ankylosis of the occiput and cervical spine.

The specimens consist of the skull and upper portion of the cervical spine. In the former the jaws are tightly closed and fixed by osseous ankylosis of both temporo-maxillary joints. There is no deformity or lateral deviation of the lower jaw. The full number of teeth are present; these are quite sound, and are not worn in any special manner. There is a triangular gap between the roots of the two upper central incisors, but there is nothing to show that this aperture was used for feeding purposes. A vertical section through the left joint shows that the head of the condyloid process and the glenoid fossa are welded in the most perfect manner; the osseous tissue on section is of ivory-like density, and the line of union can with difficulty be discerned. Though the condyloid process is undoubtedly enlarged, yet there is not much formation of bone at the periphery of the original joint. Presumably the articular cartilage was rapidly destroyed while little or no movement of the jaw was permitted; hence the joint cavity was soon effaced. The appearances of the right joint are precisely similar from the outside, but the parts have not been sawn through. The condyloid process is enlarged chiefly by a deposit of bone upon its inner and anterior surfaces. With this exception the outline of the temporo-maxillary "articulation" is normal, but there is no joint. The articular surfaces of the occipital condyles are roughened, and seem to have been forcibly separated from the corresponding articular processes of the atlas. The margins of both these joints are covered with bony outgrowths, and probably there was incomplete osseous ankylosis of the occiput and atlas during life. The axis and the three succeeding cervical vertebræ are ankylosed by ossification of the ligamenta subflava, by osteophytes from the adjacent edges of the bodies, and by ankylosis of the joints between the articular processes. The odontoid process is roughened and somewhat enlarged near its apex, but there is no

warranty for the statement in the Museum Catalogue that it "encroached on the spinal canal, and compressed the cord." Moreover, the attachments of the transverse ligament are not involved in the area of disease.

Clinical history.—The patient was a black man, a native of Jamaica, who was admitted into Guy's Hospital under Dr. Richard Bright on October 12th, 1825. Three years previously he slipped down three or four steps into the cabin of a sloop, and in the fall ran a fork to a very small depth into the back of his neck. He felt no inconvenience afterwards, but about sixteen months before admission he felt pain in various parts of his limbs, and frequently he was unable to move his arms and legs freely.

On admission.—He had a little cough and complained of pain at the lower end of the lumbar spine. The head was always bent forwards so that the chin approached the top of the sternum. He could nod his head a little, but not turn it.

At the end of December, 1825, he was seized with stiffness and pains in the feet, so that he became unable to walk and almost unable to use his arms. There were also pains in the muscles of the neck and shoulders which had been increasing for some weeks, and these regions were very tender on pressure, but there was no loss of sensation in any part. Micturition and defæcation remained normal. It was thought that his speech had become less distinct. Pulse 100, rather weak. On attempting to walk, the toes were turned inwards in an unnatural manner.

At the beginning of March, 1826, it was noted that there was very limited mobility of the lower jaw. This condition rapidly got worse, so that a fortnight later the jaw was absolutely locked, and nourishment could be taken only by sucking it between the teeth. He died on March 23rd, 1826.

Autopsy.—Body emaciated. The cranium was rather thick, and there was an excess of subarachnoid fluid. The brain appeared to be healthy, though the optic thalami and corpora striata showed some reddish mottling, and the membranes were very firmly adherent around the medulla oblongata. The occiput, atlas, and axis were ankylosed as described above, while the temporo-maxillary articulations were similarly affected on both sides. The soft parts did not appear to be at all diseased in the neighbourhood of *any* of the affected joints. Lungs somewhat œdematous, though crepitant, and free from carbonaceous deposit. "Minute miliary tubercles were

scattered through their substance, which even in the immediate vicinity of these bodies did not appear to be the subject of inflammation or any other morbid change." There was nothing noteworthy in the other viscera. In the muscles of the legs, which were rigid, there was some extravasation of blood.

No. 2104 (R. C. S. Museum).—Ankylosis of spine in extreme lateral curvature.

The specimen consists of seven vertebræ from the upper end of the thoracic region, and is remarkable in that many of the joints between the articular processes on *both* sides of the vertebral column are firmly ankylosed. The bodies are united by means of a curved ridge of bone running along the concavity of the spine, and the vascular foramina for the bodies are in the hollow of this curve behind the ridge. Four vertebræ are chiefly involved in the curvature, which is so sharp that its concave or left border measures only 1½ inches, while the convex border is 4½ inches long. Each vertebra is thus wedge-shaped, with its base to the right or convex border of the curve. The costo-vertebral and costo-transverse joints are deformed but not ankylosed. The ligamenta subflava of the four or five vertebræ which are involved in the curve show complete ossification on the concave side only. The interspinous ligaments are not affected. The bones are small, and are probably those of a young adult.

No. 2050 (R. C. S. Museum).—Complete ankylosis of spine, pelvis, and ribs (spondylitis ossificans).

The preparation shows bony ankylosis of the entire length of the spinal column, of both sacro-iliac articulations, and of all the ribs at their junctions with the spine. The bodies are united by their edges, the inter-vertebral discs being unaffected. The bond of union thus consists of a series of bridges which are most marked on either side of the anterior common ligament. The ankylosis of the neural arches is effected by osseous metaplasia (more or less complete) of the ligamenta subflava, the inter-spinous ligaments, and the capsules of the joints between the articular processes of the vertebræ. The ribs are joined to the spine on both sides by ossification of their costo-vertebral and costo-transverse ligaments, and the positions of these various bands are accurately mapped out by the deposit of bone which has replaced the ligament. No diminution is observable in the size of the inter-vertebral foramina. There is one large dorsal curve in the spine which involves the

whole of the thoracic and the greater parts of the cervical and lumbar regions. In addition a moderate lateral deviation of the spine to the right exists. The hip-joints are normal, and the symphysis pubis is not ankylosed. The inlet of the true pelvis has a strikingly triangular outline.

The specimen has probably been taken from an old male skeleton.

No. 2109 (R. C. S. Museum).—Complete ankylosis of spine, pelvis, and ribs.

The condition of this specimen is so exactly like that of the preceding (No. 2050) that one description will almost suffice. The osseous material which has replaced the various ligaments presents a fibrous appearance in many parts, indicating the original structure of the ligaments. This is especially well seen in the site of the posterior costo-transverse ligaments. The hip-joints are normal, and the symphysis pubis, with the sacro-iliac joints, are ankylosed. As in the preceding specimen, the inlet of the pelvis is decidedly triangular; that part of the brim which stretches from just outside the sacro-iliac joint to the junction of the body and horizontal ramus of the pubes is flattened so that it forms a straight line on each side. In consequence of some bending of the ilium near the mid point of the crest the anterior superior spines are a little approximated. The attachments of the longissimus dorsi, gluteus maximus, and perinæal muscles are marked by numerous spiculated outgrowths indicating ossification of tendons. The preparation apparently belongs to an old male skeleton.

No. 1007(35) (Guy's Hospital Museum).—Complete ankylosis of the spine, pelvis, ribs, and hip-joints.

This remarkable specimen shows bony ankylosis of the entire length of the spine, of the pelvic and hip-joints, and of all the ribs with the spine. There was thus absolute rigidity of the skeleton from the head to the knee-joints, excluding the upper extremities.

Unfortunately, the specimen has been broken into several pieces and otherwise damaged, but its general characters very closely correspond with those of the two preceding spinal columns. The intervertebral discs are unaffected, the bodies are united at their edges by rounded bridges of bone, the joints between the articular processes are obliterated, and the neural arches and spines are more or less united by ossification of the ligamenta subflava and interspinous ligaments. The costo-vertebral joints are ankylosed, but

neither the anterior nor posterior common ligament seems to have shared in the osseous change. Viewed as a whole the spine shows an increase of the normal antero-posterior thoracic curve, the apex corresponding with the last two thoracic vertebræ; but there is no lateral deviation. The atlas is united to the cranium by its lateral masses, though the anterior and posterior arches are normal. The articular portion of the glenoid fossa is deepened and irregular from peripheral outgrowths, but the temporo-maxillary joint was clearly not ankylosed. The axis, and with it the remaining cervical vertebræ, was firmly united to the under surface of the atlas, but there is now very slight rotatory movement between them. This is probably the result of damage to the bones in preparation. The transverse ligament behind the odontoid process appears to be ossified, but the process itself is free.

The right hip-joint is completely ankylosed in a position of extreme abduction with some flexion and eversion. The shaft, trochanters, and neck of femur are normal, and as far as it can be seen the rounded outline of the head is preserved. But the margin of the acetabulum is welded with the margin of the articular surface of the caput femoris by a layer of spongy bone. The cotyloid notch is partly filled with similar material. Enough of the right ala of the sacrum has been preserved to show that the right sacro-iliac joint is also ankylosed. The bones are well formed, the ridges and impressions are very distinct, and though old they are heavy (especially the femur), without signs of atrophy. There is nothing in this portion of the preparation to suggest the nature of the disease which has caused the ankylosis.

The condition of the left hip-joint is precisely like that of the right from the exterior. Owing to a large piece of the acetabulum being broken off, the articular surface of the caput femoris is exposed. Its rounded outline is preserved, but the surface is covered with fine bony prominences and spiculæ. Near the site of the fovea capitis there is some loss of substance, but probably not from disease. The cavity of the joint is *not* obliterated, the ankylosis being produced by bony union of the margins of the acetabulum and caput femoris, as in the opposite joint.

No. 1318[60] (Guy's Hospital Museum).—Ankylosis of spine and hip.

This specimen was described by Dr. Hilton Fagge in 'Trans. Path. Soc.,' vol. xxviii, p. 201. It is especially interesting because

accompanied with a full clinical history and autopsy. In the three preceding instances no records of the cases have been preserved.

Dr. Fagge's case may be summarised thus:

The patient was a man, aged 34, whose illness began one year before admission to Guy's Hospital with marked stooping, great weakness, pain in the abdomen, and troublesome cough. Subsequently he became unable to walk without assistance; the respiration was entirely abdominal and orthopnœic, and death resulted from dyspnœa. The autopsy revealed bony ankylosis of the neural arches of the spines of the thoracic and lumbar vertebræ, and ankylosis of the following joints:—Right hip-joint, costo-vertebral and costo-transverse joints, and those between the articular processes of the vertebræ. The bodies of the vertebræ were remarkably softened, but the inter-vertebral discs were normal. The pleuræ were adherent, and there was bronchitis with bronchiectasis on both sides. Old calcareous deposits were found in the mesenteric glands, and a peculiar mortar-like substance in the cancellous tissue of the caput femoris and the heads of the ribs.

VII. DISEASES, ETC., OF THE DUCTLESS GLANDS.

1. *Cystic accessory thyroid body.*

By WALTER EDMUNDS.

[With Plate IX.]

THE tumour is of a globular shape, between 4 and 5 cm. in diameter. On section it is seen to consist mainly of one large cyst which contained a pale brown glairy fluid. Into the cavity of the cyst there projected two small excrescences. One of these is seen in the specimen, the other has been removed for microscopic examination. In the wall of the cyst is a solid portion about the size of an almond, probably constituting the original structure from which the cyst is a development.

Microscopic examination of this solid portion shows it to be of thyroid nature; it consists mainly of vesicles, some of which contain colloid matter. It differs from normal thyroid tissue in two respects:

(1) In the majority of the vesicles containing no colloid, but being wholly occupied by large cells, the result of the multiplication of the secreting cells lining the thyroid vesicles; and

(2) In the existence between the vesicles of a considerable amount of lymphoid tissue,—that is to say, of a tissue composed of small, darkly staining cells embedded in a vascular stroma. In this respect the structure differs not only from normal thyroid, but also, as far as my experience goes, from diseased thyroid. It suggests the possibility of the tumour having originated in a lymphatic gland. (See Plate IX, figs. E and F.)

Microscopic examination of the intra-cystic growth shows it to consist centrally of a coarse fibrous tissue, externally to that of a layer of lymphoid tissue, and on the surface, and therefore contributing to the lining membrane of the cyst, of a layer consisting of large secreting thyroid cells embedded in a network of fine fibres and blood-vessels. This tissue contains no proper vesicles, but here and there are seen in it small collections of colloid secretion.

The tumour was removed during life from the neck of a man, aged 28, where it had been noticed a few months. It was situated below and in front of the left angle of the jaw; it shelled out easily, and was not connected with the thyroid gland; indeed, it was some distance from it. The thyroid gland was not seen; as far as could be judged, it was normal. In childhood there had been some inflammation of the lymphatic glands in the same situation, probably of a tubercular nature, but this is now quiescent.

The only similar specimen to be found in the 'Transactions' of the Society is one of "Intra-cystic Papilloma of an Accessory Thyroid Gland," described by Mr. Bilton Pollard in vol. xxxvii (1886), p. 507. *November 19th*, 1895.

---

2. *Accessory thyroid body.*

By Cyril Ogle, M.B.

The lobes of the thyroid gland were somewhat enlarged, especially that on the left side, which extended downwards beside the trachea and partly covered it in front.

Quite separate, lying behind the sternum, just above the left innominate vein, and in the mid-line, was a tumour of hemispherical shape, measuring $1\frac{1}{2}$ inches in diameter and $\frac{3}{4}$ inch in thickness. There was no flattening of the trachea against which it lay.

On microscopical examination no evidence of lymphatic gland tissue was found in the tumour, the structure of which appeared to be that of thyroid tissue—vesicles of somewhat large size lined by a single layer of cubical epithelium and filled with colloid material.

There were, however, in addition large tracts of tissue devoid of colloid and composed of closely set follicles filled with epithelium, a condition seen in the embryonic state of the thyroid gland.

From a woman, aged 55 years, who died of granular kidney and cerebral hæmorrhage. There was no history of any symptoms connected with the tumour described. *January 7th*, 1896.

3. *Sequel of a case of cystic accessory thyroid body in which four operations for recurrence were performed in the course of six years.*

By Arthur E. Barker.

I am led to publish a brief record of the sequel of this case from the feeling that data, both in regard to the clinical and pathological histories, of so-called accessory thyroid tumours are urgently needed.

The clinical history of the primary growth in this case, prior to the first operation for its removal, has been already recorded ('Brit. Med. Journ.,' June 21st, 1890). The nature and immediate result of that formidable procedure were also described at the same time. It will not therefore be necessary now to do more than give a very brief sketch of the history of the original tumour before its removal, together with a note as to its structure when examined with the naked eye and the microscope. An account of its recurrences and the structure of the parts removed in three of the four subsequent operations, will then complete the case up to the present moment.

When I first saw the patient in 1889 he was aged 50, and except for this very large tumour on the left side of the neck, apparently in perfect health. The growth had commenced as a small moveable nodule in 1880, just above the clavicle, in front of the inner side of the sterno-mastoid muscle. In December, 1881, when he was first seen by Dr. Cole, of Bath, it had a diameter of about ¾ of an inch. In March, 1883, it had increased to 1½ inches across, and was cystic. In May, 1884, it was 3¾ inches in its longest diameter, which ran downwards and inwards. During the next four years it slowly increased in size. Up to February, 1889, the girth of the neck had increased 5 inches.

When I was about to operate on the mass in October, 1889, it was found to reach from over the mastoid process to the clavicle. In front it overlapped the jaw and pushed the larynx to the right. Behind, it reached well under the trapezius muscle. The skin over this mass was very thin, tense, and congested, and hardly moveable on the subjacent cysts. The latter were evidently numerous, from the size of an orange to that of a marble. The largest

was on the front of the tumour, and looked as though it would burst through the tense skin. The whole mass lay under the sterno-mastoid muscle, to which it was firmly fixed. No enlarged glands could be felt around it or in the axilla or groin.

On October 29th, 1889, I removed the whole mass and part of the sterno-mastoid muscle which was incorporated with it, by a most formidable operation. Some healthy glands were also removed from over the sheath of the great vessels, and another mass the size of a walnut, obviously infected with the same growth from the apex of the pleura, where the tumour dipped down behind the clavicle. The large wound healed absolutely without any trouble or suppuration, and the patient was out of bed in the third week, and left town for Brighton in the fourth.

The tumour on removal was found to consist of numerous cysts and a considerable amount of solid matter. The walls of the former were made up of a tough, well-defined envelope of fibrous tissue from $\frac{1}{16}$ to $\frac{1}{8}$ of an inch in thickness. This tissue was fairly well marked off from the stroma of the mass in some places, but shaded into it at others. All the cavities were filled with a dirty brown fluid, and contained numerous papillomatous masses projecting into them. These prominences were firm at the base, but branched out into the most delicate fronds, which floated in the fluid contents. They were exceedingly fragile. The stroma of the mass was pinkish white in tint and fairly firm, with soft friable patches here and there. Under the microscope the basis of the mass was seen to consist of tough fibrous tissue, highly differentiated, and containing few or no cells or nuclei. It simply showed strands of parallel wavy fibres packed closely together, so closely indeed as almost to give a hyaline appearance in certain parts. It was of this material that the walls of the cysts were composed. This substratum was broken up here and there by islands of cells of more or less cuboid shape, and the centres of these islands were undergoing colloid change. Many of the islands, however, were made up of large cells packed together without any arrangement and of no particular shape. Large vessels, cut at various angles, were also to be seen in the fibrous stroma. In other parts were oval or much elongated interspaces lined with columnar cells of great regularity and having clear material in their centres. The structure, in fact, recalled very strongly that of the thyroid gland, except for the irregularity in size and shape of the cell-lined spaces. These latter were appa-

rently the beginnings of cysts. But where such cysts were fully developed they presented a very interesting appearance. Their walls were lined everywhere with a single layer of cuboid epithelium of the most regular form. From these walls here and there papillomatous growths sprung out into the cavity of the cyst. These varied in size from small microscopic excrescences to masses as large as a walnut. But whatever their size, their structure was everywhere essentially the same. They consisted of soft, delicate connective tissue in the centre, covered by a cuticle of columnar cells. The shapes assumed by these papillomata were of the greatest variety. Sometimes they were simple villous projections of greater or less length. Sometimes this primary form was folded over and over on itself, so that its outline on section resembled the old Greek border pattern. Other processes were tree-like, branching in all directions. Many of the latter showed in their central stems spaces lined by the same epithelium seen on the surface.

The masses supposed to be infected glands removed at the first operation showed identically the same structure, but without any apparent tendency to the formation of cysts.

But it is in the further history of this case down to the present moment that its chief pathological interest lies. In the first place the patient is in excellent health at this very moment, over six years after the removal of the primary growth with its secondary masses. And yet it has been thought necessary since then to operate four times for recurrences. The last of these operations I performed in October, 1895. In each case the recurrence had all the appearance of being limited to the glands of the neck, turning out clearly in a chain of masses varying from the size of a pea to that of a small plum. Each reproduced exactly the structure of the original growth removed at the first operation on the three occasions on which I myself excised it—June, 1891, April, 1894, and October, 1895. This I proved by the microscopical examination of many sections which I still possess. On the other occasion, the second, the recurrence was excised by a surgeon in Bath, but the tumour was lost before it had been examined microscopically.

That this tumour was derived from an accessory thyroid gland I have myself no doubt. It might possibly have started from the border of the thyroid itself and gravitated downwards. But, after all, this distinction is hardly of importance, the structure in either

case being essentially the same and the functions of an accessory thyroid, as we now know, being probably the same as those of the true gland.

But the exact starting-point of the secondary nodules, since removed, is not so clear. If they originated, as I believed, on each occasion in the lymphatic glands, the tumour showed most of the characteristics of malignancy. It grew at the last rather rapidly, involved the sterno-mastoid muscle, a great part of which had to be removed; and supposing these secondary nodules to be formed in lymphatic glands, the repeated recurrence would indicate malignancy, though perhaps of a milder type than usual.

And yet in view of the fact that this patient is alive and in robust health at the end of six years in spite of repeated recurrences, I cannot help thinking that it is possible that the recurrent nodules may be explained otherwise than by supposing them to have formed in lymphatic glands and to be of a malignant nature. It has occurred to me that these recurrent nodules may be nothing more than outlying buds or germs of the original growth which escaped excision at the earlier operations, and since then have hypertrophied to make up for the removal of the original large mass of thyroid tissue. In regard to the latter it is impossible to say whether it included the whole thyroid or not. It reached from the mastoid process to below the clavicle, and transgressed the middle line of the neck in front, obliterating nearly all the ordinary landmarks. It may easily be, then, that the whole thyroid was actually removed at the first operation as one diseased mass, and that the isolated large nodules found deeper in the neck were developments of fresh thyroid tissue to replace that already destroyed by the disease.

But if the original growth started in an accessory thyroid, as the history would seem to indicate, and if the thyroid proper was healthy at the time, it would be a little difficult to account for the necessity for the formation of extra thyroid tissue.

This appears to me to be a question the elucidation of which is of the utmost practical importance. For, if after the removal of these so-called accessory thyroids, we see nodules springing up in the neck in and around the scar, indistinguishable to the naked eye and the touch from infected lymphatic glands, we ought to know whether we are to regard these as indications of the generalisation of a malignant growth to be removed as soon as possible, or as simple compensatory hypertrophy of nodules similar to the original

growth, which should be most studiously let alone. I confess that, until I had removed the last of the recurrences in this case in October, 1895, I always regarded them as glands infected from the original growth. But since then, and especially since I have made a careful microscopical examination of the nodules removed, I am inclined to think they were simply due to compensatory hypertrophy of outlying nodules, and that the condition of the thyroid gland, if it remains, requires this hypertrophy. And should there be any further reappearance of similar masses in this gentleman's neck in the future, I shall feel much more happy about them, and shall feel inclined to let them alone. I may be wrong, of course, in this surmise, and others may correctly regard these recurrences as glandular infections. And the fact that they were found in all parts of the inferior triangles of the neck would seem to support this view. But though their situation, behaviour, and minute structure resembled infections of glands, the long duration of the case and apparent immunity from infection of deeper organs six years after the removal of the primary growth arouses a doubt upon the point. If they be not glandular recurrences they are to my mind the more remarkable in their wide distribution and in their number and in their occurring in chains like glands. If they be glandular they are remarkable in the slight amount of malignancy in spite of their persistent recurrence time after time during six years.

The responsibility of coming to a decision as to their pathological nature is very great in this case. If they are glandular recurrences, they must be followed up and extirpated as often as they reappear. If they are compensatory enlargements of thyroid tissue, they must be left alone. On this point I hope for the assistance of members of this Society. *January 7th*, 1896.

Report of the Morbid Growths Committee on Mr. Arthur E. Barker's specimen of cystic accessory thyroid body.—We have carefully studied the microscopic sections submitted to the Committee by the author, as well as others prepared by ourselves.

We find, with the author, that the primary growth removed in 1889 and all the recurrent tumours preserved, are characterised by being in a highly pronounced degree papilliferous. The condition of the sections from the original tumour does not permit of a more detailed statement, but newly made sections taken from the last

recurrence but one (1894), which is unquestionably in lymphatic glands, exhibit the following appearances.

The papillary formations project into and completely fill the cysts within which they have grown, the cysts themselves being of various sizes, the smallest, as will be presently noticed, microscopic. That this is the correct view (as opposed to that of the growths being simple adenomata) appears from the fact that considerable areas of the interior of the cysts are plainly recognisable, and though contiguous with, are quite distinct from, the contained papillary mass.

The epithelium covering the highly complex branching papillary processes is in some places columnar, in others subcolumnar.

It is noteworthy that colloid material of the usual kind lies between and amongst the outgrowing processes, the cells covering which have retained their physiological properties as in a glandular tissue produced by retrocession or inversion from a free surface.

The amount of colloid present, however, is not great.

The method of development is distinctly traceable in the sections prepared by ourselves.

At the periphery of the main cysts in the tissue representing the capsule of the tumour are to be seen minute solid collections of epithelial cells without lumen; in such groups a lumen is next formed, and into the minute cysts resulting from the increase of this lumen the earliest stages of papillary formation can be seen. The type of growth is from the first papilliferous; and we should class it as a cystic papilliferous carcinoma. In places the microscopic picture is almost indistinguishable from the papilliferous cystic adenomata of the ovary.

The question proposed by the author of the communication is, whether the recurrent tumours have formed in lymphatic glands or are independent formations of thyroidal tissue akin to accessory thyroids.

Amongst the sections furnished by the first operation (1889) is one of a lymphatic gland. This, we agree with the author, is devoid of any new growth. The author, however, states that he has observed nothing like lymphatic tissue in any of the recurrent tumours, and is thus inclined to disbelieve their glandular origin. This observation is correct so far as the author's own sections go, but in those prepared by ourselves from the last recurrence but one (1894), there is unmistakable evidence that certain of the growths have taken place in lymphatic glands. Around the new

formation there is a comparatively thick layer of typical lymphatic tissue accurately bounded externally by a thin fibrous capsule.

We may point out, in addition, that the papilliferous character of all the recurrent formations removes them from the category of accessory thyroid tissue which has undergone compensatory hypertrophy. The lymphatic infection is comparable to that of the axillary glands in papilliferous or villous carcinoma of the mammary ducts, and the disease in question resembles this in its comparatively low degree of malignancy. We can express no opinion as to the origin of the primary growth, whether from a normal or accessory thyroid, but the proper recurrences, we think, probably all arose in lymphatic glands, as this was certainly the case in the last but one of them. There is, at least, no evidence to show that any of the recurrences arose in accessory thyroid glands.

Somewhat similar cases have been described and figured by Wölfler ("Ueber die Entwickelung und den Bau des Kropfes," Langenbeck's 'Arch. f. klin. Chir.,' vol. xxxix, 1883).

JAMES BERRY.
ANTHONY A. BOWLBY.
SAMUEL G. SHATTOCK, *Chairman.*

---

4. *Multiple exogenous adenomata of the thyroid body.*

By SAMUEL G. SHATTOCK.

THE rarity of the anatomical condition to be described, and the contrast it offers to the case of recurrent thyroidal tumours reported by Mr. Barker in the present volume (p. 225), may render it worthy of notice.

The growths were removed by Mr. W. H. Battle (who has kindly placed the material at my disposal), from a man 22 years of age, a carman, admitted into St. Thomas's Hospital in October, 1895. There was no parental disease of a like kind, but one brother of the patient, aged 25, had a median swelling of the neck in the

position of the thyroid, unassociated with any mental defect; a second brother and a sister were free of disease.

The patient had noticed a swelling in the right side of the neck for three years; this had slowly increased save for a temporary diminution under the use of iodine paint about two years ago.

State on admission.—There is a tumour about the size of an orange in the right side of the neck beneath the sterno-mastoid. For the most part it is soft and elastic, but towards the lower and inner part there is a nodule which is exceedingly hard and freely moveable, though connected with the main mass.

The isthmus is distinctly increased in size. The left lobe of the thyroid is also enlarged, and with the exception of a nodule towards the inner and lower part, it is throughout of soft consistence.

Laryngological examination revealed no impairment in the movement of the vocal cords, or other change.

The growth of the right side was alone removed. Recovery was uninterrupted.

Description of the specimen.—The mass comprises three chief portions, ranging from $1\frac{1}{4}$ to $1\frac{1}{2}$ inches in chief diameter, and in addition a large number, about twenty, of lesser; these have a range of diameter from $\frac{3}{4}$ to $\frac{1}{8}$ of an inch. The tumours are variously shapen or facetted from mutual pressure. The chief formations and certain of the lesser have, moreover, a lobulated surface. These lobular eminences, as shown by section, are divided from the parent mass by a delicate line of connective tissue, the whole being contained within a common though extremely thin capsule. The outer surface of the chief mass presents the meandering vascular furrows which are present on the normal thyroid, and many thin-walled patulous veins are displayed in the cut surfaces whence they emerge to the exterior.

One of the growths, about an inch in chief diameter, has undergone nearly complete calcification. Before dissection these different growths were loosely held together by connective tissue, they formed indeed not a single mass surrounded by a common capsule, but a conglomerate of distinct tumours not unlike a group of lymphomatous glands.

Histology.—The larger tumours exhibit in some parts the structure of ordinary thyroid tissue, in others modifications of it; in the former the tissue consists of colloid-holding tubular spaces lined with a single layer of cubical epithelium. Here and there hæmor-

rhage has widely disparted and compressed the tubuli. The vesicles when compared with those of the normal gland are not unnaturally large, as they are in ordinary parenchymatous goitres.

Other portions of the larger tumours present the structure exhibited more widely by the smaller. In these the gland spaces are of greater size than normal, and are filled with multiform epithelial cells; they have no proper lumen, and the colloid is in relatively small amount, often as collections of discrete droplets lying amid the cell masses, and clearly the product of individual cells.

Remarks.—The microscope shows that the growths forming this remarkable conglomerate are throughout of thyroidal tissue, *i. e.* that they are simple adenomata, and have not arisen in lymphatic glands. Such a condition might account for a series of recurrences ensuing after a corresponding series of incomplete removals, but the realisation of such a possibility, though suggested, is not to be found in Mr. Barker's case before referred to; in that instance the recurrences, as determined by the Morbid Growths Committee, were located in lymphatic glands, and the tumours themselves were cystic papilliferous carcinomata.

Such multiple adenomata might arise, it is conceivable, independently of the proper thyroid in connection with residua of the primitive diverticula from which the lateral lobes and isthmus are developed, *i. e.* the formations might be genetically distinct. The thyroid, though ultimately ductless, is formed around a group of ducts (for its diverticula are such) after the manner of an ordinary acinous or tubular gland like the pancreas or kidney, and it bears the marks of this mode of development in the persistent lobulation it presents on section, whilst the so-called vesicles, as long ago pointed out by Virchow, are continuous tubular structures; the thyroid is, in short, a ductless tubular gland. As the kidney in some vertebrates (Bear, Seal, Manatee, Cetacea, Lacertilia, Ophidia), is compound, so conceivably might be the thyroid, seeing that it is developed after a similar plan. I have, however, been unable to find any description of such a condition, and nothing indicating it is shown by the series "thyroid" in the Museum of the Royal College of Surgeons, though the series is at present a small one. The possibility, therefore, of an atavistic reversion to an ancestral type cannot be at present considered.

The multiplicity of tumours in the case under consideration is, I believe, due to what may be called exogenous formation. The

growth of circumscribed isolated masses of thyroidal tissue in the thyroid body is of not infrequent occurrence in goitre—adenomatous goitre; such masses lie within the hypertrophied gland or invested on their more superficial aspect by a layer of thyroidal tissue; and they may be described as endogenous. The isolable growths, however, may arise at the surface, and, like subperitoneal myomata of the uterus, eventually become discontinuous. This is what has happened in the present case, and in the masses so disconnected the same process has been repeated. Thus some of the larger are merely lowly lobulated, but a section carried through them shows that the eminences appertain to hemispherical processes which are parted off from the rest of the neoplasm by a delicate line of connective tissue; in other situations there are minute bud-like projections which readily allow of being peeled away from the parent tumour.

In uterine myomata this method of multiplication is well known, but I have never seen it repeated; I do not know of a discontinuous subperitoneal uterine tumour which presents secondary eminences undergoing the same process of isolation.

March 17*th*, 1896.

---

5. *On the transformation of solid thyroid adenomata into cysts.*

By James Berry, B.S.

The fifteen specimens that I show this evening are intended to illustrate the manner in which a common form of thyroid cyst is formed, namely from solid encapsuled adenomata, by the gradual breaking down and liquefaction of the centre of the adenoma. The specimens are nearly all from the museums of St. Bartholomew's and the Royal Free Hospitals, and most of them have been removed by operation. The first specimen is a globular adenoma of the size of a small orange, removed feom a girl aged 10. It is solid throughout except in the very centre, where a small cyst is beginning to form. The next, of about the same size, shows a more advanced stage; the cavity in the centre is considerably larger. The third is from an older patient, a woman aged 41; in this case the whole of the tumour has liquefied, except at the periphery, where small masses

of thyroid tissue still adhere to the inner surface of the cyst wall. Another specimen shows a similar condition. It is, I think, sufficiently evident that these are all merely different stages of the same process. The next specimen is one which immediately after removal appeared to be a perfectly fluid cyst, but by carefully hardening the specimen in spirit for some days before opening it, the fluid portion has been solidified, and the delicate thyroid tissue, the remains of the original solid adenoma, has been rendered evident, and is seen to form about one third of the whole tumour. The next three specimens show numerous adenomata occupying the whole lateral lobe of an enlarged thyroid. Some of the adenomata are quite solid, others show liquefaction of the centre only, while in others the whole of the interior has been converted into fluid. The remaining specimens with the exception of two, show also different stages of the transition of adenomata into cysts. Thyroid cysts which have originated in this manner are particularly well suited for intra-glandular enucleation, since the capsule is almost always very well marked, and, in the older tumours at least, the cyst wall is usually thick and only loosely embedded in the surrounding gland tissue. The last two specimens have been brought here for comparison with the others; they are thin-walled smooth cysts with clear straw coloured contents, and do not belong to the same class, as they have apparently not been formed by the breaking down of adenomatous tissue.

March 17*th*, 1896.

---

6. *Further observations and experiments on the pathology of Graves's disease.*

By WALTER EDMUNDS.

(From the Brown Institution.)

[With Plates VIII and IX.]

IN a communication to the Society last year, the great importance of the parathyroid glands was pointed out.

It was shown that if from a dog the whole of one lobe of the

thyroid gland, including the parathyroid, was removed, and also two thirds of the opposite lobe, the dog would live or die according as the portion left did or did not contain the parathyroid gland of that side.

Further experiments have shown that it is not even necessary to leave any thyroid tissue proper at all, one parathyroid is of itself sufficient. In six dogs now have I left only one parathyroid, and the animals have lived. In some of these experiments, in order to be sure of not interfering with the blood-supply of the parathyroid to be left, the dissection has been carried rather wide of it and thus a minute morsel of thyroid tissue proper has also been left; but we shall see reason for thinking that this fragment had nothing to do with preserving the life of the animal.

If both parathyroids are removed, it is necessary, in order that the dog may live, to leave a considerable portion of thyroid proper. In one of these experiments one quarter of one lobe and one fifth of the other lobe were left; the animal nevertheless had severe symptoms of athyroidea, and, as it was thought certain he would die, he was destroyed.

In another experiment three-quarters of the thyroid proper in one lobe only was left (and neither parathyroid); the dog lived, took his food well, and did not lose flesh, but he had symptoms. He had well-marked tremors, and could not stand up properly; he remained in this state, getting neither better nor worse, for forty-four days, when he was killed.

Thus it is necessary, in order that a dog may live without parathyroids, that about 37 per cent. of the thyroid proper be left, and if he is to remain in good health, somewhat more; it seems also clear that any fragment of thyroid proper left together with the parathyroid in the other experiments had nothing to do with the preservation of the life of the animal.

The parathyroids and also the portions of thyroid tissue proper left in these experiments hypertrophy, but the thyroid proper by far the most. The microscopic changes found are interesting and important.

In the parathyroid the changes seem to be mainly those of hypertrophy. There are to be seen secreting cells, sometimes greatly enlarged, and cells showing cell inclusions, also giant cells and an infiltration of leucocytes. (Plate VIII, figs. A and G.)

Sometimes there is found a long line of columnar secreting

cells forming almost, or quite, a vesicle; but the vesicle is solitary and surrounded by less differentiated secreting tissue. Sometimes, too, scattered throughout the specimen may be seen minute collections of normal colloid secretion.

These changes no doubt show the intimate connection histologically between the parathyroid and thyroid proper; but they fall far short of the one developing into the other; and as some of the experiments extended over six months from the time of operation, it may be inferred that in the dog, as in the rabbit, the parathyroid under these conditions does not develop into thyroid tissue proper.

In the piece of thyroid proper left, the following changes are found.

If the portion left is small, and no parathyroid is also left, the dog will only survive a few days. The changes are: (1) the colloid has disappeared from the vesicles; (2) the vesicles are filled with blood; or (3) they are occupied with large cells which seem to be due to the multiplication of the secreting cells lining the vesicles.

If a parathyroid or sufficient thyroid has been left to allow the dog to live, then the specimens can be obtained at any date and the following changes will be found.

(1) The vesicles become enlarged and their shape altered from round or cubical to oblong or branched. (2) The lining membrane of the vesicles becomes convoluted, and projects in ridges into the cavities of the vesicles. (3) The secreting cells become columnar, and taller than before. (4) Comparatively little colloid is to be found in the thyroid vesicles, its place being often taken by a secretion which stains much less deeply. (Plate VIII, figs. B and D; Plate IX, figs. A and C.)

The explanation of these changes seems to lie in an attempt at compensation. The enlargement of the vesicles and also the convolution of the lining membrane would allow of more secreting cells lining the vesicles in a single layer; indeed, the multiplication of the secreting cells, in response to an increased demand, may possibly cause the stretching out of the basement membrane, which would lead to its convolution and also to the enlargement of the vesicles and their branching.

One point of great interest in connection with this matter, is that these changes are almost identical with those seen in the enlarged thyroid of Graves's disease; here too the vesicles are enlarged, oblong, and branched; the lining membrane is convoluted, and the secreting cells columnar, also the colloid is to a greater or less

extent absent, and replaced by a secretion which stains much less deeply, and appears to be of a more watery consistence; sometimes also free secreting cells are to be seen in the vesicle, sometimes blood. (Plate VIII, figs. C and E; Plate IX, figs. B and D.)

These resemblances are so close that they suggest that the changes in the thyroid of Graves's disease are due to an attempt at compensation; if so, it would appear from the extent of the changes on the one hand, and the persistence of the disease on the other, that the attempt is unsuccessful; the enlarged thyroid no doubt forms an increased amount of the secretion, but this does not cure the disease, and this agrees with the clinical observations of the uselessness of thyroid feeding in the treatment of Graves's disease; the increased secretion may, and very possibly does, add to the symptoms, but that is a very different thing from being the cause of the disease.

With respect to exophthalmos, in the former paper it was stated that it was intended to repeat the experiments of excising the parathyroids of rabbits, and endeavouring to ascertain by comparison with previously selected controls, whether the operation caused any alteration in the prominence of the eyes. The experiment has now been tried again,—ten times,—with the result that five times the eyes of the operated rabbits appeared to have become less prominent, —that is to say, excision of the parathyroids caused exophthalmos, in one case the opposite result ensued, and in four cases the results were negative, or at least indecisive. It must be admitted, however, that the method of investigation does not seem very rigid.

In connection with this subject it may be mentioned that in two dogs in both of which on one side the whole lobe of the thyroid was excised, and in addition in one dog the parathyroid, and in the other the thyroid proper on the opposite side were excised—in both these dogs there occurred on the side of total extirpation a very distinct widening of the palpebral fissure, due to a drawing up of the upper lid. This result does not always occur in these operations.

The experiments here related were made at the Brown Institution, and the writer has much pleasure in expressing his thanks to Professors Sherrington and Rose Bradford, for the opportunities and assistance afforded to him.

Conclusions.

1. If from a dog the thyroid gland is so excised as to leave only one parathyroid, the dog will live.

DESCRIPTION OF PLATE VIII.

Illustrating Mr. Edmunds' paper on "Further Observations and Experiments on the Pathology of Graves's Disease." (Page 235.)

FIG. A.—Parathyroid of dog. (× 380.) The whole of one lobe of the thyroid with the corresponding parathyroid was excised, as well as the greater part of the opposite lobe of the thyroid. Thus one parathyroid and a small portion of the adjacent thyroid proper were left. The dog continued well, and at the end of forty-one days was killed.

FIGS. A and G represent sections from the parathyroid, which was removed after death. They show (1) infiltration of the parathyroid with small cells; (2) large cells with lightly staining nuclei; (3) giant-cells with many nuclei; (4) spindle-cells and streaks of connective tissue. Contrast with Fig. F, which shows normal parathyroid of dog.

FIG. B.—The whole of one lobe of the thyroid of a dog was removed, together with the corresponding parathyroid and five sixths of the opposite lobe of the thyroid, leaving one parathyroid and one sixth of the thyroid proper. The dog continued well. One hundred and thirty-two days later the remaining portion of the thyroid was excised. Two days later it was found that the dog was suffering from symptoms of athyroidea; he could not stand, and his limbs were rigid and tremulous; he had also rapid breathing. He was killed.

The part removed at the second operation was found to consist not only of the portion of thyroid proper that had been left, but also of the parathyroid. The figure shows a section of the hypertrophied remnant of thyroid proper (× 90). The vesicles are oblong, and the basement membrane convoluted. The secreting cells are shown more highly magnified in Fig. D.

FIG. C.—Section of the enlarged thyroid from a severe case of Graves's disease. The vesicles are oblong, and the lining membrane is convoluted. The secreting cells are columnar. (× 110.)

From a woman aged 35, who suffered from exophthalmos, enlarged thyroid, hypertrophied heart without valvular disease, and considerable ascites. Death was due to double pneumonia and cardiac failure.

FIG. D.—Cells lining the vesicles in the remnant of the thyroid described under Fig. B. The cells are much enlarged and columnar. (× 600.)

FIG. E.—Cells lining a vesicle of the enlarged thyroid of a woman aged 31, who died of Graves's disease. The cells are hypertrophied and columnar. (× 600.)

FIG. F.—Normal parathyroid of dog. (× 200.)

FIG. G.—Section of same parathyroid as that represented in Fig. A. There is enlargement and activity of the secreting cells. (× 220.)

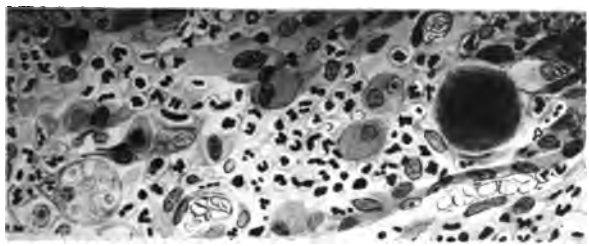

Fig. A.

Fig. B.

Fig. C.

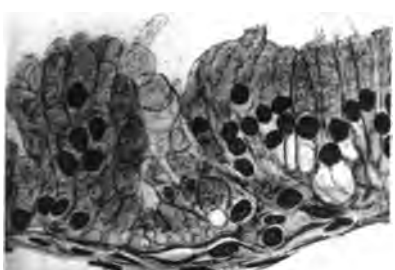

Fig. D.

Fig. E.

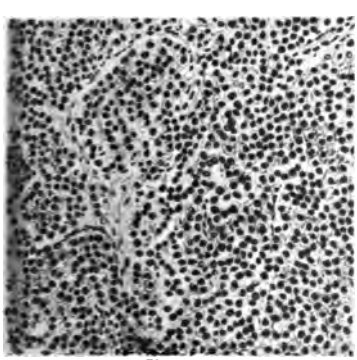

Fig. F.

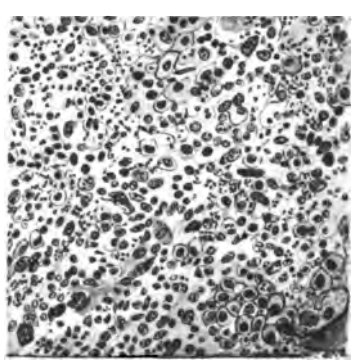

Fig. G.

DESCRIPTION OF PLATE IX.

Illustrating Mr. Edmunds' paper on "Further Observations and Experiments on the Pathology of Graves's Disease." (Page 235.)

The whole of one lobe of the thyroid of a dog, together with the greater part of the opposite lobe, was excised. In four days the animal died with symptoms of athyroidea.

FIG. A.—Section from the remaining portion of thyroid. The vesicles do not contain colloid, and the secreting cells have multiplied and migrated into the cavities of the vesicles, which also contain a little blood. (× 220.)

FIG. B.—There is multiplication of the secreting cells, which have migrated into the cavity of the vesicle, as in Fig. A. (× 220.) From the same case of Graves's disease as Plate VIII, fig. C.

FIG. C.—Large cells and blood are seen in the cavity of the vesicle. (× 220.) From the same specimen as Fig. A.

FIG. D.—Similar enlarged cells from the same specimen as Fig. B. For comparison with Fig. C. (× 220.)

FIG. E.—Section of a cystic accessory thyroid body (p. 223). It consists mainly of vesicles, some containing colloid (recognised by its dark staining), and some only large cells. Between the vesicles the stroma is infiltrated with many lymphoid cells. (× 65.)

FIG. F.—The portion of the preceding section enclosed in a square, more highly magnified. The cells within the vesicle are of considerable size, and possess large nuclei. They are probably descendants of the secreting cells. (× 380.)

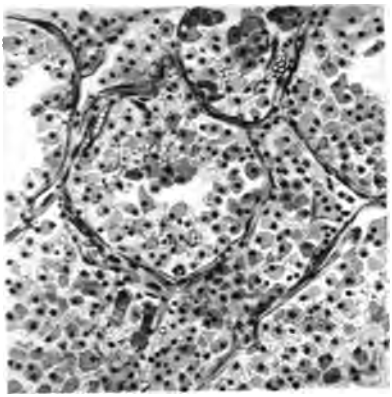

Fig. A.

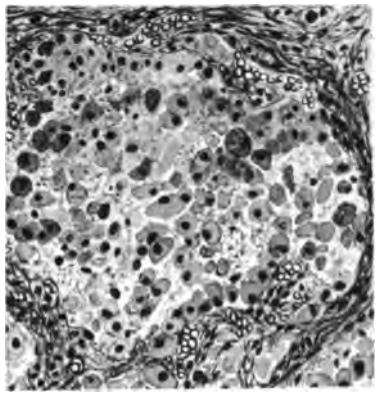

Fig. B.

Fig. C.

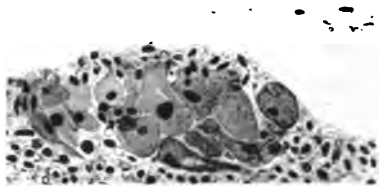

Fig. D.

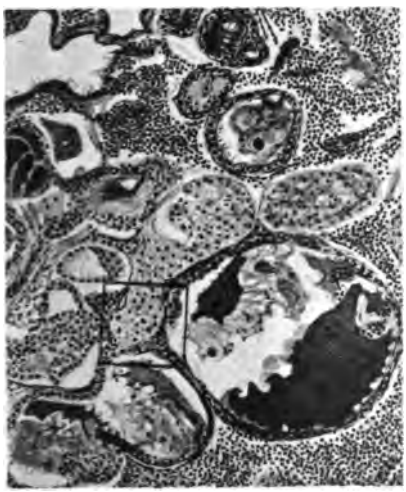

Fig. E.

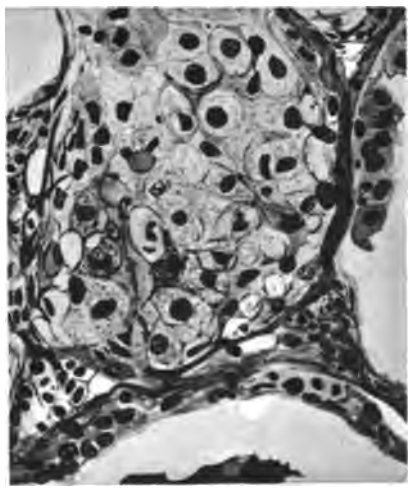

Fig. F.

2. If both parathyroids are removed, then it is necessary in order that the dog may live to leave about 40 per cent. of the thyroid proper; further, it is possible to leave just such an amount of thyroid proper as to give the dog a chronic myxœdema.

3. The microscopic appearances of compensating hypertrophy of thyroid tissue proper, are almost identical with the changes found in the enlarged thyroid of Graves's disease; these changes are therefore probably secondary, or in other words the disease of the thyroid is not the starting-point of Graves's disease.

REFERENCES.

Gley.—'Congrès des Médecins Aliénistes et Neurologistes,' Bordeaux, 1895.
Nicolas.—'Bibliographie Anatomique,' 1896, No. 4.

May 19*th*, 1896.

VIII. DISEASES, ETC., OF THE SKIN.

1. *Crateriform ulcer of face.* (*Card specimen.*)

By H. D. Rolleston, M.D.

In the 'Transactions' of the Society, vol. xl, p. 275, 1887, Mr. Jonathan Hutchinson gave an account of a group of cases of squamous-celled epithelioma of rapid growth occurring on the face near the eyes. Their characters were rapid growth, absence of any glandular infection, and as a rule of recurrence, and the histological structure of squamous-celled epithelioma.

By the term "crateriform ulcer of the face" this form of "acute epithelial cancer" (squamous-celled carcinoma) can now be conveniently distinguished from rodent ulcer (carcinoma of sebaceous glands, or possibly of some of the other appendages of the skin). Kaposi,[1] however, applied the epithet "crater-like" to the ulceration of carcinoma of the skin, including rodent ulcer. Radcliffe Crocker [2] speaks of crateriform ulcer as developing on the top of an ordinary rodent ulcer, and so presumably not having the structure of squamous-celled carcinoma from the first. But he describes a primary case of a small ulcerated tumour, clinically rodent ulcer, which after removal was found to be a typical squamous-celled carcinoma, and therefore more allied to crateriform ulcer. The question arises whether such cases of small comparatively slow-growing squamous-celled carcinoma on the upper part of the face are to be included in the class crateriform ulcer. In appearance and clinical features they are allied rather to rodent ulcer, while histologically they are potential crateriform ulcers which have not yet become acute. The existence of such transitional cases probably accounts for the Continental view that rodent ulcer is not a distinct form of carcinoma of the skin.

In the specimen I have the honour of showing, the histological

[1] Hebra, 'Diseases of the Skin,' vol. iv, p. 208, New Sydenham Soc., 1875.

[2] 'Diseases of the Skin,' 2nd edition, p. 632.

structure of the raised edges of the crater-like ulcer was that of a squamous-celled carcinoma with cell nests.

History.—M. R—, 55 years of age; nine years ago, while an attendant in an asylum, he had been scratched on the nose by a patient, and since that time his nose had been the seat of a chronic inflammatory condition associated with ulceration, which had destroyed the alæ and septum, and in places where there was cicatrisation, somewhat suggested lupus.

Two years ago a tumour appeared on the left temporal region. It soon ulcerated, and growing in extent was at the time of admission 3 × 3½ inches. The edges were raised and thickened, and the base covered by sloughing material.

He had not to his knowledge had syphilis, but since he had been a soldier for twenty-six years it was thought wisest, on the chance that the ulceration of the nose and forehead might both be syphilitic, to try the effect of iodide of potassium.

As the ulcer on the forehead spread under antisyphilitic treatment, and began to invade the upper eyelid, Mr. Warrington Haward, to whose kindness I am indebted for this specimen, freely removed the ulcerated growth, and at the same time some enlarged glands from the left parotid region. Unfortunately these glands were not preserved, so it is impossible to say whether they were enlarged from simple adenitis or whether they contained carcinomatous growth.

In Mr. Hutchinson's cases glandular enlargement did not occur—a remarkable fact considering the rapidity of the growth.

December 17th, 1895.

---

2. *Two simultaneous squamous-celled carcinomata.* (*Card specimen.*)

By H. D. Rolleston, M.D.

These two growths were removed from a man aged 64 by Mr. Dent, by whose kindness I am enabled to show them.

For the last forty years the patient had lived at Torquay, and for many years had had a bad lip, breaking out from time to time and healing in between. For the last three years it has been ulcerated continuously. Eleven months ago the growth on the left ear was noticed.

On admission, the left half of the lower lip and the lower half of the left pinna were occupied by squamous-celled carcinomatous growths, typical both to the naked eye and microscopically after their removal.

The specimens are of interest (1) from their presence at the same time on the same patient, and (2) from the possibility of infection having been conveyed from the older growth on the lip to the ear, thus setting up a similar growth in that situation.

Multiple rodent ulcers have been frequently recorded, and their association with a marked tendency to freckle is pointed out by Mr. J. Hutchinson, 'Archives of Surgery,' vol. iii, p. 318. In this case there was no noticeable freckling.

Professor William Rose ('King's College Hospital Reports,' vol. ii, p. 69, 1895) describes an analogous case of epithelioma of the right arytæno-epiglottidean fold of the larynx following a similar growth of the tongue in a man aged forty-seven years. He regards it as a true case of cancerous implantation. *March 17th*, 1896.

---

3. *An anomalous tumour (? adenoma) of sebaceous glands.*

By H. D. Rolleston, M.D.

(With Plate XII, fig. A.)

The growth was removed from a patient in St. George's Hospital by Mr. C. T. Dent, to whose kindness I am indebted for the opportunity of showing it.

Situated in the left temporal region, just above the outer angle of the orbit, the tumour was seen before removal to be composed of papillomatous masses separated from each other by faint depressions, and partially covered by a scab.

The patient, John M—, aged 57, an electro-plater, had had the growth for "many years,"—for how many he did not exactly know, but it was more than twenty, though not all his life. Five years ago it became irritated, and since that it had increased in size. Eighteen months before admission caustic had been applied, with the result that it had grown more rapidly.

The tumour is sessile, but is almost entirely above the level of the surrounding skin. On its deeper aspect it is limited by condensed fibrous tissue, and it but slightly depresses the derma on

which it lies. The epidermis covering it shows the effect of constant pressure applied from within. The interpapillary processes are flattened out and atrophied. Part of the tumour is ulcerated.

From irritation excited by the tumour, the interpapillary processes of the skin in the immediate neighbourhood of the tumour have grown down into the derma.

There are numerous sebaceous glands in close contact with the edge of the tumour; in one or two places proliferation of these glands is taking place, the resulting cells resembling those of hair follicles or those of the tumour.

The framework of the tumour is composed of strands of cell-formed fibrous tissue, which divides it into lobules. In parts there is some myxomatous tissue (Plate XII, fig. A) between the masses of epithelial cells, an appearance which has been described by Mr. Paul, both in sebaceous adenomata and in rodent ulcer.[1]

The epithelial cells composing the growth are arranged on a somewhat irregular acinous pattern. Some of the acini are very large, and contain indistinctly-seen epithelial *débris*; the cells lining them are flattened, as if from pressure exerted by the contents. In other parts there are masses of epithelial cells which are probably acini filled up with epithelial cells. The cells are of various shapes and differ in size; some resemble the cells of sebaceous glands, while others are more like the cells of rodent ulcer. Mutual pressure has produced moulding of the epithelial cells on each other, which gives the appearance of commencing *pseudo*-pearls. Kanthack[2] points out that they may be due to glandular disease or degeneration, and, as Paul remarks, their importance is often exaggerated. In this case, however, they are in a very rudimentary state, and do not present any degenerative changes.

The cells are sometimes sub-columnar, occasionally from pressure flattened into the form of spindles, but generally spheroidal. There is no sign of calcification such as has been described by Mr. Eve[3] and Mr. J. Hutchinson, jun.,[4] in sebaceous adenoma.

The resemblance of the cells and the presence of numerous sebaceous glands in the immediate neighbourhood point to this origin of the growth.

[1] F. T. Paul, 'Trans. Path. Soc.,' vol. xlv, p. 164.
[2] A. A. Kanthack, 'Journal of Anatomy,' vol. xxvi.
[3] F. S. Eve, 'Trans. Path. Soc.,' vol. xxxiii, p. 335.
[4] J. Hutchinson, jun., ibid., vol. xli, p. 275.

On the whole the structure is acinous, but proliferation has taken place to such an extent as to render the growth atypical, and so to suggest that there is here a transition from an adenoma to a carcinoma of the sebaceous glands.

The proliferation of the epithelial cells might have been, in part at least, the result of stimulation by caustic eighteen months before removal, and in this connection it is noteworthy that proliferation of the connective tissue does not appear to have played any part in obscuring the structure of the growth, as was the case in the squamous-celled carcinoma shown before the Society by Mr. Robinson in 1891.[1]

The point of interest in this specimen is its relation to adenoma on the one hand, and to carcinoma of the sebaceous glands on the other.

The long duration of the disease and its more recent growth after irritation suggest that it is an adenoma that has been quickened into morbid growth. Although the acini are larger than those met with in rodent ulcer, the general arrangement of the epithelial cells is compatible with the view that the growth is a rodent ulcer of an irregular type, for, as Mr. Paul remarks, it is an undoubted fact that in rodent ulcer both the cells and the cell groups vary considerably in appearance.

But that it is not a rodent ulcer seems to me to be shown by the position and relations of the growth. It does not invade or infiltrate the derma, and only to a very slight degree depresses the derma, from which it is separated by a layer of condensed fibrous tissue. Mr. Bowlby,[2] however, points out that "there is a noticeable absence in rodent ulcer of the infiltration of the surrounding tissues at the edge of the tumour by detached epithelial cells," and contrasts it in this respect with epithelioma. Though bearing this carefully in mind, it has seemed to me that in this case the anatomical position of the growth stamps it as an adenoma. The presence of ulceration has no special bearing on this question; it may be absent for years in rodent ulcer, in one case for twenty-two years (Bowlby), and is liable to occur in sebaceous adenomata.[3]

It may perhaps be urged that rodent ulcer is quite an exceptional form of carcinoma, and that inasmuch as many of the clinical

[1] H. B. Robinson, 'Trans. Path. Soc.,' vol. xlii, p. 315.
[2] A. A. Bowlby, ibid., vol. xlv, p. 152.
[3] J. B. Sutton, 'Tumours,' p. 236.

features of malignancy are conspicuously absent, its recognition should depend solely on its histological structure, quite apart from its anatomical relations. In that case this specimen would rank as a rodent ulcer, and not as a somewhat anomalous adenoma. It is rather with a view of eliciting an expression of opinion on the relative importance of histological structure and anatomical position in determining the nature of a growth that the specimen is brought forward. *December 3rd*, 1895.

NOTE.—In the discussion which followed most speakers regarded the growth rather as an early rodent ulcer than as an adenoma.

IX. MORBID GROWTHS.

1. *Saponifying necrosis in a lipoma of the thigh.* (*Card specimen.*)

By Samuel G. Shattock.

A vertical section of a large pedunculated lipoma which was removed from the thigh. It had been growing for twenty-six years, and after excision weighed 3½ pounds. In its centre there is an oval area of necrosis an inch and three quarters in chief diameter, which contrasts with the rest of the growth by its opacity and whiteness.

On the left of this, separated by a zone of normal tissue, is a second similar focus in which softening has taken place, with the production of a *pseudo*-cyst.

The cause of the necrosis, whether arterial blockage or other, cannot be certainly determined; in the microscopic sections there are vessels filled with clot, but how far this condition is causally related to the death of the tissue it is impossible to say. Extensive necrosis is not rarely met with in sarcomata, notably those of the testis and giant-celled tumours of bone; these areas are often largely mingled with blood, and it is a question yet to be answered whether this necrosis is due to the laceration and isolation of parts of the growth by extravasation from ruptured vessels, or whether it may be the result of arterial obstruction by ingrowth of the tumour tissue, the necrosis being then followed by extravasation, as in hæmorrhagic infarction.

In the case of ordinary tissues death is followed by intra-cellular coagulation, and this, it may be, by calcification, as in the necrosis of tubercular granulomata. We find precisely the same change ensue in the grafts of human mammary carcinoma placed in the subcutaneous tissue or peritoneal cavity of animals; the trans-

planted pieces die and undergo the changes of an anæmic infarct of the kidney, the carcinomatous epithelium ceasing to take any nuclear stains.

In lipomata, however, a different result follows necrosis, seeing that coagulation cannot be induced in the oil of the cells. In these circumstances the oil undergoes saponification, combinations taking place between the fatty acids and the lime and soda salts of the plasma which infiltrates the dying tissue.

Why this does not occur during life, whilst the tissue is surrounded by plasma, can only be attributed to the action of the living protoplasmic walls of the cells.

The process is not coagulation necrosis, nor is it calcification, but one peculiar to adipose tissue, or other tissue in which extreme fatty degeneration has preceded its death, and it should be definitely distinguished by the term Saponification.

The change is referred to by Virchow ('Die krankhefte Geschwülste'), who observes that it is not rare to find in lipomata, as Fürstenberg showed in animals, isolated cavities filled with fat, partly fluid, partly saponified. True calcification occurs, of course, in fatty tumours, but this is not to be confused with saponification.

Not only is the correctness of this interpretation borne out by chemical analysis, but one finds on histological section that although a few cells may hold the delicate radiating crystals of solidified fat, others are filled with a structureless coarsely fissured substance, to the clefts of which there adhere granules of a deeply coloured precipitate, or their inner surface is thickly crusted with a similar precipitate.

No such appearances are encountered in the normal tissue of lipomata, and the granular coloured precipitate may be regarded as derived from the hæmatoxylin, and due to the action of the soap within the cells, or the remains of it adhering to their walls,—such a precipitate, in fact, as is produced when an acid solution of the dye is added to tap-water or to a solution of common soap. In the necrosed focus, besides the fat cells, there may be recognised hyaline tracks of fibrous tissue, but no signs of hæmorrhage either recent or old.

I endeavoured experimentally to observe the saponification of necrosed adipose tissue, by grafting a portion of the fat from around a recently removed scirrhus of the breast beneath the dorsal skin of a guinea-pig.

The tumour was removed on April 11th, 1896, and the experiment carried out a very few hours after its excision: the piece of fat was cut out with scalpels (sterilised by heat), and in chief diameter was about 1·2 centimetres; it was pushed into a pocket of the subcutaneous tissue some way from the incision, which was carefully closed with many interrupted sutures of fine carbolised silk.

The wound healed rapidly without infection, and on May 9th (about four weeks afterwards) the graft, which had not diminished in size, was exposed by incision; it was of a bright yellow colour, elastic, and surrounded with a thin transparent capsule, freely moveable beneath the skin, and exactly like a small lipoma in the subcutaneous tissue, which was otherwise free of fat.

Finding that no necrosis had ensued, the wound was re-sutured, and the tissue, which had not been cut into, left *in situ*. Healing was again perfect.

On May 27th (about six weeks after the original operation) the animal was killed and the graft removed. I was surprised to find again that no microscopic alteration had taken place; the tissue was, as before, loosely encapsuled, devoid of any opacity or whiteness like saponified fat, and when cut across it presented exactly the characters of normal adipose tissue, as it did also histologically after preparation.

For some depth between the vesicles there were broad strands of highly cellular connective tissue, like the parts of lipomata when growth is actively proceeding, and with scarcely a leucocyte to be seen.

The graft had undergone no necrosis; on the contrary, it presented the marks of cell proliferation or growth. *May 19th*, 1896.

---

2. *Saponifying necrosis in a lipoma of the breast.*

(*Card specimen.*)

By J. H. Targett.

Clinical History.—From a woman aged 79, who died in an infirmary with extensive bedsores over the sacrum and trochanters, calcareous arteries, gangrene of the right foot, and bronchitis. She was blind from a cataract in the right eye, the left eye

having been enucleated ten years previously. Above the left breast there was a tumour the size of a child's head, which had begun as a small lump and had existed for at least forty years. This tumour felt like a lipoma except for a nodule of stony hardness in the centre of the swelling.

Description of specimen.—The tumour is flattened and circular, in shape like a bun, with a diameter of about five inches. It is surrounded with a fibrous capsule like a lipoma, and in its colour and general appearance it resembles that variety of tumour. A horizontal section of the mass shows that it is made up of lobules of fat held together by thin strands of fibrous tissue. In the middle of the cut surface are seen two distinct cretaceous masses; they have a roughly triangular outline, and measure 2½ inches and 2 inches respectively in their chief diameters. Further examination shows that these masses are of the nature of cysts, with walls composed of fibroid and calcareous material, and filled with a fatty substance of a yellowish-white colour in which there is no calcareous deposit.

Remarks.—These encysted masses have not the characters of old degenerated hydatid cysts. From the contiguity of the tumour with the left breast it might be suggested that they were mammary cysts filled with fatty concretions. But from the shape and well-defined outline of the tumour it may be concluded that these masses are large degenerative foci in a lipoma. Such degeneration is due to localised necrosis of the adipose tissue with saponification of the fat, and in this instance it has been followed by calcification of the periphery of the necrotic area. See Mr. Shattock's paper on p. 246. *March 3rd*, 1896.

---

3. *Encysted fatty concretions in a breast affected by chronic mastitis.*

By W. Watkins-Pitchford, M.B. (per S. G. Shattock).

The following is the history of the case from which these specimens were obtained:

Mrs. H—, a married woman 46 years of age, was admitted to the

Bridgnorth and South Shropshire Infirmary, May 18th, 1894. She complained of "something growing in the left breast."

Her previous history throws some light on the case. During twenty-two years of married life she had given birth to ten children, all of whom she brought up at the breast. She never weaned a baby until it was sixteen or eighteen months old. When she first noticed anything wrong with the left breast (which was twelve months before admission) she was suckling her youngest child, then twelve months old; she continued to suckle it for another six months, and observed that some small hard lumps had appeared in the breast, and that the milk came with difficulty.

On examination the patient proved to be an emaciated woman, saying that she had lost flesh during the last six months. She was dyspeptic. The viscera and secretions appeared normal. The left breast was tender, but no secretion could be squeezed from the nipple; in the lower half of the organ were two or three wedge-shaped masses of indurated and thickened gland tissue. Embedded in these masses, well outside the areola, were three or four hard nodules of rounded outline; retraction of the nipple was produced when the nodules were dragged centrifugally. There was no adherence to or puckering of the skin; there were one or two distinctly enlarged soft glands in the left axilla. The right breast exhibited some signs of chronic mastitis, but no nodules were to be felt.

The breast was amputated, and the axilla cleared out by the surgeon under whom the case had been admitted. The patient is now (March, 1896) in good health; the chronic mastitis in the right breast has resolved.

Upon examination of the affected portion of the left breast the appearances presented were in the main those typical of chronic mastitis; besides the abundance of fibrous tissue there were numerous minute cysts containing milk in various stages of inspissation. Embedded in the gland substance were several round fatty concretions, the largest of which are exhibited. Each concretion occupied a distinct cavity, the walls of which consisted of dense fibrous tissue with a smooth lining, and could be shelled out with the greatest ease after incision of the cyst wall. Whether these fatty concretions had been formed in the smaller ducts, or in the acini, could not be determined. The weight of the largest was ten grains. Microscopic examination of the concretions revealed only

granules and amorphous greasy-looking masses. The enlarged axillary glands presented the appearances of simple induration.

When we consider the pathology of chronic mastitis, it is very difficult to explain why these concretions are not more frequently met with in cases of that disease when accompanied by lactation. We may take it that they have arisen by a process of inspissation of the contents of galactoceles, the fluid and proteid constituents having been absorbed. The cysts were in the first instance the result of the dilation of acini or ducts due to the partial or complete obliteration of the lumina of the galactophorous channels by contracting fibrous tissue. The ducts being obstructed, and the formation of milk still proceeding under the stimulus of continued lactation, an impaction as it were of the cyst cavities by the more solid constituents of the milk has been brought about.

Note by Mr. S. G. Shattock.—The concretions consist, as the author states, almost entirely of fat. When boiled in a flask of ether by means of a water-bath, there is left, after repeated changes of the fluid, only a small amount of insoluble residue. Examination of this in glycerine shows it to consist of irregular flakes of a finely granular substance, which might be casein coagulum originally present, or albumen coagulated by the method employed to remove the fat. The insoluble residue was gently dried and tested for lactose by the phenyl-hydrazine method. It was boiled with distilled water, filtered whilst hot into a wide test-tube, and again boiled in a water-bath for several hours after the addition of phenyl-hydrazine and sodium acetate, being subsequently filtered hot to remove excess of the first-named substance. The bulk was finally reduced in the water-bath and the fluid allowed to cool slowly.

After standing twenty-four hours the deposit was examined with a pipette; it contained no crystals whatever (phenyl-lactosazone). From the small amount of solids present, it may be concluded that the concretions have not resulted from the curdling of retained milk, such as might be brought about by bacteria within the ducts.

March 3rd, 1896.

4. *Macrodactyly due to diffuse lipoma.*

By Robert Jones (per D'Arcy Power).

This specimen consists of the right thumb and index finger, removed from a girl aged 18 months. She is the third child of the father's second wife. He had two children by his first wife, but none of the family present any congenital deformity.

An enlargement of the right hand was noticed at the time of the child's birth, and it was taken to Dr. Hugh Jones of Dolgelly for advice when it was nine or ten days old. The swelling, however, seemed to be so trivial that nothing was done for it. It continued to increase in size steadily, and in six months' time it impeded the movements of the hand. The inconvenience increased

Fig. 18.

until at the age of eighteen months the parents determined to have a radical operation performed, and the child was taken to Liverpool

to be under the care of Mr. Robert Jones. The cause assigned by the mother is that she carried the previous child a great deal in her arms and against her side when she was pregnant. She imagines that this caused some local pressure upon the deformed parts.

The right hand presents the remarkable appearance seen in Fig. 18. The arm is increased in size. The hand is deflected to the ulnar side. The thumb is widely abducted, and its ungual phalanx is hyper-extended. It is uniformly enlarged, and measures 2½ inches in length and 4½ inches in circumference. The forefinger shares the ulnar deflection of the hand. It is uniformly enlarged like the thumb, and measures 3½ inches in length by 4½ inches in circumference. The third, fourth, and fifth fingers are normal in size and shape. The thenar side of the hand is puffy and enlarged both upon its palmar and dorsal surfaces. The swelling is smooth, not lobulated, soft and elastic. The skin was a little redder than natural, but there was no venous enlargement. The thumb and forefinger could be moved a little, but there was free movement in all other parts of the hand. The nails of the finger and thumb were flattened and proportionately increased in size, but they were otherwise normal. The hand was so useless that the thumb and forefinger were amputated. The patient made a good recovery, and six months after the operation her two hands were almost of equal use. Dissection shows that the increased size of the finger and thumb is due solely to an increase in the amount of the subcutaneous fat. The deposit of adipose tissue in the thumb being greater upon the palmar than upon the dorsal surface has led to the hyper-extension of its terminal phalanx. The muscles have become involved in the fatty overgrowth. There is no evidence of any lymphangiectasis. The bone is somewhat rarefied. It cuts readily, and contains soft yellow marrow.

A microscopical examination shows that the epithelium is unaltered. The superficial layers of the true skin are firm and somewhat denser than usual. The deep layers are replaced by an enormous overgrowth of true adipose tissue, which is held together by a strong framework of fibrous tissue carrying the blood-vessels. The adipose tissue is in every respect normal, but it has grown to such an extent that it has involved the subjacent voluntary muscles, and has split them up into their component bundles, whilst in a few places it has invaded the interfibrillar connective tissue. The individual muscle-fibres, however, are striated, so that the change is

rather one of fatty infiltration than of fatty degeneration. The blood-vessels are not enlarged, and the lymphatics are apparently unchanged.

Dr. Hugh Jones kindly sent the exhibitor some additional particulars about the case:—"The scar is quite linear, but the neighbourhood of the wound is very puffy, blue, and inclined to be cold. The whole limb is considerably enlarged right up to the shoulder. The measurements of the two arms differ greatly. The circumference of the hand round the scar is about one inch greater than round the left hand at the root of the thumb. The difference in circumference at the middle of the forearm is about 1½ inches; whilst at the middle of the upper arm it is half an inch. I can detect no indication of a similar condition in any other part of the body. It certainly does not exist in the other hand or in either foot. There is a little difference in the arrangement of the folds on the inside of the thighs, but the measurements are equal."

Remarks.—The case is interesting from several points of view. In the first place it is a true case of macrodactyly, agreeing with the majority of the cases recorded in the facts that it occurred sporadically in the family, that it was unilateral, and that it did not affect all the digits; but differing in that it was truly congenital, whereas most of the cases occurred after birth. The necessity for amputation set at rest the true nature of the enlargement. We are a little apt in many of these cases of overgrowth to blame the lymphatic system, and to look upon them as the result of lymphangiectases or of lymphangiomata. This error is due to the teaching that lipomata are rare in the limbs. No doubt in adults they are, but in children fatty tumours occur rather frequently as congenital defects. Mr. Adams ('Trans. Path. Soc.,' vol. v, p. 327), Mr. Gay (ibid., vol. xiv, p. 243), and Mr. Lockwood (ibid., vol. xxxvii, p. 450) have recorded cases of lipomata in the extremities. A case of Mr. Adams' recorded by Mr. Lockwood is very similar to the one shown this evening. It was a fatty tumour removed from the palm of the hand of a young lady aged eighteen years, in whom the swelling was first noticed at the age of four years. The tumour grew slowly until it interfered with the movements of the hand. It was situated under one of the muscles of the thenar eminence, and sent prolongations through the palmar fascia.

A knowledge of these cases will incline us, perhaps, to be a little less conservative in our treatment of them. So long as we considered

them to be lymphatic in origin, so long were we inclined to leave them alone because such cases sometimes undergo spontaneous cure; whilst on the other hand they do not always heal kindly when an attempt has been made to excise them. Diffuse lipomata stand upon quite a different surgical footing. They may or may not be congenital, they consist of comparatively indolent tissue, they are small at first, they increase in size gradually, and they are capable of conversion into other and more stable forms of connective tissue. Early removal is therefore the proper treatment, but failing this, it might be well to adopt some method of reconverting the adipose into fibrous tissue. *November 19th*, 1895.

---

5. *Osteomata from the scalp.* (*Card specimen.*)

By Sydney Jones.

Three flattened tumours about a quarter of an inch in chief diameter, which had been noticed two or three years. They were situated about an inch to the right of the median line, and were quite distinct from the periosteum and bone; they had apparently developed in the occipito-frontalis, and were covered with thin skin. Ground preparations showed that the structure was that of true osseous tissue (Mr. Shattock).

There were four or five similar tumours on the left of the median line.

They were removed from a gentleman sixty years of age.

May 5th, 1896.

---

6. *Lymphangioma cavernosum from the parotid region.* (*Card specimen.*)

By H. Betham Robinson, M.S.

Clinical History.—John G—, aged 3 months, was brought to me at the Children's Hospital, Shadwell, in August, 1894. The child was full term, and at birth well nourished, but since that time he had rapidly lost flesh. A few days after birth the

mother noticed some swelling behind the angle of the right side of the jaw, which gradually increased in size and varied from time to time. The swelling, which was quite free from the skin, appeared to be in intimate connection with the parotid gland, dipping in behind the jaw and extending a little in front of the ear. It was soft, doughy, and ill-defined, but apparently cystic. There was no facial paralysis.

As at the expiration of a fortnight it had increased so much in size as to cause very definite prominence behind the angle, the child was taken into the hospital, and on August 23rd I explored it. An incision was made behind the ramus below the line of the facial nerve down to the fascia. The latter was bulged, and on dividing it small rounded cystic swellings appeared. The most superficial were opened, and a clear straw-coloured fluid set free. The cysts had smooth walls, and showing through their floors other cysts were seen, which were punctured. It then appeared evident that the cysts were intimately incorporated with the gland, and that any attempt at separation would be futile. All the cysts that could be got at were punctured, and the wound washed out with carbolic lotion and closed. It healed by first intention.

On September 18th it was noticed that the swelling was reappearing and was definitely cystic. On September 25th the swelling was very much larger, somewhat lobulated, and now distending the scar of the operation. The child had wasted very much, and was very feeble. He was readmitted, but died on the 29th.

At the autopsy there were no other lesions detected except that of the parotid gland. This was taken out, and it was found riddled with smooth-walled cysts filled with straw-coloured fluid, varying in size from a walnut downwards. It was not satisfactorily made out whether the cysts were strictly localised to the parotid gland or not.

Histologically the tissue shows masses of very imperfectly developed parotid gland embedded in a connective tissue which is very cellular, but not out of proportion to the age of the child. Cystic spaces of varying size are scattered among the former tissue; their walls contain involuntary muscular fibres, and they are evidently venous or lymphatic spaces. From the character of their contained fluid there is no doubt which of the two they correspond to. In a few of the spaces coagula are to be seen, the fibrinous threads entangling a very large number of white discs. *March 3rd*, 1896.

7. *Loose bodies from a subdeltoid bursa.* (*Card specimen.*)

By J. Jackson Clarke, M.B.

This specimen is shown by the kind permission of Mr. Edmund Owen, and is thus described in the catalogue of St. Mary's Hospital Museum:

"No. 476 c.—About fifty bodies which vary in size from pigeons' eggs to peas. They have a laminated structure, and many of them contain towards their central part one or more spaces. The latter were filled with clear fluid. Under the microscope sections of the bodies showed centrally a coarse network of anastomosing trabeculæ, consisting of a substance which, when stained with hæmatoxylin, had a cloudy appearance. In all probability the trabeculæ consist of altered fibrin. Externally definite concentric lamellæ with nuclei resembling fibrous tissue were seen to take the place of the irregular trabeculæ. There were leucocytes in all parts of the section. The condition appears to correspond to Volkmann's 'synovitis fibrinosa.'

"From a boy aged 8, who fell on the outer side of the right shoulder four months before admission. A swelling appeared immediately after the accident, and gradually increased up to the time of admission. There was no pain, and the limb could be moved in all directions. The contents were evacuated through a simple incision which healed rapidly. There was no fluid in the joint."

April 21*st*, 1896.

---

8. *Syphilitic lesions of lymphatic glands.*

By J. Jackson Clarke, M.B.

The occurrence of gummata in lymphatic glands is not so exceptional as one might be led to infer from the absence of any notice of the condition in ordinary text-books. The only com-

munication I remember to have read relating to this subject was that made to the British Medical Association by Mr. Hutchinson, jun. This disease is likely to be met with more frequently as a clinical condition than in the *post-mortem* room. I propose to give first what I take to be an example of the clinical aspect of the condition, then a case in which I had the opportunity of examining the *post-mortem* anatomy of the disease.

The first case was that of a woman aged 55, an out-patient at the North-West London Hospital. She had suffered from tertiary syphilitic lesions, chiefly of the skin of the head and nasal fossæ. After an unauthorised interval of attendance she presented herself in a condition of pronounced anæmia, and with enlargement of the left cervical and axillary glands. The glands felt hard, like so many hazel-nuts beneath the skin. There was at this time no discoverable active lesion in the nose, throat, or skin. The hardness and enlargement of the glands rapidly cleared up under iodide.

The following case I examined *post-mortem*, and from it I obtained the sections of lymphatic glands which are placed before the Society. The history is as follows:

Man aged 25, admitted to St. Mary's Hospital, under Sir William Broadbent, on March 8th; died March 22nd, 1895. Admitted complaining of pain in the right side. On February 28th had been suddenly seized with pain in right lumbar region and abdomen. A few days before admission pain extended from the loin to right testis. Temp. 100·2°. Rigidity and some tenderness in right lumbar region. Urine smoky, with dark flocculent deposit. A firm clot 9 inches in length passed in urine. No cardiac murmurs. Marked enlargement of cervical glands. March 19th, had some pain at the lower part of the right chest on deep inspiration. March 22nd, several attacks of pain in right side with great dyspnœa. Much collapsed. Died in one of these attacks.

Autopsy.—Body extremely anæmic. Heart normal. No old clot or vegetations. Right lung showed many recent infarcts in lower lobe. The larger branches of the pulmonary arteries on both sides contained adherent, laminated and decolourised clot.

Left kidney weighed 7 ounces, and save for increase in size was normal. Capsule of right kidney was thickened and adherent to perinephritic fat. On section the right kidney was pale and tough. At the junction of the ureter and the pelvis there was an ulcerated surface with raised margins. This ulcer completely occupied the

circumference of the tube for over half an inch. The right renal artery was occluded by old adherent clot. The liver contained many scarred gummata.

The cervical glands of the right side contained recent gummata, ranging in size from that of a pea to that of a filbert-nut.

October 15*th*, 1895.

---

9. *The non-existence of "round-celled sarcoma" as a distinct class of new growths.*

By Herbert Snow, M.D.

A generation since malignant growths fell for the most part into two main groups, "hard" and "soft" cancers. The latter, known also as encephaloid or medullary, embraced several species of tumour, widely diverse in origin and in clinical career, and in almost every particular excepting the one common quality of a soft, pulpy consistence. I conceive that at the present day, in spite of material pathological advances since the epoch in question, the word "sarcoma"—particularly "round-celled sarcoma"—is very commonly applied in quite as vague a sense to any malignant tumour characterised by exuberant cell-growth, quite irrespective of the tissue origin thereof.

The connective tissues, so far as I have yet seen, give origin to a malignant lesion invariably characterised by spindle-celled tissue in some form or other. The degree of organisation varies, of course, considerably, but there is always some attempt thereat; and, in consequence, we find spindle-cells arranged in strands or bands over considerable tracts of even the most acute sarcoma properly so called. In the more chronic growths these strands constitute the whole; in the former they are mingled with clusters of round or oval cells, containing the usual multiplicity of nuclei characteristic of malignant processes in any form. There is, in fact, but one true cancerous outgrowth of the connective tissues, viz. the spindle-celled sarcoma, acute or chronic, with or without special modifications, such as the presence of pigmentary degeneration or of myeloid cor-

puscles. I have never yet been able to satisfy myself that these tissues ever generate a new growth solely composed of round or oval cells.

Of what nature, then, are the tolerably prevalent tumours entirely constituted of round or oval-celled parenchyma? They will all be found on careful examination to fall into one of three divisions—carcinoma, lympho-carcinoma, and blastoma. Large exuberant masses appear in the female breast; when removed, a thin section from the central portion shows the microscopic phenomena in question, with few or no traces of alveolar structure. If, however, the precaution be taken of examining the edges, no one would fail to recognise the disease at a glance as a true carcinoma. One often reads of sarcoma of the breast; but that lesion is decidedly rare, except perhaps in association with cysts.

A second division can be usually traced to a lymph-gland; or, failing that, to some area of adenoid tissue. The tumour will show the minute round or oval cells, also containing huge and multiple nuclei, which characterise the "lympho-sarcoma," or, as I greatly prefer to call it, "lympho-carcinoma." Among the adenoid tissues ranks the marrow of bones, and a malignant development from that structure consists of small round cells devoid of the spindle element. An interesting case, in an infant, which I take to be of this derivation, was published by Dr. Railton, of Manchester, in the 'British Medical Journal' of June 18th, 1895; and about the same time I had occasion to remove part of the foot of a young girl for a similar growth from the first metatarsal bone.

Then, lastly, very malignant tumours, consisting wholly or almost so of rounded cells, arise in such parts or under such circumstances as to leave no doubt of their origin from unobliterated rudiments of fœtal structures. This class of congenital cancers, so to speak, complies with the theory of Cohnheim, and has, for many reasons, to be considered on a wholly different footing from ordinary sarcoma or carcinoma; hence I have ventured to propose for it a distinct title,—blastoma. Into such a division will fall many tumours attacking the kidney of the child or young adult; forty-one cases are tabulated by Dr. Bertram Windle in the 'Journal of Anatomy and Physiology,' vol. xviii, p. 166. Many lesions occurring for the most part in childhood or early youth in the ovary, palate, mediastinum, bladder, prostate, &c., will also fall into this group.

As an instance of error in the classification of a new growth consisting of round-celled parenchyma, I may be permitted to mention melanotic cancers of the integument, formerly termed "melanotic sarcoma;" and as the huge multinucleated cells often fill little loculi, sometimes "melanotic alveolar sarcoma." In 1892 ('Lancet,' October 15th), I was enabled to demonstrate, by the examination of twenty cases, that this disease really arises from the pigmented epithelium of the rete Malpighii; that melanotic sarcoma, properly so called, springs only from the eyeball; and that for the simple reason there is no pigmented connective tissue which can give rise to it, melanotic sarcoma attacks the skin only under the rather exceptional occurrence there of degenerate nævoid tissue. As a year later, Unna of Hamburg ("Nævi and Nævo-carcinoma," 'Berlin. klin. Wochenschrift,' vol. i, 1893) independently arrived at the same conclusion, this may reasonably be regarded as established.

The term "round-celled sarcoma" is time-honoured and deeply rooted in medical literature; it is also often a very convenient one for malignant lesions of dubious origin. If, however, I can induce pathologists to regard the word, and the fact it implies, with only a very slight degree of suspicion, I feel confident that they will soon arrive at the same conclusion as myself, viz. that the spindle-celled sarcoma, acute or chronic, is the one true malignant product of the connective tissues; and that all new growths, solely composed of round or oval-celled parenchyma, are not derived from those structures, and therefore should be placed in some other category than the sarcomata. *November 5th*, 1895.

---

10. *Chondrifying sarcoma of the humerus following upon a fracture.*

By Samuel G. Shattock.

Whilst fractures of the long bones frequently ensue on the growth of tumours involving them, the rarity of the converse is such as to make the following case worthy of record.

It may serve also to raise the question, Why is this sequence so rare?

The specimen I have described in the catalogue of St. Thomas's Hospital Museum as follows:

No. 625A.—A vertical section of the upper half of a left humerus. About three inches from its upper end it is surrounded, but unsymmetrically, by a subperiosteal sarcoma in which the microscope shows the presence of cartilage. The growth has a lobulated outline, in places infiltrates the muscles, and occupies the interior of the bone for a distance corresponding with its outward extent. The outer half of the shaft is to a large degree replaced by the growth, and the continuity of the inner wall is barely traceable between the intra- and the extra-medullary portions of the tumour.

The original fracture appears to have united with scarcely a trace of displacement.

History.—G. C—, aged 33, a policeman, admitted under the care of Mr. Mackellar, without history of syphilis or phthisis. Four and a half months previously he fell heavily against an iron railing, and broke the left humerus near the middle. Splints were kept on five and a half weeks; when these were removed the arm felt normal, and union was complete. A month and a half after the discontinuance of the splints the patient noticed for the first time a lump in the region of the fracture after a strain; this increased somewhat rapidly ever since, and for a while was regarded as an excessive production of callus.

Recovery ensued after amputation at the shoulder-joint. Death took place about two years afterwards with symptoms of recurrence in the chest.

Histology.—Hardening in Flemming's fluid; stain, carbol fuchsin. The growth is constructed of spheroidal cells with large, clear, vesicular, finely granular nuclei furnished with one or more nucleoli. Karyokinetic figures occur here and there in the tumour-cells. A few of the cells are polynucleated, and of correspondingly larger volume. In some of the tumour-cells the nuclei have undergone fragmentation, the chromatin being dispersed through the cell body in variously sized, deeply stained, spheroidal masses.

The method of preparation displays very clearly a complete network of cement or ground substance, which is brought into view in consequence of slight shrinkage of the cells. The lines of this substance are particularly hard and sharp, and appear more deeply

coloured than the cells,—a result due to their being the optical sections of thin planes of the material in question. By imperceptible degrees the ground substance increases in amount until the cells, retaining their forms, become disparted by wide tracts of a clear intercellular matrix. A few of the cells, embedded in the chondrigenous matrix, are regularly spherical; mostly they are spheroidal and like those of the general tissue. The capillaries are not mere channels between the cells, but, as seen in their longitudinal sections, have nuclei pertaining to a proper wall of their own; the nuclei are oval and elongated in the long axis of the vessel, and both in form and arrangement are obviously different from those of the cells immediately around them. The section comprises the fibrous capsule or periosteum of the growth, and beneath this, in the most external part of the proper tumour substance, are flattened processes of osteoid tissue, or of cartilage with stellate cells, for a chemical test could alone decide between the alternatives.

Remarks.—In face of the fact that the fracture of a long bone is not infrequently the first, and for a while the only evidence of the growth of a tumour, the contrary sequence is one not easy of proof, and Virchow, in discussing this subject, frankly states that in two of the small group of cases he cites, the sequence in question had been considered doubtful by other observers of repute. Amongst instances forthcoming from London museums there are two at St. Bartholomew's; in one (No. 454) the sequence, it seems to me, admits of doubt. The other, No. 854A, is the section of a tibia in the upper end of which there is "an ununited fracture." "A periosteal sarcoma springs from the bone at the point of fracture, and extends outwards into the surrounding tissues, and inwards along the medullary canal, absorbing in its growth one side of the wall of the bone. The lower fragment is displaced inwards and slightly forwards. From a man aged thirty-seven, whose tibia was fractured by a kick eight months before amputation through the thigh was performed. Growth was observed four months after the injury in the form of three small lumps, situated one below the other on the outer side of the tibia at the level of the fracture. One uncle died of cancer of the lip, which was said to have followed a blow."

In the Society's 'Transactions' (vol. xxxvi, p. 388) there is Mr. Bilton Pollard's case, but here the new formations, which presumably followed fracture of the tibia and fibula, are not sarco-

matous, but osteomata, or, as the author names them, "excessive growths of callus."

Yet the rarity of the sequence may be judged by the fact that Mr. Butlin, in his works on "Sarcoma and Carcinoma," and upon the "Operative surgery of malignant disease," does not even allude to it.

The large proportion of cartilage in the histological section is noteworthy in connection with the exciting cause of the growth. It relates the new formation to the reparative callus, which, as is now generally known, in simple fractures in the human subject undergoes a certain amount of cartilaginous metaplasia.

The reflections which Virchow makes on this subject he places in his lecture on enchondroma, since the macroscopic and histological examination of the tumours showed them to have consisted largely of cartilage. In the only case examined by Virchow himself, Langenbeck had disarticulated the arm of a man twenty-three years of age for a growth which had appeared a year and a half after a fracture following a fall; the tumour was an "osteoid chondroma," or in other terms a chondrifying sarcoma.

It is not a little remarkable that the sequence under consideration should be so rare, seeing how common a part traumatism plays in the growth of sarcomata affecting the ends of the long bones, where there is frequently a history of antecedent contusion. In this the ætiology of new growths is exactly paralleled by that of tuberculosis. Here, too, the disease, so far as it affects the long bones, is rare except in the articular ends, and here, too, it is often enough related to similar injuries; whilst, on the contrary, it is unknown as a consequence of fracture. Those who adopt a microparasitic theory of cancer will read a meaning in the parallel without difficulty. In the case of tuberculosis it has been suggested that the more violent injury—the fracture—is followed by such active cell-division that any virus already latent in or reaching the spot is unable to thrive. There is the old therapeutical observation that the spread of cutaneous erysipelas may be stopped short by the application of a solution of nitrate of silver over and two or three inches beyond the affected part, and an account of the similar utility of tincture of iodine has been supplied by Dr. Cartwright Wood and Dr. Maxwell Ross ('Edin. Med. Journ.,' May and June, 1891; and 'Reports from the Laboratory of the Royal College of Physicians,' Edinburgh, 1891). It is sufficient that the tincture be applied in the form of a broad ring encircling the affected portion

immediately beyond the congested skin. Here the non-infective inflammation set up by the irritant stops the spread of the infection by successfully opposing the advance of the micrococcus. Dr. Cobbett and Dr. Melsom ('Journ. of Pathol.,' November, 1894) conclude also, from experiments on local and general immunity based upon experimental erysipelas in animals, that "a rapid inflammatory reaction is the chief factor in the production of immunity, both local and general." The successful issue attending the use of tuberculin in the case of small tubercular lesions demonstrates that the same really does hold true in tuberculosis itself. In regard to the rarity of sarcoma following upon fracture, and its frequency after less grave injuries, the same explanation may be advanced; the reaction after the fracture is such as to prevent the growth of the hypothetical virus producing the malignant disease.

Another fact has, however, to be considered. Bacteria, when introduced into the circulation experimentally, rapidly disappear from the blood-stream, and are found located (as is now well known from the work of Wyssokowitch, 'Zeitschrift für Hygiene,' Koch and Flugge, Bd. i, 1886) particularly in the bone marrow, spleen, and liver; and the same is true of dead particulate material which reaches the circulation. In the curious osteitis which occurs in the Viennese mother-of-pearl turners, the inspired dust becomes located in the growing ends of the bones, the disease being confined to adolescents. In Berlin, where young persons are not so employed, the affection is rare. Levy ('Berlin. klin. Woch.,' No. 45, 1889; cited by René Condamin, 'Pathogénie des diverse ostéites,' Paris, 1892) relates the first five cases of the kind observed in Berlin; in one there became affected in succession the upper jaw, the lower jaw, and the inferior third of the shaft of the humerus. In another case there was first osteitis of the right scapula, then of the right upper jaw, the right clavicle, the left upper jaw, and finally three of the left metacarpal bones and the right femur.

It is in the *red* marrow that the localisation of particulate material takes place,—in the tissue, *i. e.*, which resembles the spleen in its vascular mechanism and the large amount of lymphatic tissue of which it consists. Ponfick (Virchow's 'Archiv,' Bd. xlviii, p. 34), in repeating Recklinghausen's experiments, has found that after introducing cinnabar into the circulation, the particles of this substance found in the marrow of spongy bones and long bones lie in

the proper marrow-cells, whilst the cells of the reticulum, like the fat-cells of the bone-marrow, contain little of the colour stuff.

Now in the bone tuberculosis following trauma it must, I submit, be assumed (at least in many cases) that the virus is located in the marrow before the date of the injury. Indeed, injury is not any more strictly necessary here than it is to induce an acute infective periostitis or acute infective "epiphysitis;" the location of the virus is the same in the tubercular and in the pyococcal epiphysitis. Doubtless there is, in most cases of bone tuberculosis, prior tubercular disease elsewhere, as in lymphatic glands, &c.; but this indicates rather that osseous invasion has arisen from a slow leakage of bacilli beyond the glands through the lymphatic vessels, and ultimately into the blood-stream. It is not only unnecessary to assume that a sudden and direct transference of the virus takes place in all cases, but such a supposition borders upon the absurd, for it implies that the escape of tubercular *débris* from a softening focus elsewhere exactly coincides with an injury which is the result of a pure accident, such *débris*, on reaching the stricken spot, setting up a specific inflammation.

These considerations will show the higher probability of sarcoma ensuing after an injury of cancellous or red-marrowed osseous tissue than after a fracture, say, of the shaft of a bone involving adipose medulla.

In the case described in this paper the site of fracture is not traceable in the section, but the cancellous tissue of the upper end of the shaft is occupied by the substance of the tumour; and in the specimen referred to in St. Bartholomew's I find that the upper part of the present fracture is three quarters of an inch only from the upper articular surface, and the lower end two and a half inches. Nevertheless we have in the opposite scale of the argument the weighty instances of epiphysial separation in the young which are not followed by the growth of sarcomata, though here the growing end of the diaphysis is involved in the injury, and (as pointed out by Mr. Pearce Gould) such fractures through cancellous tissue as those of the patella, cervix femoris, and ankle-joint. Of the two elements submitted, therefore, the fact that the epiphysial separation or fracture is a graver injury than contusion, and incites a greater serous effusion and more active cell-proliferation, is probably a more potent one than the localisation of the hypothetical virus in red-marrowed tissue. Every sarcoma of bone ensuing

upon traumatism, however, does not arise within the medullary tissue; the tumour may be subperiosteal. In this we have a hypothetical location of virus parallel with the subperiosteal location of the tubercle bacillus or of pyogenic cocci which obtains in subperiosteal tuberculosis and the acute infective periostitis of children and adolescents. *April* 21*st*, 1896.

---

11. *Sarcoma of mamma containing multinuclear giant-cells. (Card specimen.)*

By H. D. Rolleston, M.D.

[With Plate II, fig. A.]

The tumour, which had grown rapidly, was removed by Mr. Pick from a woman aged 44 years. Recurrence rapidly took place, and the patient was readmitted under the care of Mr. Sheild. Coley's fluid (toxins obtained from cultures of streptococci, etc.) was injected into the tumours, which diminished very considerably in size. Before being used the fluid was examined by Dr. Slater, and found to be sterile. The injections were repeated on several occasions. The bottle was finally exhausted by two injections, one in a patient with scirrhus mammæ involving the skin, in whom it had no effect; the other into this patient, who died rapidly in forty-eight hours with multiple abscesses in every part of the body except the lungs. The brain contained hundreds of minute hæmorrhagic abscesses, and the thyroid gland showed a large number. The liver contained numerous pyæmic abscesses. The pus examined by Dr. Slater contained *Staphylococcus pyogenes aureus.*

The tumour occupied the greater part of the left breast, but did not infiltrate the skin, which together with the nipple was quite free from and unattached to the growth. It was sharply limited, and surrounded by some condensed tissue so as to be encapsuled. It was of a greyish colour, and showed numerous areas of necrosis which easily crumbled away, but was nowhere hæmorrhagic. Microscopically the tumour was composed of cells of varying size and shape (Plate II, fig. A). Between the cells there was a delicate

reticulum like that seen in a lympho-sarcoma, passing between and often separating individual cells. This was best seen in fresh sections stained in picro-carmine. There was, however, no alveolar arrangement, and the structure was not that of carcinoma. Scattered at intervals through the growth there might be seen the remains of the fibrous tissue and of the gland-tubes of the mammary gland, but there was not the least resemblance to an adeno-sarcoma. The gland-tubes seen showed no proliferation, and were evidently in process of destruction from without by the sarcoma cells. The cells of the tumour were round or polyhedral, and the majority, of a rather large size, showed a well-marked nucleus surrounded by a zone of protoplasm of considerable breadth. Among them, and comparatively numerous, were larger cells, containing several nuclei, the nuclei being, as in the giant-cells of a central sarcoma of bone, in the centre of the cell. These multinuclear cells were, if anything, rather less numerous near the necrosed areas. A prominent feature was the large size of the nuclei even when multiple. In this, and also in the fact that the number of nuclei in any cell seldom exceeded five, these large nucleated cells differed from the myeloid cells often found in central sarcomata of bone. In some cases the nucleus was very large, as if composed of several; in other cases it appeared lobulated, as if about to divide into several separate nuclei (Plate II, fig. A).

These appearances, taken together with the rapid growth of the tumour clinically, suggest that the presence of these multinuclear cells is due to rapid nuclear division, with which the cell-division could not keep pace, and not to the fusion of previously distinct and separate phagocyte cells into a plasmodium-like mass. This latter is the mode of origin of the giant-cells of the infective granulomata, more especially in tuberculosis, and of those seen surrounding resistent material when undergoing absorption, such as bone, blood-clot, elastic tissue, &c.[1] Duenschmann[2] has recently described the giant-cells in squamous-celled carcinoma as exerting a similar phagocytic action on leucocytes and cell nests. While the myeloid cells in central sarcoma of bone, both from their resemblance to myeloplaxes, and from the extensive absorption of bone which is a result of the tumour, would seem to have a similar function. Mye-

[1] For a discussion of this subject see Knud Faber, 'Journ. of Pathol.,' vol. i., p. 356, *et seq.*, "The Part played by Giant-cells in Phagocytosis."

[2] 'Journ. of Pathol.,' vol. iii, p. 118.

loid cells also occur in epulides, and in tumours arising from the fibrous sheaths of the tendons.[1] This tumour was hardened in alcohol, and I could not satisfy myself that karyokinesis was present; and hence, though it seems probable that the multiplicity of nuclei is due to rapid division, and not to fusion of pre-existing cells, the proof is wanting.

As mentioned above, the large multinuclear cells in this specimen differ from the typical myeloid cells both in the size and number of the contained nuclei—a point which was rightly insisted upon at the meeting by Dr. Voelcker.

Large multinuclear cells are sometimes found in sarcomata arising in soft parts. I have seen this in a rapidly growing sarcoma of the body of the uterus.

Dr. Snow has described "myeloids" (giant corpuscles) in a spindle-celled sarcoma of the breast, but regarded them as "simply microscopic fragments of fibrin—minute blood-clots, in short."[2] As I have already said, their presence appeared to me to be the result of rapid nuclear division rather than of a plasmodial fusion process, which explains the giant-cells met with in chronic inflammation, especially when tuberculous. In a few spots there were some isolated blood-spaces, but no general extravasation of blood-corpuscles or pigmentation.

The drawing which is reproduced in Plate II, fig. A, was most kindly placed at my disposal by Mr. Marmaduke Sheild.

May 5th, 1896.

---

12. *Case of (?) metastatic sarcoma of both breasts; multinucleated giant-cells in the growth.* (*Card specimen.*)

By E. L. Fox (per J. H. Targett, M.S.).

Clinical History.—The patient was a housemaid, aged 16 years. In May, 1895, she had diplopia, and attended an eye infirmary for it. The right eye was regarded as paralysed. The following month she noticed "lumps" in her breasts, and complained of

[1] *Vide* Shattock, 'Trans. Path. Soc.,' vol. xliv, p. 134.

[2] Ibid., vol. xlvi, p. 186.

pains across the shoulders and in the right knee. The legs gradually became weak, and one morning she found herself unable to stand. No history of previous illness.

When admitted to the South Devon Hospital on July 31st, 1895, she presented all the symptoms of hysterical paraplegia, and there was complete incontinence of urine. Both mammary glands were enlarged, hard, and nodular; the hardness was so remarkable that it might be termed "stony." In this respect both breasts were alike. The lymphatic glands passing into the axillæ were enlarged and hard, as well as those behind the right sterno-mastoid muscle. In the epigastrium there was a small button-like nodule resembling a sebaceous cyst. The skin over it was thin, red, and adherent. It should be added that the urine contained a considerable quantity of pus.

August 15th.—A small swelling was noticed in the left temporal fossa. It slowly enlarged and gave much pain. There was also slight exophthalmos on the left side.

September 15th.—Lymphatic glands throughout the body appear to be enlarged and hard. In the abdominal walls there are numerous hard nodules, and the epigastric growth has increased in size.

October 30th.—There is marked deafness, the tongue is protruded to the right, and there is some optic neuritis. The breasts have enlarged considerably during the last few weeks, and they are much more nodulated than formerly. There is great weakness and emaciation. The patient died on December 12th, 1895.

The temperature was raised throughout the illness, and the highest record was 105·4° on September 8th.

Autopsy.—External examination of the body revealed multiple tumours in the integuments of the thorax, abdomen, and thighs, and in both breasts. There were petechiæ on the legs, especially over the right tibia. About three pints of clear serous fluid occupied the left pleural cavity, and the left lung was extensively collapsed. Growths were found on the inner surface of the wall of the thorax, and in the muscular substance of the right auricle of the heart. There was one small nodule of growth in the liver, and large masses in the pancreas and great omentum. Both kidneys contained deposits of growth and circumscribed areas of cretaceous material; there was also pus of a greenish colour in the pelvis of the left kidney. Both ovaries contained growths, and in the right

one there was a cyst 1½ inches in diameter. Lastly, there were growths firmly attached to the lower part of the vertebral column, but they did not involve the spinal cord. The head was not examined. All these growths were hard to the touch, and when cut across presented a firm, white, homogeneous structure. Histologically the tumours were sarcomata, chiefly of the round-cell type. The microscopic sections were taken from the breast and great omentum, and presented one or two peculiarities. In the first place the growth in the breast was remarkably diffused, and, though composed of round cells, was unusually firm for a sarcoma of that type. Microscopically it showed a very marked trabecular structure, the small meshes of which were filled with round cells. Thus it presented more than a superficial resemblance to a carcinoma. But on further examination it was clear that the trabeculæ of this alveolated structure consisted of the unabsorbed stroma of the organ. The strands were granular, almost devoid of nuclei, and in places hyaline from degeneration. Hence this alveolated stroma differed in its minute characters from that of a carcinoma, but its abundance in this tumour may be held to explain the unusual hardness above mentioned. The cells were small, round, and uniform in size; they did not run in lines like those of a scirrhous carcinoma, and the intercellular substance formed a delicate network in some parts of the section.

Another point of interest in the specimen was the abundance of multinucleated giant-cells[1] in some of the slides. They were not uniformly distributed throughout the microscopic section, but occurred in groups. The possibility of tuberculosis was considered, but there was not the least evidence of it. There was no inflammatory tissue, and no giant-cell systems or caseation.

The third point worthy of note was the presence of a few ducts and acini as the remains of atrophied lobules. These were not found in every slide, so that they must have constituted a very small proportion of the whole tumour. Undoubtedly the most striking feature of the growths in the breasts was their remarkable hardness, and this was noticeable from the first. During the last few weeks of life the breasts rapidly increased in size, but previously the progress of the growth had been extremely slow. The primary seat of the disease in this case was not determined. By some the nodule in the epigastrium was thought to be primary; at all events, it had

[1] See Dr. Rolleston's paper on p. 267.

existed as long as the trouble in the breasts, and grew so slowly that it never became larger round than a shilling.

April 21*st*, 1896.

---

13. *Secondary sarcomatous growth in the mamma.* (*Card specimen.*)

By H. D. Rolleston, M.D.

A T—, aged 33, three months after the birth of a child developed œdema of the arm, and subsequently numerous masses of new growth in various parts of the body, in the glands of the neck, the liver, the left breast, and the subcutaneous tissues.

The mammary nodule was not in the skin covering the breast, but was embedded in the substance of the gland, and had the same structure as the growths elsewhere, viz. a large oval-celled sarcoma with a tendency to an alveolar arrangement. The primary growth was a large sarcomatous mass in the anterior mediastinum.

The growth in the breast was about the size of a hazel-nut. It is possible that the increased vascularity of the gland, the result of a comparatively recent pregnancy, determined the occurrence of a secondary growth in it.

In cases of general dissemination of new growth secondary tumours have very seldom been recorded as occurring in the mammæ.

J. J. Clarke[1] mentions a case of lympho-sarcoma primary in the bronchial glands in which a nodule of pink growth appeared in the corium beneath the left breast. Probably the skin is more often affected than the underlying gland.

Dr. J. E. Pollock, in the third volume of this Society's 'Transactions' (p. 254), described a case of an "encephaloid tumour" in the anterior mediastinum with a scirrhus in the left mamma and a swelling in the right axilla. It does not appear certain whether the case was an example of two primary malignant growths occurring independently in different parts of the body, whether the mammary tumour was perhaps a fibro-adenoma, or whether the mammary

[1] 'Brit. Med. Journ.,' Jan. 18th, 1896, p. 135.

growth was secondary to that in the mediastinum. But the last view is somewhat improbable, inasmuch as the mediastinal growth is described as being encephaloid, and that in the mamma as scirrhous.

That the mediastinal growth was secondary to the mammary tumour is possible, but such a view is not mentioned in the paper.

This specimen is an exception to the general rule that organs in which primary growths occur are very rarely the site of secondary deposits. *January* 21*st*, 1896.

---

14. *Three cases of carcinomatous cyst of the breast.*

By Charters J. Symonds, M.S.

Case 1.—Ann W—, aged 28, came to Guy's Hospital early in December, 1885, with a small, flat, indefinite lump in the left breast. By January 18th it showed distinct fluctuation, and on being tapped yielded about half an ounce of clear fluid. In a month's time it was as large as before. It was now incised, when a solid growth was found in the bottom of the cyst. She was admitted into the hospital on February 22nd, 1896. The cyst was situated in the upper and inner quadrant, and the tumour was removed with most of the breast. The axilla was not touched, as the tumour was thought to be a sarcoma. On examining the specimen the small cavity was lined with soft fungating growth, and a white mass lay on the muscle beneath. The microscope showed the disease to be carcinoma. In January, 1887, she was readmitted with a mass in the axilla, and a nodule in the small portion of breast left behind. On removal the main mass was definitely encapsuled, and therefore not involving the fat in which it was embedded. The centre was caseous, and liquefied on being exposed for a few hours. The margin was whiter, firmer, and in active growth. The axillary fat was filled with large glands. On March 11th, 1888, she was again admitted, with a recurrent mass in the old scar, and with a history of six weeks' pain in the head and vomiting—indications of extensive recurrence in the brain.

On May 22nd I made the following note:—The patient was much lower, very thin; there was no paralysis of the eyes, or face, or limbs.

She protruded the tongue, but was incapable of replying to many questions. Vomiting continued, and she did not recognise people so well.

On June 3rd she was much worse; she had had no headache for four days,—that is, there was no complaint. The sickness had ceased, but still there was no sign localising the brain disease. She died on June 5th, 1888.

Autopsy.—A large mass of growth was found in the right lobe of the cerebellum. It consisted of a softened centre with a tougher wall, lined with caseous material, and contained a little puriform fluid. There was a smaller mass in the left lobe. In the right half of the cerebrum was a similar deposit beneath the supra-marginal convolution, but here it consisted more distinctly of a cavity lined with soft, greyish, vascular membrane, containing yellow puriform fluid. In the left hemisphere was a deposit at the back of the island of Reil, just behind the claustrum, and outside the internal capsule. This was softened in the centre. Similar deposits were found in the under surface of each frontal lobe. The lateral ventricles were dilated: there was no meningitis. All the deposits were remarkably alike and symmetrical. At first sight they appeared to be abscesses, being distinctly cavitated and having a lining membrane, while the surrounding brain matter was softened. The contents were thin yellow fluid, like diluted pus, but not at all like the creamy, thick pus of a typical cerebral abscess; moreover the lining membrane was not a typical pyogenic layer. As all the secondary deposits showed well-marked degeneration, though not actually softened, it seems probable that those in the brain were originally of the same nature, but that softening and puriform degeneration had altered their character.

The microscope showed in the periphery clear, succulent, growing epithelium, and in the rest degenerating cells. The nodule in the pectoral region was clearly a carcinoma. Secondary nodules were found in the lungs, the right bronchus, the liver, the adrenals, the kidneys, and ovaries.

Case 2.—Mrs. C—, aged 56, was sent to me by Dr. Boothroyd, of Brockley, on December 4th, 1894. She was a large, stout woman, and presented a good-sized tumour in the upper and outer part of the left breast. It had been first noticed fourteen days before. On December 20th there was distinct fluctuation without any overlying

hardness. An ounce of clear amber fluid was removed, and a deep hollow left, without surrounding induration; no other cyst existed on either side. No further operation was recommended.

On January 19th, 1895, the cyst was again tapped by Dr. Boothroyd on account of increasing pain, and on February 13th I removed the cyst, with some of the surrounding breast-tissue. It had a smooth wall, which was thin, except at one point where there was a suspicious nodule, which I regret to say was not examined. By July 23rd the swelling was as large as ever, and on the 31st of this month it was again tapped.

On October 19th, 1895, I found immediately beneath the old scar, which was stretched and thin, a large cyst, which showed dark through the scar. It looked perfectly simple in every way, but on account of its recurrence we decided to remove the entire breast, for which the patient was particularly anxious. On incising the cyst dark fluid escaped, and on inserting the finger the wall was felt to be hard and nodular. The axilla was not cleared, partly because the tumour was situated so far on the inner side of the breast, and partly because no lymphatic gland was felt, in addition to the fact of the tumour being a cyst.

The specimen shows an oval cystic tumour the size of a hen's egg. It is placed under the scar of the former incision, and is partially divided into two compartments by a thin septum. The wall of the cyst is irregularly thickened, and its inner aspect presents nodules and ridges which project into the cavity. The surrounding tissue is chiefly fat, with a small quantity of normal breast-tissue. To the deep surface a portion of muscle is attached. Microscopical examination of the wall of the cyst shows the ordinary appearances of mammary carcinoma.

Case 3.—Mrs. W—, aged 55, was a patient of Dr. F. K. Holman, of Hampstead. She had a mass in the outer quadrant of the left breast. It was hard, flat-topped, and nodular, with no fluctuation. As it had only been recently noticed, we decided to make a preliminary incision; an inch of dense tissue was cut through without evacuating any fluid. The whole breast was at once removed, and the axilla completely cleared out. On turning over the specimen to incise it from behind an ordinary dark cyst was seen, and I was dismayed at having removed a simple cyst. The interior of the cyst was smooth, excepting at one spot where a small glandular-looking

nodule was visible. This, on microscopical examination, showed the ordinary appearance of a carcinoma in an early stage. I regret that the specimen has been lost, but on inquiring of Dr. Holman a few days ago for the purpose of this communication, he confirms my statement that at the time I told him the growth was found to be a carcinoma.

Remarks.—It is noticeable that in these three specimens the cyst was nearer the periphery than the nipple. The history given in all was a short one. In none was there a second cyst, either large or small. In Case 1 the cystic appearance of the secondary deposits in the brain is of interest in connection with the early cystic stage of the primary formation. In all the cases the fluid was not that of degeneration; it was in two amber-coloured, and in one dark, but thin. In the third case the nodule of growth was very small, and I have no doubt that the suspicious nodule in the second case was also carcinomatous. In Case 2 the recurrence in a cystic form, after complete extirpation, together with the surrounding tissue, is specially worthy of notice. I have no doubt a part of the original growth was left as I worked close to the cyst wall. In contrast with what we find in the simple cysts, it may be noted that the refilling of the cavity in the second case was unusually rapid. This is perhaps a feature of some importance. As to the mode of formation of these cysts I have no definite view, for the specimens gave no special information as to whether the cyst or the growth was primary. On this point I may repeat that in all three cases the tumour was some distance from the nipple. In the brain such a cyst is described by Wilks and Moxon of the size of a small apple, having a carcinomatous nodule in its wall; and the same authors, speaking of mammary tumours, say that "in a few cases cancer has been found associated with a great cyst, the cancer forming only a patch on one side of it."

Though early removal in all these cases would have been the best possible treatment, it would hardly justify us in recommending such a procedure in all cases of solitary cysts, since we know the great majority are of a simple character. The converse, however, seems more true, viz. that there is even less necessity for removing the breast in cases of multiple cysts. So I would conclude that whereas solitary cysts demand careful watching, and must be regarded with suspicion, my experience of multiple cysts of large size leads me to view them with less anxiety. *February 4th*, 1896.

15. *Carcinomatous cyst of the breast.* (*Card specimen.*)

By W. S. Sprent (per J. H. Targett, M.S.).

Mrs. C—, aged 67 years, a temperate woman in comfortable circumstances, noticed pains in her *left* breast ten weeks before she came under treatment, but only complained of them to her daughter a month previously, as she thought the breast was growing larger. There was a dirty red, grumous discharge from the nipple (which was retracted) for about six weeks. The patient had been under observation at different times during the previous ten years, and as the cardiac region had been frequently examined it was improbable that any large tumour in the left breast would have passed unnoticed. Three years previously the patient had a delusion, following upon a severe attack of influenza, that she had been to a hospital and had the left breast removed for cancer. The breast was therefore carefully examined at that time, but found to be healthy, and her friends had never noticed anything wrong about her until the onset of the present illness. There were no enlarged axillary glands. The whole breast was freely removed by operation, and though part of the flaps sloughed the patient ultimately made a good recovery.

Seven months after the removal of the breast, a swelling appeared in the corresponding axilla, and rapidly enlarged. It was excised, and the remaining lymphatic glands were cleared away. The tumour proved to be a very soft hæmorrhagic growth, breaking down into cysts; but there was no colloid degeneration in it.

Description of specimen.—A portion of a breast, the substance of which is largely replaced by fat. It shows a thin-walled cyst the size of a pullet's egg, which is situated towards the deep surface of the gland, and at some distance from the retracted nipple. The inner surface of the cyst is uneven from the projection of ridges and low rounded nodules. Except at one spot the lining of the cyst is smooth. There is no intra-cystic papillomatous growth. At the upper end of the preparation the wall of the cyst merges into a dense mass of apparently glandular tissue, which on section exudes a colloid substance. Histologically the wall of the cyst is composed of fibrous tissue arranged in layers, and has no definite lining membrane. In the outermost part of the cyst wall

there is an abundance of carcinomatous growth; many of the alveoli are large and rounded, and their epithelial contents have undergone colloid degeneration. Some of the smaller alveoli are so situated as to be almost flush with the inner surface of the cyst. Hence there can be little doubt in this case that the cystic change is a secondary condition, due to extensive softening and degeneration in the larger alveoli of the tumour, and subsequent coalescence of these cystic alveoli into one common cavity.

February 4th, 1896.

---

16. *Carcinomatous cysts of the breast.*

By Cecil F. Beadles.

In former communications which are published in these 'Transactions' I have called attention to the frequent existence of cystic degeneration in mammary glands that contain cancer, apart from the actual malignant growth. I referred also to cystic spaces, usually of small and microscopic size, that were surrounded by an irregular thickening of proliferated epithelium, the cells most often of a uniform size and character, and presenting no malignant aspect. But this was not always so; at times there was irregularity in shape, size, and staining power of the individual cells and their nuclei, presenting appearances that I ventured to think were the transitional stages between simple hyperplasia and malignant overgrowth. These cystic spaces, which occasionally reached a fair macroscopical dimension, were either portions of distended ducts or greatly dilated acini.

The present matter is, however, connected only with the presence of cysts of some size (macroscopical) in the actual cancerous tumour, or a tumour of the breast which is formed by a single cyst, whose wall is formed by a malignant heaping up of epithelium, or in whose wall or neighbourhood there is a deposit of glandular carcinoma. But the condition above described in the breast tissue is not wholly unassociated with this latter condition, and may help to explain the origin of these forms of cystic carcinomatous growths.

It is possible that an original, more or less general, cystic condition of the breast may give way to the expansion of a single cyst associated with malignancy that had commenced by a simple over-development of the epithelial lining from some irritant, the accumulation of secretion following with the general expansion of the walls of the duct or acinus.

On the other hand, there appears to me no argument against the view that in other cases there has been a simple, non-malignant cyst in the breast, single or otherwise, and more or less suddenly for some reason, perhaps an injury or the action of an irritant in the secretion, part of the epithelium lining its wall or lying in its vicinity has taken an active proliferation, passing on into the stage of malignancy.

Without taking into account cavities formed in the substance of a new growth from the breaking down of a portion of the new formation, spaces formed by colloid degeneration, or resulting from the extravasation of blood into its interior, we have actual cysts lined by an epithelium not rarely developed as a part of the actual growth. As a rule they are then of comparatively small size, and seldom exceed half an inch in diameter. Occasionally they are numerous and interspersed about the tumour; the cancer is then usually of a soft, glandular, or encephaloid nature, with large cell-masses intermingled with small microscopic cysts. When the growth is more scirrhous in character, cysts are rarer and less numerous; it is in association with a scirrhous mass that large solitary cysts are most often found.

The following is a marked example of the former:—The patient was a married woman, aged forty-five, who had had thirteen children and four miscarriages. No family history of cancer. Only seven of the children took the left breast. Had an abscess twenty-seven years ago with her first child. This was lanced and left a little "nut" underneath, which was always painful when she had other children; it was situated below and to the inner side of the nipple. Six months ago the present tumour appeared as a little hard mass which grew slowly up to six weeks ago, since which time it has increased rapidly in size. It came to the outer side of the nipple, and grew outwards and upwards. There has been some pain under the arm. A sanguineous discharge has existed from the nipple during the last four weeks, which causes smarting of the skin.

A hard mass occupies the outer half of the left breast; it is the

size of an orange, and is not fixed to the skin. Glands in the axilla cannot be felt. The breast was removed by operation, and the axilla was cleared out.

On making a section through the breast the appearance presented is typically that of what I may call a cystic carcinoma. A soft glandular carcinoma, with large rounded areas of malignant deposit, separated by intervening bands of connective tissue, so as to give the general appearance of a gland lobule, and throughout the growth are small macroscopic cysts, from which mucus or blood-stained fluid escaped; while from others a firmer and more caseous material could be expressed.

Microscopically the whole growth is made up of large, distended, alveolar spaces, some rounded, others irregular in outline; some entirely filled by epithelial cells, others containing a granular, amorphous mass in their interior, while in the larger cavities it either does not exist or has fallen out. The cells present that peculiar appearance so often seen in this type of cancerous growth, being formed into bands of compressed cells by the pressure exerted by groups of other cells that are pale and swollen, and lie amongst them. The wall of some of these spaces is half a dozen cells in thickness, often more, but seldom less.

The edge of the growth and the breast beyond shows clearly how the larger masses and cystic spaces have originated, and forms an excellent illustration of the development of cancer from the gland acini of the breast.

The following is an uncommon variety of breast tumour, in which the cell-masses largely take the form of small microscopic cysts, few of which are visible to the naked eye:—A married woman, aged 39, with two children whom she nursed. No family history of cancer. Twelve months ago she had a blow on the breast, and a tumour had been noticed for two months. A mass in the axilla she had observed five months. Slight pain only during the last six weeks. There was a hard, firm mass in the upper half of left breast. Skin freely moveable over it. Enlarged glands in axilla. The breast was amputated, and the axilla cleared out. Two years and four months later there had been no recurrence.

The growth is an unusual and interesting one. The tumour is almost entirely composed of exceptionally large, rounded spaces, which when examined under a low power of the microscope are seen to be lined internally by a thickened layer of epithelium many

cells deep (a dozen or more), the cells having at the same time a fairly uniform size and appearance, with a round nucleus. In the interior of the space in some—in others it may have fallen out—there is a colourless, amorphous mass, apparently composed of coagulated secretion, with no trace of cell-form in it. Although the larger part of the growth is made up of these cystic-like spaces, there are other alveoli interspersed amongst them, which often reach a large size where the cavity is entirely filled with the proliferated epithelium of similar form. Only in a very few places was there seen the ordinary invading character of carcinoma which proved its more malignant character.

Convincing proof of malignancy is found in the diseased lymphatic glands, where for the most part the epithelial masses assume the general form of carcinoma with irregular alveoli, and the individual cells larger and unsymmetrical; but the cystic condition is to some extent present.

As an instance of a large solitary cyst associated with a scirrhous deposit we have this specimen from the museum of the Cancer Hospital, which I mounted and have to thank Dr. Snow for allowing me to exhibit:—From a woman aged 60, who had had no child or miscarriage. No family history of cancer. Never had an abscess in breast, but believes she had a blow four years ago. There was a tumour the size of a pigeon's egg when she first noticed it four years ago, situated at the inner part of breast, which has since gradually increased in size, and has been accompanied by occasional shooting pains.

On admission.—A mass the size of a cocoa-nut occupies the left breast, and the skin is tense over it. There are areas of fluctuation, and some of these stand out a little more prominently from the general surface of the tumour. Nipple is displaced upwards and outwards. There are no enlarged glands to be felt in axilla, but some thickening leading up to that region. Patient is somewhat emaciated, the right breast atrophied. Breast was amputated and axilla cleared out, when some glands were found enlarged. She recovered, and left the hospital in nineteen days, but nothing has been heard of her since.

On making a section into the tumour it was seen to be formed of one large cyst containing sanguineous colloid fluid and blood-clot, the wall being of a deep brown colour. At the upper and inner part, beneath and connected with the nipple, was a hard, solid

white mass of growth which projected into the cyst cavity. This growth had evidently obliterated all means of exit of fluid from the nipple.

Microscopically this growth presents the ordinary appearance of cancer of the breast with rather small alveolar spaces. The cyst wall is seen to be formed of dense fibrous tissue an eighth of an inch or more in thickness. In this tissue are numerous spindle and elongated brown pigmented cells, with scattered groups of round cells also containing brown colouring matter. In other parts the wall seems more or less honeycombed by small cavities filled with brown colloid-like fluid, and in the rest of the breast tissue there are a number of small cysts, apparently dilated lymphatic channels. An interesting point in this specimen is the presence of a number of small, raised, whitish nodules, little larger than pin-heads, on the inner surface of the wall of the cyst. These proved to be minute foci of cancer, with the usual epithelial cell-masses arranged in alveolar spaces. Seeing that there is no sign of an internal epithelial lining to the cyst, and that no gland acini are anywhere near, I make the suggestion that these small masses may have arisen by auto-infection from malignant cells detached from the large mass of cancer above.

The next specimen is of interest on account of the variable nature of the epithelial elements present, and although it has the general appearance of a cysto-sarcoma I am inclined to look upon it as a form of carcinoma:—From a married woman aged sixty-three, who had four children; the youngest was twenty-two years of age. No family history of cancer. She first noticed a small nodule in the breast twenty-one years previously, and, as it gradually increased in size, she thought of having it removed some years ago, but was advised not. Lately it has grown rapidly, and is painful. There is a large cystic tumour, the size of a cocoa-nut, occupying the whole of the right breast, freely moveable; skin nodulated and brawny. Nipple retracted. Glands in axilla enlarged and numerous. Breast removed and axilla cleared. One gland the size of a small plum and several others enlarged; they were soft, but unfortunately were not examined with the microscope. Owing to the extent of removal the edges did not meet, and the wound had to granulate from the bottom. The patient did well, and was discharged in six weeks.

The breast was a mass of cysts which contained a fluid of a

brownish colour and gelatinous nature; the cysts extended completely under the mamma, and were divided into parts and saccules by a number of septa, some being separated only by very narrow bands, while others had thick masses of hard white growth between them which had a malignant aspect; in this firm tissue were a few small cysts, with occasionally a small intra-cystic growth therein.

Apart from the rest of this cystic tumour, and lying on the outskirts of the mass removed, was a round hard mass, size of a walnut, which proved to be composed of dense fibrous tissue, with here and there a trace of degenerated glandular elements,—in fact, a distinct adeno-fibroma.

Microscopically the specimen is of an exceedingly interesting nature. It does not present the appearance of a simple cystosarcoma, as from its naked-eye characters and history one might be led to surmise; but it is of a complicated nature, in which the epithelial or carcinomatous elements largely predominate. In a series of drawings of sections taken from various parts of the tumour, from the thin-walled septa, and the dense scirrhus-like masses which occur in places, we have represented some of the appearances that are to be seen. In places we have the surface covered by a single layer, or one or two thicknesses of large distorted cells, or we have small fringes covered by a greatly multiplied mass of more or less well-formed epithelial cells. Other parts again have single or multiple layers of columnar-shaped epithelium resembling adenoid cancer. Again, in the more solid parts there is a definite alveolar arrangement, and spaces exist which are either entirely filled or lined by a variable thickness of irregular cancer-cells.

The stroma is for the most part degenerated, often mucoid; in places it is more embryonic, but to me does not seem so prominent a feature as the epithelium. It may be that the disease was originally a cystic degeneration of the breast, then a connective-tissue growth supervened, followed by a carcinomatous or malignant change in the epithelium. *February 4th*, 1896.

17. *Carcinoma of the mamma associated with a large cyst.* (*Card specimen.*)

By H. D. Rolleston, M.D.

This specimen was removed from a woman aged 50 years, in St. George's Hospital, by Mr. Bennett, by whose kind permission I am enabled to show it. A year before admission she had received a blow on the right breast, and four months later she first noticed the breast to be swollen. Five months later she noticed that the skin over the swelling appeared red and inflamed.

On admission the skin over the inner and lower part of the right breast was red and adherent to a tumour, in which fluctuation could be obtained. The nipple was quite free, and was situated quite an inch from the tumour. No enlarged glands were felt in the axilla. The skin and the whole of the breast, together with the tumour, were freely removed. Part of the pectoral muscle, being adherent to the tumour, was removed. The nipple was quite normal, and the greater part of the breast tissue, with the exception of a few minute cysts, appeared healthy. Continuous with the inner and lower part of the mamma there was a cyst the size of an orange containing clear fluid. The wall of the cyst was adherent to the skin anteriorly, and in this situation was composed of fibrous and organising granulation tissue. This part of the wall of the cyst was free from any carcinomatous infiltration, and did not show any gland-tubes, so that there is no evidence that the cyst arose in a fibro-adenoma. Tracing the wall of the cyst round towards its deeper attachments it is seen that it gradually thickens, reaching its maximum where it is adherent to the pectoral muscle. Microscopic sections through the cyst-wall where it is increasing in thickness show an infiltration with spheroidal-celled carcinoma. The structure of the thickest part of the cyst-wall shows spheroidal-celled carcinoma, which, from the presence of fatty degeneration of the cells, is presumably of older date than the less thickened portion just referred to. The inner surface of the cyst-wall in this situation is irregular and fenestrated, so as to resemble the interior of a chronically inflamed bursa, while it is comparatively smooth under the skin where no carcinomatous infiltration has taken place.

From the structure of the cyst-wall, innocent in one part, carcino-

matous in another, it appears probable that the carcinoma has developed close to the cyst, along the walls of which it was in process of spreading. In addition, the clear contents of the cyst show that it is not due to softening down of the growth. The cyst does not appear to have had its origin in a fibro-adenoma, and the absence of blood-pigment both from the walls and contents is against the view that it was the result of extravasation of blood at the time of the injury. It is probable, then, that the cyst was a simple one, and that the invasion of carcinoma rendered it more manifest, and possibly led to some increase in its dimensions.

May 19th, 1896.

---

18. *Cystic disease of both breasts, with scirrhous carcinoma in the right breast.*

By H. Betham Robinson, M.S.

History.—E. C—, a married woman aged 49, came under my care at St. Thomas's Hospital on August 6th, 1894, with cystic disease of both breasts. She had had six children, and had had at no time any trouble with her nipples or breasts. No family history of carcinoma. In April the enlargement of her breasts had first been taken notice of. During the last month she had thought she felt a lump in the right breast. There had been no pain in either breast, and no discharge from the nipples.

On examining the right breast the nipple was a good deal retracted (this had not developed apparently in relation with the disease). The whole of the gland was uniformly enlarged and indurated, and with a very well-defined edge. Around the nipple were several very hard nodules, but without any evidence of fluctuation in them. The skin was quite free over the breast, and the gland itself was quite free of the deep tissues. There was some fulness in the right axilla, but no definite hard glands could be detected.

The left breast presented much the same features. There were several firm lumps to be felt, and the whole gland was freely moveable, but it was not quite so large as the right one. The right breast was amputated on August 20th. It was freely removed with

the skin, and the axilla was cleared out. The wound healed by first intention.

The breast, on section, showed that it had undergone a generalised change. There was a fibrotic condition through the whole breast, the connective tissue being white and glistening, but the section did not cup. It was riddled throughout with cysts varying in size from that of a Tangerine orange to those of microscopic size. These contained the greenish-brown mucoid fluid usually met with. Many of the cysts were on the deep surface, forming there definite bosses. They were quite smooth-walled, and in none of them were there any intra-cystic growths. The glands on section were quite soft, and showed no evidence of any growth.

Histologically the breast shows the changes characteristic of chronic interstitial mastitis. The remnants of gland tissue are widely separated by an extensive development of fibrous tissue; the latter in the neighbourhood of the gland tissue is much firmer, and the connective-tissue bundles are arranged circularly round the acini, developing especially, to start with, from the basement membrane of the tubules. The acini in places are almost obliterated, the cells being very small and evidently much compressed, their nuclei staining deeply with hæmatoxylin. In some spots dilatation of the small ducts has taken place, and their epithelium is proliferating. Besides these there are large masses, composed of cells much larger than those before mentioned, rather irregular in shape, and not taking the hæmatoxylin stain so deeply. In some specimens, as in the one under the microscope this evening, there is definite evidence of a scirrhous growth in addition. The fibres of connective tissue are arranged in parallel bundles, and cells, evidently carcinomatous in nature, are to be seen running between them in rows.

During October the left breast distinctly increased in size, and she was advised to have this removed. In the middle of November, when she next presented herself, it had further increased, and a gland in the left axilla was to be felt. After strong persuasion she consented to have this breast removed, and so on November 28th she was admitted.

The breast presented the nodulated condition before described, especially in the outer and upper quadrant, but the lumps were softer than in the other breast.

The breast was amputated and the axilla cleared out, but in the latter there was only one gland that seemed at all enlarged.

On section, as on the other side, the breast was studded with cysts varying in size, but none of them showed any intra-cystic growths. Histologically the breast showed the signs of chronic inflammation; no evidence of scirrhous carcinoma. The gland removed was quite healthy.

Since the removal of the breasts the patient has remained quite well.

Remarks.—These specimens are good examples of a generalised cystic disease of the breasts. As in other organs, *e.g.* the kidney, the development of cysts in relation with a diffuse fibroid change is not to be wondered at. Now such an extensive cystic change is certainly unusual in the breast, and this bilateral condition as a clinical form has been accurately described by many observers. Sir Astley Cooper, in his classical monograph 'Illustrations of Diseases of the Breast,' refers to this disease under the name of "cellulous hydatids," and says, "It is an enlargement growing for months or years, the swelling at first feeling solid, developing after a time fluctuating centres. These contain a mucilaginous serous fluid, and the glands are not enlarged. On dissection the breast has chronic inflammation of the connective tissue, with a large number of cysts of varying size distributed through it, with tendency to grouping." He, however, makes the statement that he had never seen the disease present in both breasts at the same time. In France, both Phocas and Reclus have described these cases, and the disease is named after the latter observer. He describes these nodular swellings as occurring more towards the periphery of the gland; König says on the posterior surface, and both are undoubtedly correct. Reclus also states that both breasts are, as a rule, involved, and the cysts develop progressively. They occur in women between forty and fifty, and in only a small proportion is pain complained of. In about 80 per cent. there is some discharge from the nipple. Intra-cystic growths in the large cysts are rare, Reclus having noticed them only once in fourteen cases.

Although we may recognise several clinical forms of cystic disease, from the pathological standpoint, which should be our only guide, classification becomes very simple. Excluding the so-called duct cysts, localised specially to the nipple region and developed from the sinuses, of which many cases have been described by Birkett and Bryant, I believe that every cyst of the breast, which is not especially associated with lactation, develops in relation with some

chronic inflammatory change. The latter may be local or generalised, but in every so-called "single cyst" that I have examined there has been an increase of fibroid tissue with small cysts in the neighbourhood. Whether one cyst or many enlarge is purely a matter of accident.

Another point worthy of note is the presence of carcinoma in relation with this chronic inflammatory change. The two lesions are so common that they may be accidentally associated, but in this case, as in so many others, there appears a causal relation between the two. We know that in most cases of chronic interstitial mastitis, appearances such as the marked proliferation of acinous epithelium, and the distension of the acini, are common features, and it would baffle the most expert histologist to decide between their simple or malignant nature. Any patient with such a condition is practically on the brink of a precipice, a condition which I feel certain is not appreciated and even opposed by many. These cases, whether the development is local or general, should be treated radically; for any measure such as tapping or plugging is worse than useless, and only excites further irritation. It can only be from the æsthetic side that the retention of such diseased organs is defended, while from a practical point of view we must recognise the fact that they are a positive source of danger.

March 3rd, 1896.

---

19. *Hæmorrhagic duct-cancer of the breast.* (*Card specimen.*)

By Rutherford Morrison (per J. H. Targett, M.S.).

The specimen was removed from a married woman aged 39, who was admitted to a hospital with pain and swelling in the left breast. Three years previously she fell from a tram, and the same night felt pain in that breast. A slight discharge of blood from the nipple was seen, and this has been present more or less ever since. Three months ago the patient felt a small lump in the breast, but it was not then painful. On admission there was a

firm, semi-elastic tumour immediately beneath the left nipple; it was about an inch and a half in diameter, and had ill-defined edges. It was attached to the substance of the nipple, but the skin over the tumour was not adherent. There was much bloody fluid discharged from the nipple. The axillary glands were enlarged. The breast and the whole of the axillary glands were removed by operation. These glands were much enlarged and infiltrated with secondary deposits, but were not examined microscopically.

The growth in the breast proves to be a duct-carcinoma, and is remarkable for the extreme engorgement of its capillaries and the extravasation of blood into the stroma.

The tubular structure of the epithelial growth is fairly well seen, but is to some extent modified by the extraordinary dilatation of capillary vessels which run in the delicate stroma surrounding the tubes, or forming the core of papillary processes of growth. Indeed, so abundant is the blood in some portions of the tumour that the tissue has an alveolar appearance, the alveoli being filled with blood-corpuscles, and the walls formed of distorted epithelial cells which represent the original tubules flattened out by pressure. Probably much of this blood is in reality extravasated into the loose cellular tissue around the engorged capillaries, the outlines of which are easily discerned. Two results would appear to have followed from this engorgement and extravasation: firstly, the flattening of the epithelial tubules as described; and secondly, large tracts of the growth have undergone necrotic changes, so that they would not stain. The latter change may be due to interference with the blood-supply by extravasation into adjacent areas. The vascularity of duct-cancers of the breast is well known, and the specimen here described indicates very well the mode in which such growths may sometimes be converted into blood-cysts, and so lose their malignant characters, or at least be mistaken for blood-cysts of a simple type.

March 3rd, 1896.

20. *Malignant tumour from ischio-rectal region of a fox terrier. (Card specimen.)*

By C. S. Wallace.

Tumour was first noticed in the spring of 1889. It was situated to the left side and behind the anus. It was freely moveable over deep and superficial structures. In June, 1890, it was removed under cocaine and shelled out completely; it was lying beside the rectum, but in no way connected with it. When removed it measured 2 inches by 1 inch, its long axis corresponding with the long axis of the rectum. On section it was pinkish-white in colour, and presented well-made lobules. In the autumn of 1893 it again appeared in the same situation, and gradually increased in size until the autumn of 1895, when the dog was killed on account of his age, being thirteen years old.

When examined after death the tumour was found to be unconnected with anything except the scar of the old incision. No secondary growths were present in the body.

Microscopical examination showed the tumour to consist of lobules divided from one another by strands of fibrous tissue. The lobules themselves consisted of branching columns of cells, but without any sign of a lumen. The columns of cells presented a basement membrane of flattened cells whose nuclei were well stained, and on these were situated, in some places, long columnar cells, which interdigitated with one another, and possessed a round nucleus with one or two nucleoli. In other places the cells were of the polyhedral type, and presented the same kind of nuclei.

In various parts of the sections, and nearly always in the connective tissue, were to be seen rounded bodies of a yellow colour, suggesting a horny nature. In a few instances there were indications of a faint circular striation, but in very few of them were there any epithelial cells outside the yellow centre, and these did not resemble the outer layers of cells in the nests of squamous epitheliomata.

Sections of the recurrent tumour showed similar appearances to those of the primary growth, with the exception that the columnar cells were less abundant, and that in some places the cells appeared

to be vacuolated. This specimen was not placed in preservative fluid until three days after death, and then only in alcohol.

Since the dog possesses only sweat-glands on the hairless parts of its body from which the columnar cells might have arisen, the tumour must be either an adenoma of the glands of the rectum or a sacro-coccygeal tumour, from both of which it differs in showing no tubules with lumina. The sebaceous glands of the dog resemble human sebaceous glands, and would therefore be unable to give rise to a growth containing columnar cells. *March 3rd*, 1896.

---

21. *On sarcomata of the bladder and their classification.*

By J. H. Targett, M.S.

[With Plates V, X, and XI.]

During the last thirty years several examples of sarcoma of the bladder have been brought before this Society, and the subject has received fuller attention at the hands of Barling,[1] D'Arcy Power,[2] Fenwick,[3] and Southam.[4] It is not my intention to traverse the same ground as these writers, or at least not in the same way; but I propose to describe the specimens of vesical sarcoma which I have had the opportunity of examining, with the view of introducing an anatomical method of classification for the diverse growths which are included under the heading of sarcoma of the bladder.[5]

Several methods of classification have been already adopted. It is generally agreed that sarcoma of the bladder occurs most frequently in childhood and after middle life. Thus cases may be divided clinically into those occurring before the age of ten years, and those after the age of forty years. It is also agreed that there are considerable differences in the macroscopical characters of the tumours at these two ages, so that this classification by age has both a clinical and a pathological value.

[1] 'Birmingham Med. Rev.,' 1838, vol. xxiii, p. 193; 1892, vol. xxxii, p. 65.

[2] 'Trans. Path. Soc.,' 1888, vol. xxxix, p. 172.

[3] Ibid., p. 171.

[4] 'Med. Chron.,' 1888, vol. viii, p. 177; 1889, vol. x, p. 119.

[5] The various specimens described in this paper were exhibited at the meeting of the Society, chiefly as lantern plates from photographs.

Classification according to the shape or arrangement of the cells of the sarcoma is a well-recognised method, and is adopted by Barling (loc. cit.). Further, it is easy to separate the growths into three classes, which may be broadly distinguished as (1) primary sarcomata of the bladder; (2) sarcomata which have extended into the bladder from adjacent viscera or tissues; (3) secondary or metastatic sarcomata. By combining the first and last of these methods we can speak of sarcomata of the bladder in adults (over forty years of age) as being either primary, or by extension, or metastatic; and similarly with those occurring in childhood.

We will proceed to consider those met with in adults first, and take them in the inverse order of frequency.

1. *Metastatic sarcomata of the bladder.*—Under this subdivision I have but one specimen to exhibit. It consists of a soft pigmented polypus attached by a slender pedicle to the mucous coat of the posterior wall, and is histologically a melanotic sarcoma. The primary disease was in the eye.[1]

A doubtful case of sarcoma of the bladder secondary to the left kidney is recorded by Dr. Penrose.[2] The left kidney was wholly replaced by a large round-celled sarcoma weighing over 6 lbs. A little above the internal meatus of the urethra there was a somewhat pedunculated villous growth, which was regarded as a secondary deposit of sarcoma induced by direct implantation from the kidney. The microscopical examination was not conclusive, and the vesical tumour might have been only a simple papilloma associated with sarcoma of the kidney. But a loose mass of degenerated sarcomatous tissue was found in the bladder, and the patient had passed a spirally twisted, vermiform clot composed of sarcomatous cells and coagulum. The possibility of metastasis by direct implantation must be admitted, but was not conclusively demonstrated in this case.

2. *Sarcomata of the bladder by extension from adjacent viscera and tissues.*—The viscus which is most frequently the primary seat of the disease is certainly the prostate; but the remaining viscera in the male, or those of the female pelvis may occasionally exhibit the original focus. The consideration of the tissues other than those of the pelvic viscera may be deferred for the moment.

Primary sarcoma of the prostate is not a common affection in the

[1] 'Trans. Path. Soc.,' 1891, vol. xlii, p. 214.

[2] Ibid., 1893, vol. xliv, p. 96.

adult, but most museums possess specimens of the disease in children, and in them we find that in addition to a large gelatinous tumour replacing the prostate there are deposits of the growth beneath the mucous coat of the bladder, which generally assume the polypoid form. This specimen (4360A, R.C.S. Mus.[1]) is an example of a large myxosarcoma of the prostate from a man aged fifty-three, but there is no actual protrusion into the cavity of the bladder.

A good example of sarcoma of the prostate invading the bladder is preserved in St. Bartholomew's Hospital Museum (No. 2854A). It shows a large soft growth replacing the prostate and projecting into the cavity of the bladder in the form of pedunculated growths of varying size. Histologically the growth is a sarcoma composed of round and spindle-shaped cells. The patient was a man aged twenty-one, who was admitted for retention of urine. He died three weeks later, after much hæmaturia. The autopsy showed marked dilatation of the ureters and suppurative nephritis, but no secondary deposits were found.[2]

Primary sarcoma of the vagina in adults is a very rare affection. Dr. William Gow[3] carefully searched the literature of the subject, but was able to collect only thirteen cases, and in none of them was there any statement to the effect that the bladder was involved. But a *post-mortem* examination was made in only two of these cases, hence the frequency of extension into the bladder cannot be estimated. In children, however, we have more anatomical evidence to work upon, and the subject will be dealt with later.

It is unnecessary to refer to primary sarcoma of the uterus and rectum in detail. When the growth has passed beyond the limits of either viscus it may extend into the wall of the bladder, but I have no specimens to bring forward illustrating these conditions. One example of sarcoma extending into the bladder by way of the ureter must be mentioned.[4] A round-celled sarcoma starting in the neighbourhood of the right kidney penetrated the upper end of the corresponding ureter, and gradually spread down that channel until it reached the bladder. On laying open the bladder (3706A,

[1] See 'Trans. Path. Soc.,' 1887, vol. xxxviii, p. 195, whree the growth is wrongly described as encephaloid carcinoma.

[2] 'Trans. Path. Soc.,' vol. xxxiv, p. 145.

[3] 'St. Barth.'s Hosp. Reps.,' 1891, vol. xxvii, p. 97.

'Trans. Path. Soc.,' 189 vol. xliii, p. 92

R.C.S. Mus.) a polypoid tumour the size of a large cherry was found to project from the mouth of the right ureter into the cavity of the bladder. The pedicle of the tumour was covered with healthy mucous membrane, but at its summit (which included the actual orifice of the ureter) the surface was ulcerated (Fig. 19). In a

FIG. 19.

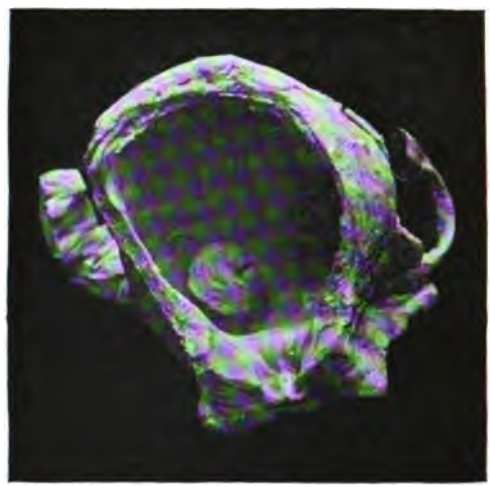

remarkable case recorded by Dr. Bastian,[1] the malignant growth invaded the ureter from its vesical extremity, and spread upwards in the walls of the canal as far as the pelvis of the kidney. From the description of the growth in the bladder it was probably a soft sarcoma. The two cases are of interest as showing the invasion of the entire length of a ureter by sarcoma commencing at one or other end of the tube.

3. *Primary sarcomata of the bladder.*—These growths in the adult may be advantageously divided into two classes. In one class an intra-vesical tumour is formed, while in the other the disease is mainly outside the wall of the bladder, and may be termed "pericystic." Before describing the specimens which illustrate these subdivisions a word or two may be said as to the frequency of primary sarcomata of the bladder. In the various London museums there are more than 200 specimens of solid tumours of

[1] 'Trans. Path. Soc.,' 1867, vol. xviii, p. 159.

the bladder which are primary in origin. Of these rather more than one half are primary carcinomata of various kinds, while barely one tenth are primary sarcomata; in other words, carcinoma is five times more common than sarcoma in the adult. In making this calculation all examples of sarcomata in childhood have been excluded because of the differences in their pathology and effects. As this proportion differs considerably from that given by Prof. Albarran, in his monograph on 'Tumours of the Bladder,' it may be pointed out that in the largest individual collection in London (which is preserved in Guy's Hospital Museum) the above proportion obtains. Thus out of thirty-six primary growths, all of which I have examined with the microscope, there are twenty-two carcinomata and four sarcomata in adults. Albarran only met with two examples of sarcoma among eighty-nine vesical tumours which he himself had examined with the microscope, but it is probable that a very large number of these were papillomata removed by operation.

A. The naked features of the first variety of primary sarcoma mentioned above are those of a solid sessile tumour, originating in the submucous tissue and projecting into the cavity of the bladder. It is usually situated in the inferior zone of the bladder, behind or to one side of the trigone, or less frequently upon the trigone; it may involve the orifices of the ureters, and may also tend to grow towards the neck of the bladder. The outline of the tumour is lobulated, and its surface smooth from the covering of mucous membrane which it bears. If ulceration has occurred, the summit of the tumour will be frayed or shaggy from maceration. On section it usually presents a soft, somewhat spongy structure. Though at first limited to the submucous tissue, the growth eventually infiltrates the muscular coat and forms nodular masses beneath the serous membrane. Mr. Southam[1] records a case in which perforation of the bladder and fatal peritonitis resulted from sloughing and ulceration of the growth.

The following preparations are excellent examples of the variety of primary sarcoma now under consideration. This one was brought before the Society in 1883 by Mr. Clutton,[2] and there is perhaps some doubt as to its being a primary growth. The case is always included in the statistics of metastatic sarcomata of the bladder. But the reasons for this classification are to my mind not very con-

[1] 'Med. Chron.,' 1888, vol. viii, p. 177.

[2] 'Trans. Path. Soc.,' 1883, vol. xxxiv, p. 212.

vincing. The autopsy revealed only two growths; one of these was in the scalp and had penetrated the skull, the other in the urinary bladder. The former consisted of large spindle-shaped and giant-cells, the latter of round and oval cells. The vesical tumour was called secondary because it gave rise to no symptoms during life, and was much more cellular in structure than the cranial deposit. I venture to think that the case should be read reversely, and therefore I have included this vesical tumour with the primary sarcomata of the bladder.

The next specimen is from St. Bartholomew's Museum (No. 2428), and consists of a female bladder opened in front to exhibit a large growth on the trigone, base, and posterior wall. Its surface is coarsely lobulated and covered with mucous membrane. A vertical section through the specimen reveals a spongy new growth, nearly 1½ inches in thickness, which has raised up the mucous coat from the wall of the bladder, carrying with it the orifices of the ureters. The muscular coat can be distinguished at the base of the tumour, where the growth has extended through it and infiltrated the anterior aspect of the cervix uteri. Both ureters are moderately dilated, the bladder is hypertrophied, and its cavity is much reduced in size by this intra-vesical tumour. Histologically the growth is a round-celled sarcoma.

The third preparation (Plate X, fig. F) exhibits a large, lobulated, sessile sarcoma, which projects into the cavity of the bladder and has the following relations. Occupying the greater part of the vesical cavity is a firm spheroidal tumour, which measures about 4½ inches from above downwards and 3 inches from side to side. The exposed surface of the tumour is coarsely nodulated, and where it has been in constant contact with the bladder wall it is quite smooth. But the right side of the tumour and its lower extremity, which extends into the prostatic urethra, are ragged from ulceration—probably the result of exposure to the urine. On turning back the vesical wall it is found that the mucous membrane around the attachment of the growth is healthy, and that the impressions on the surface of the tumour are produced by the pressure of the hypertrophied muscular coat when firmly contracted upon the upper end and left side of the tumour. In consequence the surface was not exposed here to maceration by the urine. As regards the area of attachment of the tumour, the whole of the trigone (except the orifice of the right ureter, which is normal), the posterior and

left lateral walls, the neck of the bladder, and the prostatic urethra as far as the verumontanum are involved—an area which measures about 3 inches in diameter, and is less than that of the tumour itself, owing to the superior and left margins of the tumour overhanging considerably the seat of attachment.

The cut surface of the tumour has a somewhat translucent appearance, marked with patches and lines of opaque yellowish material. Towards the base there are several spaces apparently due to softening of the growth, and the subjacent wall of the bladder is invaded. Where the edge of the tumour overhangs the wall the mucous membrane is traceable upon the tumour for a short distance. On the reverse of the preparation the end of the left ureter is displayed. It is much dilated, and its lumen is entirely blocked by an extension of the growth along it. The vasa deferentia, vesiculæ seminales, and right ureter are normal.

The only history that has been preserved of this specimen states that it was removed from an old man in whom signs of the growth had long existed. A very hard tumour formed in the situation of the deep iliac glands some weeks before death. A section of the growth has been placed under the microscope, in which it will be seen that the minute structure of the neoplasm is peculiar.

The specimen has been long preserved in the museum, and therefore is not in a satisfactory state for histological purposes. But this much can be made out: that the growth is a sarcoma composed of interlacing bundles of small spindle-cells; that certain parts of the tissue have undergone a hyaline change, so that narrow rows of nuclei are seen embedded in an abundant hyaline matrix, and that one or two well-defined nodules having the appearance of cartilage are present in the most cellular parts of the tumour. Hence it may be concluded that the growth is a sarcoma undergoing chondrification. Here and there concentric bodies like the corpora amylacea of the prostate are seen.

B. The second variety, or pericystic sarcoma, is the form to which I wish to draw special attention. The growth begins in the connective tissue outside the muscular coat, beneath or perhaps in the sheath of recto-vesical fascia. Hence it extends more or less round the organ, forming a thick coating of growth, and also infiltrates the muscular tissue, ultimately producing nodules of various sizes beneath the mucous membrane. In such cases extension to the lymphatic glands along the iliac vessels and to the adjacent viscera

will take place, and true secondary deposits may occur in the lungs and other organs. A good example of this form of sarcoma is represented in Plate X, fig. E. The preparation consists of the male pelvic viscera divided in the median plane. The uppermost cavity is that of the bladder, which is almost embedded in an enormous mass of sarcoma. The rectum is free, as well as the recto-vesical pouch of peritoneum, but beneath the serous covering of the bladder, and outside the pelvic peritoneum along the iliac vessels there are large masses of new growth. In the muscular coat of the organ whitish nodules of varying size may be seen, some of which form small rounded elevations within the bladder, but are smoothly covered with mucous membrane. The prostate is but partially recognisable, as its outer surface is blended with that portion of the growth which extends up in front of the bladder. This specimen was removed from a man aged twenty-seven, who was admitted to Guy's Hospital for weakness of the legs, partial intestinal obstruction, and thrombosis of the iliac veins. A growth was felt in the pelvic cavity, which was at first limited to that region, but subsequently it extended upwards to a distance of 3 inches above the pubes. Two months before death the first urinary symptom supervened, viz. incontinence of urine. At the autopsy secondary deposits were found in the skull, lungs, and liver. The rectum was compressed though not invaded by the pelvic growth, and the kidneys were in a state of advanced suppuration. The bladder was so embedded in the growth that it formed a cavity the size of a hen's egg, with rigid walls. None of the pelvic bones were invaded, but the sacral plexus was compressed. Microscopically the growth proved to be a soft round-celled sarcoma, and from its anatomical distribution there can be little doubt that it began in the pericystic cellular tissue.

Another specimen (3704, R.C.S. Mus.) presents very similar appearances. It consists of a female bladder opened in front. The greater part of its wall has been replaced by a soft round-celled sarcoma which forms a somewhat oval tumour, measuring 5 inches in its chief diameter. On looking into the bladder healthy mucous membrane is seen upon the left lateral wall, extending forwards to the middle line. The whole of the base, the posterior and right lateral wall (including the apex) are covered with nodular projections and ridges of growth. Many of these have a smooth covering of normal mucous membrane, while some are superficially

ulcerated or are fungating into the vesical cavity. Turning to the substance of the bladder, it will be observed that the right wall and apex consist of a mass of new growth fully 2 inches in thickness, which on section shows a soft white tissue bounded internally by the mucous membrane, and adherent externally to the anterior abdominal wall and the pelvic fascia. It appears to be traversed by a few strands of fibres which are probably the remnants of the muscular coat. On the right side of the specimen a window has been cut in the thickened pelvic fascia to display the extension of the growth from the bladder to the adjacent tissues. A part of the adherent abdominal wall has been detached from the front of the bladder and turned upwards. Its deep surface is infiltrated with growth. The left vesical wall is the least affected, but the growth has already extended into it from behind, where it forms a lenticular mass about one inch thick. On the reverse of the preparation the uterus and vagina are seen to be much compressed by the tumour, but not invaded. The peritoneum of the utero-vesical pouch is normal, but on the posterior surface of the bladder the serous membrane is raised by a subjacent lobulated deposit of growth. A section of this surface has been reflected to display the spongy structure of the neoplasm. The right ureter passed through the whole thickness of the growth, and emerged upon a rounded nodule of growth at the trigone. The length of this passage through the tumour was nearly 3¼ inches, and it was remarkable that in spite of this long distance through a soft growth an ordinary probe was passed through it without difficulty. It may be concluded that there was little or no obstruction to the exit of urine, especially as the canal above the bladder is not dilated; and further that the wall of the ureter resisted invasion by the growth after the manner of large arteries. The left ureter is likewise patent and free, though there is a submucous deposit of growth around its vesical termination.

Lastly, in Plate V, fig. A, is represented the left half of a bladder divided by a median section, together with a portion of the penis. The whole of the vesical wall, except a small piece at the base, is invaded by a firm new growth, uniform in structure. In front it has replaced the anterior wall, and reaches a thickness of 3½ inches; while on the posterior wall the growth forms lobulated masses projecting into the bladder, which are ulcerated on the surface. The left ureter opens into what remains of the vesical cavity at the

base. Histologically the growth is a small round-celled sarcoma. The patient was a man aged sixty-eight.[1] His illness began with pains in the loins. Soon after his urine became thick and tinged with blood. He was several times sounded for stone in the bladder. Death resulted from exhaustion two years after the onset of these symptoms, and both kidneys were found to be dilated. On the external surface of the viscus towards the apex there was a large mass of growth directly continuous with that upon the anterior wall of the bladder. Though the large size of the growth precludes the possibility of determining its exact origin, yet the fact that more than three quarters of the mass which has replaced the anterior wall of the viscus is actually external to the muscular coat, and the small amount of intra-vesical protrusion render it practically certain that the sarcoma began in the cellular tissue outside the muscle coat of the bladder rather than in the submucous tissue. Hence the specimen has been grouped with the pericystic sarcomata.

c. Another supposed variety of sarcoma of the bladder has been described under the title of villous sarcoma. If the term "villous" as here applied merely refers to papillomatous outgrowths from the mucous membrane which covers the sarcoma, then there is no need to make a fresh class for such tumours. The association of papillomata with the sarcoma will in no way influence the natural course of the malignant disease. But unfortunately two other conditions have been included in the term, and thus an important source of error exists. One of these consists of inflammation of a fibro-papilloma, which is mistaken for a villous sarcoma. Owing to the abundant infiltration of the fibrous stroma of these papillary growths with round inflammatory cells they become thickened, and being closely packed they form a firm globular tumour, which differs considerably in its naked-eye features from those of the simple sessile villous growth. Microscopically the cellular infiltration of the pedicle is then regarded as a round-celled sarcoma. A good example of this condition is preserved in Guy's Hospital Museum (No. 2103[5]). The interior of the hypertrophied bladder presents an oval tumour, the size of a hen's egg, attached by a very thick pedicle to the mucous coat a little way above the orifice of the right ureter. The surface of the tumour, where it is not shreddy from ulceration, has the appearance of a cauliflower, and a vertical section

[1] 'Trans. Path. Soc.,' 1885, vol. xxxvi, p. 284.

through the middle of the growth exhibits a stout central stalk bearing thick villous processes, which are so closely packed that the tumour feels quite hard. The resemblance in its coarse structure to the efflorescence above mentioned is thus very close. The preparation has been described[1] and frequently quoted as a "villous sarcoma of the bladder;" but microscopical examination of the pedicle and processes of this tumour has convinced me that it is merely an inflamed fibro-papilloma, and in no sense a malignant neoplasm. One cannot doubt but that similar mistakes have been made. Thus the description of the microscopical structure of the "villous sarcoma," recorded by Mr. Roger Williams,[2] leaves no doubt in my mind that the growth was an inflamed fibro-papilloma, and not sarcomatous at all.

Messrs. Southam and Railton,[3] in speaking of the so-called "transitional" papillomata of Sir Henry Thompson, declare that "the connective-tissue framework of such growths is infiltrated with suspicious-looking cells in greater or less abundance, which in the early stages are not to be distinguished from inflammatory leucocytes." Nevertheless, while admitting that these features are not sufficiently pronounced to place them confidently among the sarcomata, these writers hold that such growths, in some instances at all events, undergo a complete transformation into sarcoma. In proof of this a case is quoted in which a typical fibro-papilloma was removed by operation from the bladder of a man nine months before death. At the autopsy a growth was found in the bladder springing from the site of the original tumour, and this growth had the intimate structure of a sarcoma though still retaining papillomata upon its surface. The opinion as to its nature was further substantiated by the discovery of a small secondary deposit in the sacrum. A very similar case has been recorded by Mr. Shattock.[4] It is beyond the scope of this paper to discuss this point as fully as its importance deserves; but from the examination of a very large number of vesical growths, removed by operation or otherwise, I have come to the conclusion that inflammatory changes in vesical growths are common, and sometimes very extensive; and further, that the so-called transitional papillomata are either inflamed villous

[1] 'Brit. Med. Journ.,' 1889, vol. i, p. 17.
[2] 'Trans. Path. Soc.,' vol. xxxiv, p. 156.
[3] 'Med. Chron.,' 1889, vol. x, p. 119.
[4] 'Trans. Path. Soc.,' 1887, vol. xxxviii, p. 183.

growths on the one hand, or they are simple papillomata springing from the mucous surface of an essentially distinct sarcoma. A third possibility—namely, the secondary invasion of such simple papillomata by the subjacent sarcoma—must be admitted, but I have no evidence to bring forward in support of it.

The term "villous" has likewise been applied to sarcomata and carcinomata of the bladder whose surfaces are shreddy and flocculent from ulceration and maceration of the malignant tissue in the urine, whereby the softer parts of the tumour are washed away and the fibrous stroma becomes exposed. Such a use of the term is most misleading, and should be carefully avoided.

Sarcoma of the bladder in children.—Before proceeding to discuss the classification of these growths it is necessary to premise that under the heading of sarcoma are here included all those polypoid growths attached to the mucous coat of the bladder in children, which are described as mucous polypus, fibro-sarcoma, fibro-myxoma, myxo-sarcoma, and the like. All observers are agreed that the vast majority of primary vesical growths in children are of the polypoid type,—that is, rounded elevations of the mucous coat with more or less constricted pedicles, and arranged in clusters. That their macroscopical characters to some extent vary according to their histology will likewise be admitted. But the point which I wish to maintain is that the minute structure of these formations is of subsidiary importance, that pathologically they are best considered as members of one group, and that clinically they have one common character, viz. that they are uniformly fatal.

In thus grouping the primary connective-tissue growths of the child's bladder it is not intended to imply that they are all equally malignant, or that the fatal issue of the disease is the result of this malignancy. On the contrary, it is well known that death is chiefly, if not entirely, due to urinary obstruction and its backward effects upon the kidneys. And as regards malignancy, evidence may yet be forthcoming that some of these vesical growths are as benign as the simple myxoma of the nose. In attempting to classify the innocent tumours of the bladder, Barling (loc. cit.) admits the difficulty of assigning certain specimens to a definite class. He places the following under the division of innocent tumours: papilloma, fibroma, myxoma, fibro-myxoma, myoma, fibro-myoma, adenoma, and a few other rare growths. Excluding papilloma, fibroma, and pure myoma, none of which have come under my notice in *young*

children, we are left to consider the myxoma, the fibro-myxoma, and the fibro-myoma. Now I very much doubt the existence of any vesical growth in children which is comparable to the simple myxoma of the nose. Myxomatous tissue enters very largely into the constitution of these vesical polypi, and indeed may be regarded as characteristic of them. But that may be attributed to the fact that the polypi are developed from young connective tissue which still possesses some of its embryonic attributes. Sarcomata originating from other young connective tissues present the same features; for example, retro-peritoneal sarcomata in children, in which the existence of much myxomatous tissue in no way detracts from the acknowledged malignancy of this disease. Southam (loc. cit.), in speaking of myxoma and fibro-myxoma of the bladder, remarks that from a consideration of their clinical history and course, and also from the fact that a considerable proportion of the cases have occurred in young subjects, it is probable that they are really examples of sarcoma. The presence of muscle-fibres in some of these vesical tumours admits of no doubt, and will be referred to subsequently. But there is no evidence that these elements in any way modify the essential nature of the tumour in which they take part.

I propose now to bring forward specimens of vesical tumours from children in illustration of the groups above described. If we adopt the same anatomical classification as already used for the sarcomata in adults, it will be necessary to begin with the *metastatic growths*. But there are no examples of this variety in my series.

Extension sarcomata.—The second class consists of growths which have extended into the bladder from adjacent viscera or tissues, and is well represented. Indeed, examples of this variety are to be found in all large museums, and it is therefore unnecessary to make more than a passing reference to them. The viscera which are most frequently the primary seats of the disease are the prostate and vagina.

A good example of the former is here shown (No. 4360c R.C.S. Museum). There is a rounded gelatinous tumour, 3 inches in diameter, attached to the neck of a child's bladder, and a collection of polypi spring from the mucous membrane around the internal meatus of the urethra. The prostatic tumour is a myxo-sarcoma, while the polypi are composed of round and oval cells situated in the submucous tissue, and covered with normal mucous membrane.[1]

[1] 'Trans. Path. Soc.,' 1891, vol. xlii, p. 218.

In the next preparation (No. 2104[32], Guy's Hospital Museum) there is a collection of polypi within the bladder, the largest of which is the size of a walnut, and is attached by a stout round pedicle near the orifice of the right ureter. The neck of the bladder is crowded with similar small polypi, one of which has been forced some distance down the urethral canal. Below the prostatic urethra and the neck of the bladder there is a large solid tumour measuring 3 inches in its chief diameter. It extends backwards to the line of the ureters, and projects downwards as a large oval mass towards the rectum. It has a gelatinous and homogeneous aspect on section, though the central portion has softened and presents a small cavity. Below the left ureter on the outside of the bladder there is a second similar tumour, the size of a filbert nut. No portion of the prostate can be discerned. The growth beneath the bladder is composed of round, oval, and spindle-shaped sarcomatous cells in a homogeneous matrix; it is traversed by many vessels, and has areas of mucoid degeneration in it. The polypi within the bladder are covered with the vesical epithelium, and consist of large round and oval cells in abundance; their bases exhibit strands of well-developed fibrous tissue, with many round and spindle-shaped cells.

Mr. D'Arcy Power, in a paper on "Primary Sarcoma of the Vagina in Children,"[1] has collected a valuable series of twenty-six cases. In at least ten of these the bladder was involved by infiltration of its wall, and in several instances there were polypoid projections of the sarcoma into the cavity of the organ, as described above in connection with the prostate. This was notably the case in the preparation exhibited by Mr. Howard Marsh at this Society in 1874.[2] In the specimen of sarcoma of the vagina described on p. 169 of this volume the cavity and mucous membrane of the bladder are not invaded; but the vesical wall is adherent to the front of the sarcomatous growth, and its infiltration, therefore, was only a question of time.

Primary sarcomata.—In the third group of specimens are included the primary sarcomata of the bladder in children, and they are the most important, both as regards frequency and variability of structure.

The bladder represented in Plate X, fig. c, is of historical interest, inasmuch as it was prepared by John Hunter more than a century

[1] 'St. Barth.'s Hosp. Reps.,' vol. xxxi, p. 121.

[2] 'Trans. Path. Soc.,' vol. xxv, p. 178.

DESCRIPTION OF PLATE X.

Illustrating Mr. Targett's paper on "Sarcomata of the Bladder and their Classification." (Page 291.)

FIG. A.—Polypoid sarcoma of bladder, from an infant aged eighteen months (see p. 306). Preparation in Guy's Hospital Museum.

FIG. B.—Rapidly growing sarcoma of bladder, from a boy aged 3½ years. An enlarged lymphatic gland is attached to the back of the bladder (see p. 307).

FIG. C.—Sarcomatous polypi filling the bladder of a young girl, and protruding from the dilated urethra (see p. 304).

FIG. D.—Sarcomatous polypi springing from the base of the bladder of a boy aged 2 years. There is a secondary deposit at the apex of the organ, the centre of which has become cystic (see p. 305).

FIG. E.—Pericystic sarcoma with extensive invasion of the wall of the bladder, from a man aged 27 years (see p. 298). Preparation in Guy's Hospital Museum.

FIG. F.—Large sessile sarcoma filling the bladder of an old man (see p. 296).

Preparations represented in Figs. B, C, D, and F are preserved in the Museum of the Royal College of Surgeons.

Fig. A.

Fig. B.

Fig. C.

Fig. D.

Fig. E.

Fig. F.

DESCRIPTION OF PLATE XI.

Illustrating Mr. Targett's paper on "Sarcomata of the Bladder and their Classification." (Page 291.)

FIG. A.—Bladder of child everted to show two polypoid sarcomatous growths. The orifices of the ureters are indicated by glass rods (see p. 307).

FIG. B.—Bladder of a boy aged 14. The whole of the mucous surface is covered with polypoid growths, except a narrow strip at the apex, which is of a lighter tint (see p. 308).

These preparations are preserved in Guy's Hospital Museum.

Fig. A.

Fig. B.

ago, and forms the subject of a plate in Dr. Matthew Baillie's classical work, 'Illustrations of Morbid Anatomy,' published in 1799. The interior of the viscus is almost filled with a lobulated new growth, made up of closely packed pedunculated polypi. Some of these springing from the neck of the bladder have enormously dilated the urethra, and protrude from the external meatus. The organs are obviously those of a young girl, but no clinical history has been preserved.

On microscopical examination it is found that the section is composed of narrow bundles of closely packed spindle-shaped cells, cut in various planes. The bundles are only three or four cells wide, and these cells are remarkable for their great length and tenuity. Their nuclei are long and rod-shaped. Thus a close resemblance to muscle-fibres exists, and this is strengthened by the fact that in certain parts an imperfect transverse striation can be recognised in the cells. These bundles are held together by a loose matrix of richly nucleated tissue, the nuclei being chiefly round or oval in shape. In some places there are a considerable number of multinucleated masses, which are clearly giant-cells, and *not* transverse sections of the closely packed bundles above mentioned. In spite of the great age of the specimen, the sections stained very satisfactorily.

In the next preparation (Plate X, fig. D) the growths have assumed a remarkably similar polypoid appearance. They also protrude into the urethral canal, but obviously cannot dilate it to the same extent as in the female bladder just described. Hence urinary obstruction and its sequelæ are proportionately greater in boys than girls, while vesical irritability and the straining excited by the extrusion of polypi from the urethra are more marked in girls. It is worth noting that in the latter sex polypi extruded from the urethra appear in the vulva as a deep red lobulated tumour, which may be ulcerated and sloughy on the surface. A prolapsed ureter in the female may closely resemble such a tumour, and there are cases on record in which a portion of the ureter has been ligatured and excised under the impression that it was a polypus of the bladder.

Another interesting feature in this preparation (Plate X, fig. D) is the occurrence of a separate deposit of growth at the apex of the bladder outside the muscular coat. In the photograph the deposit is represented in section, and the centre of the growth is marked

by a small cavity due to mucoid degeneration. Microscopical examination of the polypi shows that they are composed of long spindle-shaped elements forming a dense tissue beneath the epithelium of the mucous coat. The cells are not arranged in definite bundles, but cross one another in various directions, and are mingled with curly, probably elastic fibres. Passing outwards from the epithelial surface the tissue becomes looser, and there is a considerable amount of granular matrix, with many round and oval nuclei scattered through it. In some of the long spindle-cells a transverse striation can be recognised as in the preceding specimen, but owing to its age the microscopical features are not so distinct as one would wish. The occurrence of striped cells in many sarcomata of the kidney in children is well known, and they are frequently present in other congenital sarcomata of infants, as well as of the fœtus. In all these situations the striped cells probably represent a metaplastic change of the better developed sarcomatous cells.

The nodule at the apex of the bladder is more cellular than the polypi. It is composed largely of interlacing bundles of spindle-shaped cells, with areas of myxomatous tissue.

This case is recorded by Mr. John Greene Crosse in his classical 'Treatise on Calculus' (1835), and the specimen is engraved in Plate XX, fig. 2, of that work. The patient was a boy aged two years, whose illness began about six months previously with frequent micturition and dysuria. The straining on micturition became very violent and painful, and he was repeatedly sounded for vesical calculus. No hæmaturia. Perinæal section was eventually performed, and many gelatinous polypi were excised. The child died forty-four hours after the operation.

Autopsy.—Ureters and pelves of kidneys much dilated; bladder hypertrophied; at its fundus there was a firm rounded mass, external to the muscular coat and covered by peritoneum. The mucous coat was thickened and gelatinous, and had still many polypoid tumours attached to it. These tumours were all covered with mucous membrane. Other viscera normal.

Sometimes these growths do not form multiple pedunculated or sessile polypi, but give rise to one or two finger-like processes of considerable length, which when crumpled up in the bladder seem to fill its cavity. If the viscus be everted, they are found to have a small well-defined area of attachment. In Plate X, fig. A, the bladder has been opened in front, and presents a single polypoid

tumour, 2½ inches in length, which has a constricted attachment to the left side of the neck. Around the base of the tumour may be seen a flattened, crescentic extension of the growth between the mucous and muscular coats, which has crossed the anterior wall, and formed a collar round the neck of the bladder, and extends a short distance down the urethra. All other parts of the bladder, including the trigone, are healthy. Histologically the tumour is very cellular, being chiefly composed of round and oat-shaped sarcomatous cells, and is traversed by many thin-walled vessels. There is also evidence of commencing invasion of the muscular coat, the growth having originated in the submucous tissue. In some parts of the section the tissue is myxomatous.

The history states that the bladder was removed from a male infant eighteen months old. The symptoms were those of stone in the bladder, and had existed some months. Death was due to suppurative nephritis.

A similar specimen is represented in Plate XI, fig. A, in which the cavity of the bladder when laid open was found to be entirely filled with growth, apparently springing from the whole extent of the mucous membrane. But on everting the viscus, as in the photograph, it became evident that there were only two finger-like processes, from 3 to 4 inches in length, which sprang from the fundus and right lateral wall of the bladder. They had a common origin from a rounded area not more than 2 inches in diameter, and the remainder of the bladder was quite free from growth. The extremities of these processes were ragged from maceration in the urine and sloughing, but their bases were covered with normal mucous membrane. Histologically the growth was composed of long spindle-shaped cells arranged in interlacing bundles. As in the last specimen, it originated from the submucous tissue, but there was no evidence here of invasion of the muscular coat.

In the next example the sarcoma was of more rapid formation, and has not assumed the polypoid shape. (Plate X, fig. B.)

The bladder has been freely laid open, and presents a lobulated fungating mass of growth which has involved the greater part of the mucous surface. The growing edge of the mass has a smooth covering of mucous membrane, but in other parts the tumour is much ulcerated. An enlarged lymphatic gland hangs from the

back of the bladder. Histologically the tumour is composed of round and oval cells.

The following notes of the case were kindly given me by Mr. Edmund Owen:—Boy, aged three and a half years, admitted to a hospital with incontinence of urine and great pain. The bladder was distended above the umbilicus, and after a large quantity of urine had been drawn off a hard rounded mass was felt in the hypogastric region, occupying the position of the bladder. His illness began two and a half months previously with pain on micturition, and he preferred to pass water lying down. Suprapubic cystotomy was performed, and as the growth could not be removed, the bladder was drained. A few hours later a portion of the growth protruded through the wound and had to be excised. From that time till death fresh lobules of growth continued to protrude from the wound, and were removed or sloughed off. Death occurred five weeks after admission. At the autopsy secondary deposits were found in some of the lymphatic glands of the pelvis, but the remaining viscera (except the bladder) were normal.

The modes of extension of growth incidentally alluded to in the preceding specimens are (*a*) in the substance of the mucous coat, (*b*) into the muscular tissue of the vesical wall, (*c*) as secondary deposits in the cellular tissue outside the wall of the bladder, and (*d*) as deposits in neighbouring lymphatic glands. A remarkable illustration of the first of these modes of extension is seen in Plate XI, fig. B. The specimen consists of the bladder of a boy about fourteen years of age, whose symptoms were referred to vesical calculus. The trigone and base of the bladder are covered with masses of pyriform polypi like those already described. Some of these are arranged in bunches like grapes, having very thin cord-like pedicles; others are nearly sessile. One tongue-shaped polypus projects into the urethra. The whole of the mucous membrane with the exception of a small area at the fundus is affected in a peculiar manner, being remarkably thickened and rugose; this condition passes through all stages into the polypi above described. The junction of this greatly thickened mucous membrane with the normal lining of the bladder is marked by a very definite line crossing the specimen, and there is a sharp contrast in colour, the healthy mucosa being smooth and white. The bladder is dilated and hypertrophied, the fasciculation being evident at the fundus. Both orifices of the ureters are sur-

rounded with growth, but the right is actually situated on the summit of a polypus. At the back of the specimen are two large cysts. One of these opens on the left of the verumontanum, and seems to be an enormous dilatation of the prostatic ducts. The other cyst is very similar in appearance, but is due to a sacculation of the extra-muscular termination of the right ureter. It has two openings into it, one is the end of the abdominal portion, and the other leads into the bladder; these orifices are separated by an interval of half an inch.

Histologically the thickened mucous coat in no way differs from the polypi. Both are composed of myxomatous tissue and of round and spindle-shaped cells, the latter arranged in interlacing bundles. The growth is entirely limited to the submucous tissue, the wavy elastic fibres of which form a distinct separation between it and the subjacent muscular coat.

This tendency of the vesical growths to spread along the submucous tissue constitutes an important distinction between them and the simple gelatinous polypi of the nasal mucous membrane. No doubt many of the polypi from this particular bladder are almost indistinguishable microscopically (except for their epithelial covering) from the nasal mucous polypus. But the malignant trait in their character is exhibited by the tendency of the neoplasm as a whole to invade the tissues surrounding its base, even though it does not infiltrate the muscle substance. Where that occurs the question of malignancy is not in doubt. Hence the opinion which I would venture to express, as to the nature of the mucous polypi of the bladder, is that all grades of malignancy will be found in them, and that the class of apparently simple vesical polypi passes insensibly into a group of tumours having some evidences of malignancy, and these again into another series, in which we meet with more or less rapid extension and even secondary deposits.

The low degree of malignancy of some of the connective-tissue tumours of the bladder in childhood is exemplified by the history of this specimen (No. 2104[22], Guy's Hospital Museum). The bladder has been laid open in front, and exhibits a sessile shaggy tumour the size of a walnut, springing from the mucous coat of the right lateral wall, some distance away from the orifice of the right ureter. The base of the tumour is smooth and covered with mucous membrane, but the summit is frayed from ulceration. A vertical section shows solid growth extending into the loose tissue beneath the

mucous membrane, but there is no invasion of the muscular coat, and the mass moves tolerably well over it. The bladder is otherwise normal and the ureters free. Microscopical sections of the specimen included the tumour, the submucosa, and the muscular coat. The new growth, which is very compact and firm, springs from the superficial part of the submucosa, a layer of fibrous tissue being left between the growth and the subjacent muscle. The neoplasm itself is composed of large spindle-shaped cells with well-defined nuclei, arranged in interlacing bundles, and consequently cut in various planes. There are no villi on the surface. Though the specimen is not in a good state of preservation, yet the histological appearances are more like those of a spindle-celled sarcoma than a fibroma. The clinical history of the case is interesting. The patient was a man aged thirty-four, who died of anæmia. He had suffered from recurrent attacks of hæmaturia for twenty-two years,—that is to say, from boyhood. As no other cause of the hæmaturia was found, the question arises whether the tumour could have existed twenty-two years. If this be admitted, then the growth must be classed with those of children, and marked as a very exceptional instance of persistence far into adult life, and as exhibiting the lowest degree of malignancy. No doubt the fact that it did not interfere with the orifices of the ureters explains the freedom from consecutive nephritis, which, as already stated, is the most potent influence in producing the high mortality of tumours of the bladder in children.

Of the *pericystic variety* of sarcoma in children I have little to say; nothing comparable to the specimens already described in adults has come under my notice. But there is good evidence that the cellular tissue in front of the bladder is capable of producing large myxo-sarcomata. A portion of such a tumour was kindly sent me by Mr. Pridgin Teale, and I am much indebted to him for notes of the case. A girl, aged 7, fell in crossing a stile, and struck the lower part of the abdomen. A few days later the mother noticed a swelling there, and when the child came under medical observation a fortnight after the fall, there was a tumour the size of a cocoanut in the hypogastric region, rather to the right of the median line. Laparotomy was performed, and a very soft growth found between the abdominal muscles in front and the peritoneum and bladder behind. It was extremely vascular, and could not be com-

pletely removed. The child died six weeks later with signs of rapid extension.

Microscopical examination of the growth reveals a very vascular myxo-sarcoma. The mucoid portions are arranged in strands or rounded areas, and on the whole the change is most marked in the vicinity of the vessels.

This specimen (No. 417B, R.C.S. Museum) in many respects resembles the preceding. It was taken from a child aged one year and four months, whose abdomen was much distended, measuring 21 inches in circumference at the umbilicus. The abdominal enlargement had been noticed for ten months, and there were signs of a large solid tumour occupying the front of the abdomen. At the autopsy a large oval tumour, 5½ inches in length, was found attached to the fundus of the bladder, and connected by soft adhesions to the back of the abdominal wall, lying between the muscles and the peritoneum. The pericystic connective tissue was directly continuous with that covering the tumour.

On section the growth was soft, gelatinous, and of a whitish colour mottled with dark red. Histologically it was a myxo-sarcoma with large tracts of mucoid degeneration, and some extravasations of blood. No secondary growths were found.

In conclusion, it is perhaps hardly necessary to point out that as in neither of these cases was the bladder invaded by the growth, so must they not be included in the term pericystic, in the sense in which it has been employed here when speaking of the sarcomata of the adult. *November 19th*, 1895.

X. MISCELLANEOUS COMMUNICATIONS.

1. *Acute nephritis due to oxalic acid poisoning.*

By W. Hale White, M.D.

So few authors allude to nephritis as a result of oxalic acid poisoning that I thought the two following cases worthy of record. The first was fatal, apparently from uræmia, six days after the acid had been swallowed. The *post-mortem* examination revealed acute tubal nephritis, with oxalic acid crystals in the kidney. Neither patient showed any œdema, a high tension pulse, or hæmaturia, nor did they complain of pain in the loins, although this might have been obscured by the general abdominal pains. The symptoms appear to be scanty urine—the fatal case had almost complete suppression—and albuminuria. The urine contained granular and epithelial casts, together with calcium oxalate crystals. The crystals and the albumen were found in both cases in the first specimen of urine obtained after swallowing the acid. In the case which recovered, the crystals disappeared from the urine in twenty-four hours, the albumen persisted four days, and the casts for about a week. The quantity of urine, after being scanty, gradually increased, until on the fifth, sixth, seventh, and eighth days from swallowing the acid much more than normal was passed, and it was pale and of low specific gravity. Seven days after taking the poison this patient passed a quantity of phosphates in his urine, and after this he often passed a considerable quantity of uric acid. In the fatal case the albumen and the oxalate crystals remained in the urine till the end, and the amount of urine passed in twenty-four hours varied between a drachm and 4 oz.

Dunlop,[1] in a most exhaustive article on the excretion of oxalic acid in the urine, refers the pains felt in the lumbar region by persons suffering from oxaluria to the passage of crystals along the pelvis of the kidneys and the ureters, but he does not describe cases

[1] 'Journ. Path. and Bacteriol.,' Edinburgh and London, vol. iii, p. 389.

of oxalic poisoning in the human subject. Dr. Stevenson has kindly called my attention to the fact that in Maschkas's [1] "Handbook of Forensic Medicine" it is stated that in both acute and chronic oxalic acid poisoning the crystals of calcium oxalate may be seen in the kidneys, and that nephritis too may be present; and also to the fact that Wynter Blyth,[2] quoting from Kobert and Kussner,[3] says that "when oxalate of soda was injected into animals the kidneys were dark, full of blood, . . . and there is observed in the cortical substance a fine striping, corresponding to the canaliculi; . . . . it is due to a deposition of oxalate of lime: no crystals are met with in the glomerules. . .. . . The urine was always albuminous, ... hyaline casts and deposits of oxalates never failed." Wynter Blyth goes on to say that in man also the white zone may be seen in the kidneys, which are congested and rich in oxalates.

The following are brief notes of my two cases:

Case 1.—Alfred C—, aged 58, a bootmaker, was admitted into Guy's Hospital on January 13th, 1896. For some time past work has been very uncertain, he has taken too much alcohol, and has been very depressed in his mind. This morning at noon he took an ounce of oxalic acid crystals in a cup of coffee; almost at once he felt a burning pain in his throat and the upper part of the abdomen, he vomited several times, and the pain became so great that he was unable to stand. He was at once brought to the hospital, twenty minutes after he had taken the poison, but he was sick many times on the way.

On admission.—Mr. C. D. Edwards, to whom I am indebted for the report of the case, noticed that the patient was cold and collapsed; his face was of an ashen colour; he was cold and clammy, the breathing was gasping, the pulse could hardly be felt at the wrist. The tongue was swollen and red, the mucous membrane over the front of the organ was quite smooth, the papillæ having disappeared; the fauces and palate were hyperæmic. The patient frequently retched and often vomited. The vomit was strongly acid, and gave a precipitate with calcium chloride, which was

[1] Maschkas, 'Handbuch d. Gerichtl. Med.,' Bd. ii, s. 117.

[2] Wynter Blyth, 'Poisons,' 3rd edit., p. 517.

[3] Kobert u. Kussner, "Exp. Wirkungen der Oxalsäure," 'Virchow's Archiv,' Bd. lxxvii, s. 209.

insoluble in acetic acid, but was soluble in hydrochloric acid. No blood was present.

The stomach was at once washed out, and then 4 oz. of Mistura Cretæ were introduced into it. Brandy and ether were injected subcutaneously, he was wrapped up in hot blankets, and hot bottles were applied to the feet. The pulse soon improved, and the respirations became more regular. For some time he was extremely cold (temp. 96°) and clammy, he was troubled with frequent retching, and complained of pain radiating over the abdomen, and of cramps in the feet and hands, but all these symptoms soon improved. Shortly after his admission he passed a little urine into his bed, and he passed no more for twelve hours, and then only a drachm. This contained a quantity of albumen, and no blood, but there were a number of small irregularly-shaped crystals, which disappeared on the addition of nitric acid. The bowels were well opened soon after admission; the motion contained no blood. Examination of his blood showed marked leucocytosis, and while normal blood coagulated in six minutes, that from this patient did not coagulate until sixteen minutes. As the day wore on he improved in all respects.

January 14th.—The patient seemed in all respects better, but he has only passed a drachm of urine. This contained much albumen and a few granular casts, but no blood. His bladder was empty; he was dry-cupped this evening; his bowels have been opened three times.

15th.—Again only a drachm of urine has been passed in twenty-four hours. It contains much albumen. He was dry-cupped over the loins.

16th.—To-day the total urine passed is 4 drachms. It contains albumen, a few casts, and a quantity of small crystals which dissolve on the addition of nitric acid. He takes his food well, and has no headache. He was given a hot bath this morning, and sweated profusely after it.

17th.—During the last twenty-four hours an ounce of urine has been passed. It contains no blood, but is highly albuminous, and under the microscope shows several small crystals, some of which are typical calcium oxalate. He was again dry-cupped, and had poultices applied to the loins.

18th.—The patient still appears well, but he has only passed 2 oz. of urine, albuminous, and containing calcium oxalate crystals.

There is considerable tendency to constipation, so his bowels have been kept well open with sulphate of magnesium or compound jalap powder.

19th.—He vomited once last night, and again this morning; he has some difficulty in moving, and says he feels very ill. His respirations are twenty-four to the minute, and the pulse is a little hard; but there are no twitchings and there is no œdema. He says he has no headache, but that he feels very helpless. He has passed 4 oz. of urine during the last twenty-four hours. It is albuminous, and contains crystals He lies on his back, and says he cannot move either his upper or his lower extremities, except he can flex or extend his fingers. He can move his head freely, and has perfect control over his facial muscles and sphincters; his pupils are equal, and react to light and accommodation, but no other reflexes except the left plantar could be obtained. He is quite rational, and occasionally retches.

He died suddenly this afternoon, while talking to his wife. He was rational up to the last, and was talking when he died. The pulse and respiration ceased simultaneously, He was covered with a cold sweat, but had no twitchings and no convulsions.

At the *post-mortem* examination the usual signs of recent oxalic acid poisoning were found at the lower part of the œsophagus and in the stomach. The kidneys weighed 15 oz.; they were enlarged, swollen, and of a dark red colour, and very full of blood. The capsules stripped off easily. A few faint whitish streaks could be seen in the pyramids of the kidneys. Histologically they were found to be in a typical condition of early acute tubal nephritis, the epithelium of the convoluted tubes being granular, swollen, and indistinct in outline; there was no appreciable interstitial change, and the glomeruli were not much affected; the vessels were considerably dilated, and several little clumps of oxalate crystals were seen lying in the tubes.

Case 2.—Charles H. G—, æt. 42, was admitted into Guy's Hospital January 19th, 1896. The patient swallowed a pennyworth of oxalic acid in some beer. He was given an emetic of mustard and water, and then brought to the hospital, where he arrived within half an hour of taking the acid.

On admission.—The tongue was very red; the patient was much collapsed, and vomited frequently. He was treated in the usual

way, and the symptoms of gastro-intestinal irritation had disappeared in twenty-four hours. The first urine obtained soon after admission contained some albumen.

January 20th.—Urine acid, sp. gr. 1018. There is a whitish deposit, which is found to consist of large, well-formed crystals of calcium oxalate. The urine contains albumen but no casts.

21st.—Only 12 oz. of urine were passed in the last twenty-four hours. The albumen is less; there are no oxalate crystals, but plenty of granular casts.

22nd.—Fourteen ounces of urine of the same character as yesterday were passed to-day; sp. gr. 1010.

23rd.—Urine, 34 oz., still a trace of albumen. Plenty of epithelial and granular casts; no oxalate crystals.

24th.—Urine, 96 oz.; to-day for the first time it contained no albumen. Faintly acid, 1010.

25th.—Urine, 104 oz., neutral, 1012, no albumen, and only one or two casts.

26th.—Urine, 72 oz., pale, sp. gr. 1012, no albumen, one or two granular casts, deposit of phosphates.

27th.—Urine, 74 oz., other characters as yesterday.

28th.—Urine, 36 oz., still one or two casts; there is a typical cayenne-pepper deposit of uric acid crystals.

From this time the patient did well; there was often a deposit of uric acid. The quantity of urine passed was normal, except on January 30th, when 84 oz. were voided. He was discharged February 4th.

March 17th, 1896.

---

2. *Notes on the occurrence of large quantities of hæmatoporphyrin in the urine of patients taking sulphonal.*

By Archibald E. Garrod, M.D., and F. Gowland Hopkins, M.B.

Many cases have recently been recorded in which urine of a deep red colour has been passed, which has proved on examination to be free from unaltered blood-pigment, but to contain large quantities of an iron-free derivative of hæmoglobin, namely, hæmatoporphyrin. We are not here confronted with the occurrence in the urine of an unusual or exceptional ingredient, for traces of

hæmatoporphyrin are usually, if not constantly, present in normal human urine, and under a great variety of morbid conditions larger amounts are met with in specimens which nevertheless exhibit no marked peculiarity of tint. On the other hand, the quantity of the pigment present in these dark red urines is far in excess of that met with in ordinary morbid specimens.

The evidence which connects the phenomenon under consideration with the administration of sulphonal is so cogent that the connection between them is usually regarded as an established fact. The great majority of the recorded cases have occurred in insane persons, by whom this drug has been taken for a considerable period; and furthermore, the renewal of the sulphonal treatment after recovery has more than once been followed by a return of the symptoms. The allied drugs, trional and tetronal, appear, moreover, to be capable of producing a similar effect.[1]

Except in the slightest cases, the excretion of dark red urine is only one of a group of symptoms which appear to be connected with the administration of sulphonal. Of these, vomiting, constipation (sometimes following an initial diarrhœa), and abdominal pain are the most constant. In a few cases febrile disturbance has been observed, but as a rule there is no rise of temperature. Paresis or paralysis of limbs, sometimes of an ascending type, with diminution of knee-jerks, is not infrequently present, and ptosis and diaphragmatic paralysis have been met with.

In some instances, when the drug is stopped, the urine gradually resumes its normal colour, and recovery takes place; but in many cases the patients pass into a condition of collapse, with cyanosis, feeble and rapid pulse, and coldness of the extremities. They may sink into a condition of apathy, or may remain conscious up to the time of death, which quickly follows upon the development of these symptoms.

Very few *post-mortem* records are available, and the changes met with at the autopsies have not been conspicuous. Lesions of the brain have been noted, and in one case there was mitral stenosis. The liver has more than once shown advanced fatty degeneration.

In a case recorded by Percy Smith[2] there was much *post-mortem* staining and injection of the vessels of the stomach and intestines,

[1] *Vide* Schultze, 'Deutsche med. Wochenschr.,' Leipzig, 1894, s. 152; and Herting, ibid., s. 343.

[2] 'St. Thomas's Hosp. Reports,' London, 1891, vol. xxi, p. 241.

and in the ileum there were one or two patches of submucous hæmorrhage—an observation which is of interest in connection with the views of Stockvis, which will be referred to later.

On the other hand, in a case reported by Oswald[1] the stomach and intestines showed nothing of special note, excepting some congestion of the first part of the duodenum, and in other parts corresponding to the coils.

In one of the cases recorded by Hammarsten,[2] although the unequal contraction of parts of the alimentary canal is carefully described, there is no mention of hæmorrhage or injection.

The kidneys have not shown any obvious naked-eye lesions, except such as could be referred to antecedent disease or senile change. But Stern and Oswald have described granular or necrotic changes in the epithelium of the glomeruli and secreting portions of the tubules, and Kast[3] observed hæmorrhage into the glomerular capsules in dogs poisoned with sulphonal.

That poisoning with sulphonal has some effect upon the kidneys is shown by the not infrequent appearance of albumen in the urine, when symptoms of poisoning develop, and by the presence of casts, hyaline, cellular, or granular, more frequently than can be ascribed to accidentally associated renal disease.

We must not omit to mention that Franz Müller[4] speaks highly of the therapeutic effect of alkalies, such as sodium bicarbonate, in these cases, and believes that such treatment, if adopted as soon as the unfavorable symptoms develop, is capable of averting a fatal ending. Stockvis endorses this recommendation, and it is obvious that this method of treatment should in future be given a trial when the above-described symptoms are met with in patients taking sulphonal.

Assuming, then, as we are apparently justified in doing, that in the great majority of instances the administration of sulphonal is the actual cause of the condition, we are nevertheless confronted with several important difficulties.

1. The action of the drug appears to be a cumulative one, and the patients have usually taken sulphonal for a considerable period of weeks or months before any ill effects are observed. Sometimes

[1] 'Glasgow Med. Journ.,' 1895, vol. xliii, p. 4.

[2] 'Upsala Läkaref. Förh.,' 1890–91, vol. xxvi, p. 267.

[3] 'Arch. f. exper. Path. u. Pharmakol.,' Leipzig, 1892–3, Bd. xxxi, p. 69.

[4] 'Wien. klin. Wochenschr.,' 1894, s. 252.

the symptoms have only appeared after the sulphonal has been discontinued, and in one of the cases recorded by Hammarsten an interval of no less than nine days had elapsed since the last dose was taken.

2. Under ordinary circumstances the urine of patients taking sulphonal does not contain more hæmatoporphyrin than that of other healthy or diseased individuals, as was found by one of us on the examination of specimens kindly supplied from Bethlehem Hospital;[1] and of the large number of patients who take this drug only a very few exhibit the symptoms under discussion.

3. In a *very large majority of cases* the patients who do so suffer are females. We do not know of any recorded fatal case in a male, and, indeed, have only met with the mention of two cases of a slight character in such subjects. One of these, which is quoted by Franz Müller,[2] was that of a man suffering from advanced tabes dorsalis, who had taken from half a gramme to a gramme of sulphonal nightly for two months; and the other, referred to by Percy Smith, was that of an old man under the care of Dr. Savage, who had taken doses of 20 grains to 25 grains nightly for more than a year.

In ordinary morbid cases, on the other hand, we do not find that sex has any influence upon the increase of the urinary hæmatoporphyrin.

4. Lastly, there are a few cases recorded by MacMunn,[3] Ranking and Pardington,[4] Sobernheim,[5] and others, in which dark red urine, rich in hæmatoporphyrin, was passed by patients who had taken no sulphonal. In some of these, and notably those of Ranking and Pardington, in one of which acetanilide was given, general symptoms somewhat resembling those of the sulphonal patients were observed, but in others this was not the case. We do not propose at the present time to enter upon any discussion of the origin of urinary hæmatoporphyrin, but it is necessary to mention the views recently enunciated by Stockvis,[6] who believes that the traces present in normal urines, and the larger amounts met with in

[1] 'Journ. Path. and Bacteriol.,' Edinburgh and London, 1892, vol. i, p. 187.

[2] F. Müller, loc. cit.

[3] 'Journ. Physiol.,' Cambridge, 1890, vol. xi; 'Proc. Physiol. Soc.,' London, p. 13.

[4] 'Lancet,' London, 1890, vol. ii, p. 607.

[5] 'Deutsche med. Wochenschr.,' Leipzig, 1892, s. 566.

[6] 'Zeitschr. f. klin. Med.,' Berlin, 1895, Bd. xxviii, s. 1.

disease, are alike derived from the blood-pigment contained in the food; whereas he ascribes that present in cases of lead poisoning, and the far larger amounts met with in sulphonal urines, to hæmorrhage into the mucous membrane of the alimentary canal; the conversion of the blood-pigment into hæmatoporphyrin being in these last cases materially aided by the presence of the sulphonal which causes the hæmorrhages. Concerning these views we would here merely state that our own observations and experiments make us hesitate to accept them as offering a complete explanation of the observed phenomena, and as regards normal and ordinary morbid urines, we question strongly the correctness of Stockvis's theory. The grounds for this attitude we hope to set out fully on a future occasion.

On the other hand, the observations to be described in this paper add in one respect to the evidence in opposition to the view that increase of urinary hæmatoporphyrin implies excessive blood destruction, for the presence in the urines, examined by us, of large quantities of this iron-free derivative of hæmoglobin was not attended by any corresponding increased excretion of iron. Blood examinations in the sulphonal cases are few in number. Percy Smith[1] did not find in his cases any greater diminution of blood-corpuscles, or of hæmoglobin, than is usually met with in cases of melancholia, from which disease the patients were suffering. In one case the number of red corpuscles per cubic mm. was no less than 4,600,000.

In a case recorded by Oswald[2] three examinations of the blood, at intervals which are not stated, gave results varying between 3,520,000 and 3,150,000, a difference so small that no great significance can be attached to it. On the other hand, conspicuous anæmia is frequently mentioned in the clinical reports, and E. Schäffer[3] describes a great diminution both of red corpuscles and of hæmoglobin in his case, but neither the hæmoglobinometer nor hæmocytometer was employed.

Franz Müller[4] states that in his case the percentage of hæmoglobin fell to 45, and returned to 85 per cent., after the hæmatoporphyrinuria had ceased. He, however, gives no enumeration of the corpuscles.

[1] P. Smith, loc. cit.

[2] Oswald, loc. cit.

[3] 'Therap. Monatsb.,' Berlin, 1893, s. 57.

[4] F. Müller, loc. cit.

Since the point to be ascertained is whether the passage of large amounts of hæmatoporphyrin in the urine is *necessarily* accompanied by excessive blood destruction, it is obvious that the force of even a few observations which do not reveal any successive hæmolysis, such as those of Percy Smith and Oswald, is not impaired by the fact that in other cases there is a condition of advanced anæmia. On the other hand, it should be noted that, as Salkowski has pointed out, a given quantity of hæmatoporphyrin represents more than twenty times its own mass of hæmoglobin, and this observer calculated that in one of his cases the daily excretion of hæmatoporphyrin corresponded to about $\frac{1}{32}$ of the total hæmoglobin of the patient.

In all our specimens, as will be seen from the following account, very little urobilin was present, and in the third case, in which a special method was employed for its extraction, a quantity much smaller than that usually got from normal urine was obtained. Seeing that there is strong evidence that excess of urobilin in the urine accompanies excessive hæmolysis, the above fact is also significant in this connection.

The chemical and spectroscopic characters of the dark red urine of sulphonal poisoning have been carefully studied by Salkowski,[1] Hammarsten,[2] Stockvis,[3] and MacMunn,[4] and our object in bringing forward the following three cases which have come under our notice is to emphasise certain points to which these eminent observers have already called attention, and in certain particulars to supplement their results.

For the following clinical notes we are indebted to Drs. J. Delpratt Harris, W. M. Abbot Anderson, and M. J. Nolan, who respectively had charge of the cases, and from whom the specimens were received.

Case 1.—Miss M. J. W—, aged 50, single; chronic epileptic since sixteen years of age. Suffered much from sleeplessness, and had taken sulphonal more or less continuously since May, 1889. The drug has occasionally been omitted for a night or two, or even for a week, and then, insomnia supervening, patient has always

[1] 'Zeitschr. f. physiol. Chem.,' Strassburg, 1891, Bd. xv, s. 286.
[2] 'Skandin. Arch. f. Physiol.,' Leipzig, 1892, Bd. iii, p. 319.
[3] 'Nederl. Tijdschr. v. Geneesk.,' Amsterdam, 1889, p. 413.
[4] See Percy Smith, loc. cit.

returned to the sulphonal, and has occasionally taken two doses of 20 grains in eight hours. It has always been found to agree well, and surpassed chloral in producing sleep; for a relatively larger amount of the latter was required to produce the effects of 20 grains of sulphonal—her usual dose. Her sleeplessness, if neglected, resulted in attacks of epileptic mania, of which there were three in seven years.

March 12th, 1895.—There is much pain in the lower part of the bowels over the region of the bladder, with tenderness over the right ovary and constant sickness. She was given a carminative mixture.

14th.—There is some constipation. Colocynth, calomel, and belladonna were given in pill. From this date to April 10th patient was better. She was taking a tonic of gentian and nux vomica.

April 10th.—Much abdominal pain again felt. It seemed to concentrate in the region of the bladder, and was increased by pressure in this region. Constant sickness and complete loss of appetite. Buchu and hyoscyamus in large doses had no effect on the pain.

13th.—To-day it was noticed, after a fit, that the urine was of *deep claret colour*, but had no sediment. Temperature normal. Pulse quick and feeble. She is so weak that she cannot raise her hand from her bed. She suffers from piles, but there is little or no bleeding. Up to this date sulphonal had been taken almost every night, and on the 10th she took 40 grs. during the night. The quantity of urine averaged two pints daily. There was never any decided reaction with albumen tests. The colour was deepest about April 13th. It very gradually became less so, and by the 26th was but slightly coloured.

26th.—Patient steadily became weaker and weaker, and very pale and anæmic, complaining of thirst, and looking like one very much exhausted from hæmorrhage. During the night she had an epileptic seizure, from which she never quite recovered, and died shortly afterwards. There was never any œdema of the extremities, or any ascites. No pulmonary symptoms until the very end, when œdema occurred. The pain and sickness were the first symptoms of any serious trouble (March 12th). One month after this began the dark-coloured urine was first passed, and a fortnight later death occurred. The abdominal pain was at first felt as high as the liver, later it was always over the bladder.

CASE 2.—Female aged 32, married at twenty. Treated for hysteria by Weir Mitchell method in 1892. Bad attack of erysipelas in 1887. In 1893 showed evident signs of myxœdema.

December 26th, 1894.—First showed signs of typhoid fever. This became of very severe type, and was followed by relapse. Ill two months, but well enough to go to Bournemouth at the end of February, 1895. During this illness the patient slept badly, and took sulphonal in doses from 10 to 20 grs. The use of the drug continued from December 26th, 1894, to early in May, 1895. Towards the middle of April she returned to London from Bournemouth, and was progressing favorably. One day towards the end of April she unduly exerted herself, came home exhausted, and had to take to her bed. Shortly afterwards she passed dark red urine. From this time she continued to grow weaker and weaker, and died May 11th, 1895.

CASE 3.—Female aged 33, married, mill worker, admitted to Downpatrick Asylum, April 12th, 1895, suffering from acute melancholia of the agitated type. The attack commenced immediately after the birth of her child, eight months previously. This child was nursed at the breast up to a few days before admission. Physical examination gave no evidence of organic disease. She had been partially refusing food for some weeks, and had been sleepless and constipated, and was in a very low state of health. The skin of the entire body was very dark-coloured, suggestive of the bronzing of Addison's disease, and the face, in addition, was of the peculiar cachexia seen in malignant disease; frequent and careful examinations, however, failed to determine any such conditions, nor did the patient complain of any symptoms associated with the diseases named.

She was put to bed, mild aperients and abundant nourishment were given, and 20 grs. of sulphonal were administered every second night to secure sleep. Sulphonal was continued in this way for a few weeks, by which time the condition had improved. The drug was now given only at irregular intervals (in doses of 20 grs.) whenever patient was reported as awake all the previous night. There was very little change in the mental and physical state from this time to the first week in July, when a violent relapse caused sulphonal to be given twice daily (10 grs. at 12 noon, and 20 grs. at 6 p.m.) for a fortnight; but as patient did not seem to derive the

benefit expected, the *drug was abandoned on the 21st July, and was not administered again.*

A few days later she was quieter, and complained of weakness, which increased until the 31st July, when she was confined to bed. There was not at any time stupor, motor inco-ordination, pain, vomiting, feverishness, or gastro-intestinal irritation.

August 1st.—Patient was very weak, complaining of general lumbar pain; temperature and pulse normal. For the first time the urine was noticed to be of a brownish tinge, but as it was mixed with a small quantity of fæces it was difficult to determine the true character of the pigmentation. The quantity passed was not over the average.

2nd.—The discoloration was more pronounced, the urine being now of the shade of *old* port wine. Held up against the light it was quite tawny, showing no cloudiness or "smoky" appearance. On examination albumen and sugar were found absent, and for the first time hæmatoporphyrin was suspected. Thus the condition began ten clear days after sulphonal had been wholly abandoned. It continued and increased daily to the date of death, 9th of August, which was nine days from the date of its first appearance. The clinical symptoms during these nine days were confined to intense weakness (the pulse being very small and slow), and a change in the colour of the skin. The dark tinge of the latter became clearer, owing to the increased anæmia, which was indicated by a pearly white sclerotic, blanched lips and fauces. The temperature became slightly subnormal, and respiration feeble. There was no indication of nephritis, which was daily looked for. After death the skin was of a whity-brown hue. No *post-mortem* was allowed.

It will be observed that all three patients were females, all had taken sulphonal, and in all the cases death followed shortly after the development of the symptoms, the intervals being thirteen, fourteen, and nine days respectively. In Case 1 the symptoms conformed to the ordinary type. A point of special interest in this case was the long period during which sulphonal had been taken without any ill effect (no less than four years). The pain in the region of the bladder here complained of has been met with in other cases, and was a conspicuous feature in the cases described by Ranking and Pardington, in which sulphonal was not given. The second and third cases were peculiar in the absence of gastro-intestinal sym-

ptoms. In Case 3, as in one of Hammarsten's cases above referred to, an interval of no less than ten days elapsed between the administration of the last dose of sulphonal and the onset of the symptoms. In connection with the pigmentation of the skin in Case 3, which was present before any sulphonal was taken, it is interesting to note that caseation of the supra-renals and bronzing were present in a sulphonal case, referred to by Oswald as having occurred in the Edinburgh Royal Infirmary. We much regret that we have no *post-mortem* observations to add to the few already published.

General Character of the Urine.

In all three cases the specimens came into our hands for examination only a few days before the death of the patient. Any attempt to make a series of observations, either on the pigmentation or general condition of the urine, was therefore prevented. The specimens examined were passed when the condition of dark urine was at its height. Their colour was that of port wine. All the specimens were acid, and of low specific gravity (1010—1013). The percentage of urea was about the same in each (2 per cent.). In none was more than a minute trace of albumen present: one specimen from Case 1 was in fact entirely free; Case 3 showed more than the others, but the quantity was extremely small. In spite of this, the deposits obtained by use of the centrifuge contained abundant tube casts. In the absence of any renal symptoms, and in the practical absence of albuminuria, this fact seemed somewhat surprising; but the literature of the subject as stated above shows that the presence of casts is common in these cases. In ours they were very numerous indeed. In addition to the ordinary hyaline and epithelial varieties, there were many well-formed, finely granular casts, of purplish colour, which appeared to be almost wholly made up of pigment. The cells composing the epithelial casts were deeply pigmented, and the deposit comprised numerous isolated epithelial cells, and many large granular leucocytes, all of which contained much pigment. This description is true of all three cases.

Absence of Iron from the Urine.

It seemed a point of some interest to determine whether the great increase in the excretion of the iron-free derivative of hæmoglobin was accompanied by any increased excretion of iron, present

in some other combination. In Case 1, 8 oz. of urine were evaporated to dryness, great care being taken to prevent contamination with extraneous iron. The residue was burnt in a muffle-furnace, the ash dissolved in hydrogen chloride, and, after the addition of a little hydric nitrate, the solution was evaporated to dryness. Taken up again in a little dilute hydrogen chloride and filtered, the solution was made just alkaline with ammonia, and boiled. The ammonia precipitate was filtered off, dissolved in 2 c.c. of dilute hydrogen chloride, the solution divided into two parts, and tested (*a*) with sulphocyanide, and (*b*) with ferrocyanide of potassium. *Neither reagent gave the least trace of colour.* Eight ounces is perhaps a somewhat small quantity to use for this purpose, but control specimens of normal urine gave in several cases distinct iron reactions from the same quantity, so there can be no doubt that any increase in the urinary iron was absent from Case 1. The other cases (in which, however, still smaller quantities had to be used) also gave negative results.

Spectroscopic Examination of the Urine.

Case 1.—*Specimen* A.—The urine had a deep port-wine colour. In a layer of 1·5 cm. a band was seen in the red from λ 624 to λ 612. This is the first band of alkaline hæmatoporphyrin; from the D line onwards the spectrum was completely obscured.

Diluted with an equal quantity of water in a depth of 1·5 cm. the following bands were seen:

1. λ 624—612 } rather faint.
2. λ 589—573 }
3. λ 546—532.

From D onwards towards the blue the spectrum was much obscured. Absolute darkness extended from a band λ 515.

On the addition of a few drops of hydrogen chloride, the bands read—

1. λ 597—589.
2. { λ 576—570, shading λ 558—540.

These are the bands of acid hæmatoporphyrin. There was darkness from λ 529.

On shaking with acetic ether a pink ethereal extract was obtained, which showed the following bands:

Shading to λ 642.
1. λ 628—620.
2. λ 601—597.
3. λ 586—569.
4. λ 540—525.
5. λ 511—482.

This is a slightly modified neutral hæmatoporphyrin spectrum.

The subjacent liquid, after treatment with the acetic ether, was of deep brown colour, showing complete absorption of the spectrum from λ 549.

On the addition of a drop of hydrogen chloride the pigment left the acetic ether for water, forming a deep pink solution, which showed the acid hæmatoporphyrin bands with great intensity. No urobilin band. Readings:

λ 597—λ 589.
λ 576—λ 560—543.

A more concentrated specimen, similarly treated, showed a faint urobilin band.

The soda method and the ammonium chloride method were quite unable to cope with the amount of hæmatoporphyrin here present, the precipitates being able to carry down only a small portion.

The extract from the soda precipitate was peculiar in that the hæmatoporphyrin could not be, by any means, persuaded to go into chloroform.

Specimen B.—This was much darker than the earlier specimen just described. The colour was almost black. Shaken with acetic ether it yielded an extract less distinctly pink than that obtained by the same method from Specimen A (*v. supra*). After extraction with the acetic ether the urine retained a deep brown colour, and absorbed the spectrum quite up to the red.

About 4 oz. were treated by Salkowski's barium method. The precipitate had a deep mauve colour, the filtrate was yellow. The precipitate was washed and treated with alcohol acidified with hydrogen sulphate.

The extract had a very deep colour. From the acid liquid, after the addition of water, chloroform took a very deep red colour. The supernatant liquid was poured off and water substituted. On shaking a mahogany-brown pigment left the chloroform, and also a little hæmatoporphyrin. After repeated washing, the chloroform

was pink, and showed the five-banded spectrum of neutral hæmatoporphyrin with great intensity.

A specimen of the *original urine* was repeatedly extracted with acetic ether.

The first and second ethereal extracts were red-pink, and showed the following bands:

1. λ 628—624, fainter.
2. λ 586—570 } very dark.
3. λ 549—526 }
4. λ 508—486, faint.

The appearances suggested that much two-banded (oxyhæmoglobin-like) hæmatoporphyrin was mixed with a small quantity of the ordinary kind.

The third ethereal extract was reddish brown, and showed the two dark bands very clearly. No band was seen in red, and that in blue was very faint.

Case 2.—The urine had a dark port-wine colour. Filtered, and examined direct in a layer of 2·25 cm., the specimen allowed only a little red to penetrate. With a wider slit a band was seen:

λ 624—612, darkness from D.

On dilution—

1. λ 624—λ 612, faint.
2. λ 586—λ 573.
3. λ 549—λ 529.

General darkness from λ 515.

On adding hydrogen chloride the acid hæmatoporphyrin bands appeared:

1. λ 597—589.
2. λ 560—543.

On shaking with amylic alcohol, a very intense spectrum of alkaline hæmatoporphyrin was obtained:

1. λ 626—618.
2. λ 597—586—568.
3. λ 549—532.
4. λ 515— ?

The extract was red, the subjacent fluid dark brown.

Salkowski's barium method gave a red precipitate, the filtrate being pale yellow.

The precipitate was washed and treated with alcohol, acidified with hydric chloride.

The acid extract had a deep red colour (not pink), and showed the acid bands well, and with ammonia the alkaline band strongly, but the pigment could not be got to go into chloroform.

The Salkowski extract was neutralised with ammonia, and evaporated nearly to dryness. On adding a drop of hydrogen chloride and shaking with acetic ether, the ether became pink, and showed a three-banded spectrum, as follows:

1. λ 570—536.
2. λ 532—517.
3. λ 506—481.

A specimen of the same urine shaken with acetic ether gave a reddish-pink extract, which showed the five-banded neutral spectrum:

1. λ 628—620.
2. λ 601—592.
3. λ 586—567.
4. λ 549—526.
6. λ 513—484.

Case 3.—The colour of the specimen resembled that of dark port wine.

A portion was repeatedly extracted with acetic ether. The extracts were red, and showed the bands of alkaline hæmatoporphyrin with decreasing intensity in each successive extract.

After three extractions the urine no longer showed these bands, but still had a dark red colour. This specimen, from which almost all the hæmatoporphyrin had been extracted when treated with barium chloride and hydrate (Salkowski's process), gave a purple precipitate, which, when treated with alcohol, acidified with sulphuric acid, gave a reddish-brown extract, which showed the bands of acid hæmatoporphyrin very faintly, and much general absorption from the green onwards. On the addition of ammonia the liquid became brown, and no distinct bands were seen.

The original urine, diluted with water, showed a band in red (λ 6200—6100), a shading from λ 6010—5825, and complete absorption beyond. In a thinner layer the following spectrum was seen:

1. λ 6200—6100, faint.
2. λ 5860—5570, faint.
3. λ 5430—5320, very dark.
4. λ 5080—4690, very dark.

These are the bands of alkaline hæmatoporphyrin, but the great relative intensity of the third and fourth bands, and a shading connecting them, showed the presence of a second pigment. On the addition of sulphuric acid the bands of acid hæmatoporphyrin appeared, and also a very broad band with ill-defined edges from about λ 5290—4690.

To another portion more than its own bulk of rectified spirit was added, which caused turbidity, and, on filtering, a brown precipitate was collected. This yielded hæmatoporphyrin to alcohol, acidified with acetic acid, showing that in this, as in Stockvis's case, some of the hæmatoporphyrin was insoluble in neutral alcohol.

The residue upon the filter was readily dissolved by a dilute solution of caustic soda in water, yielding a brown solution which showed the following bands:

1. λ 6200—6100, faint.
2. λ 5760—5570, faint.
3. λ 5460—5370, dark.
4. λ 5170—4910, dark.
5. λ 4720—4570, faint.

Here the third and fourth bands were far darker than the others, which agree with those of alkaline hæmatoporphyrin, the fifth band in the extreme violet being one which is only seen when an excess of alkali is present. This band disappeared on the addition of acetic acid.

The dark third and fourth bands were those which were so conspicuous in the original urine, and the spectrum was obviously either a modification of that of alkaline hæmatoporphyrin, or that of a mixture of two pigments, one of which was ordinary hæmatoporphyrin. That the latter was not the case was shown by the fact that on the addition of sulphuric acid the bands of acid hæmatoporphyrin did not appear, but only an ill-defined absorption band from λ 5290—λ 4770.

Another portion of the original urine treated by Salkowski's method yielded a brown precipitate, from which a deep red alcoholic extract was obtained, which showed the bands of acid hæmatoporphyrin with great intensity, but there was also much general

absorption from the green onwards. On the addition of ammonia the liquid became much paler, brown in colour, and showed the bands of alkaline hæmatoporphyrin. Only a trace of urobilin was present in this urine.

It should be mentioned that in this case the examination of the urine was not made until some weeks after it had been passed, and there was reason to believe that when fresh it contained little, if any, ordinary hæmatoporphyrin. Such development of the pigment in the urine, on standing, has been noticed by several observers.

In all the above specimens there was evidence of the presence of a reddish-brown pigment, producing a great general absorption of the more refrangible portion of the spectrum, but showing no bands. Owing to this, the urine always remained deeply coloured after all or nearly all the hæmatoporphyrin had been extracted.

In reviewing the results of the above examinations, one point to which we desire to call attention is that the methods which we have found most serviceable for the detection of hæmatoporphyrin in ordinary morbid urines (viz. that by the addition of caustic soda, and extraction of the pigment from the washed phosphate precipitate, and that by saturation of the urine with ammonium chloride, and treatment of the urate precipitate with a mineral acid) are useless when we are dealing with such large quantities of the pigment as were present in the urines above described. Both the methods referred to—the former especially—are extremely delicate, and serve for the detection of the traces present in normal urines, but they are not true precipitation methods, the pigment being merely carried down upon the precipitates of phosphates and urates respectively, to which, however, it clings with sufficient tenacity to allow of the washing of the sediments.

Either of these methods, when applied to the sulphonal urines, leads to the separation of only a very small part of the contained hæmatoporphyrin, which is here present in quantities which completely overtax the carrying power of the precipitates.

Salkowski's method of precipitation with barium chloride and hydrate removes all the abnormal pigments, leaving the filtrate of a pale yellow colour, but, as we have seen, much of the pigment so carried down is, in most instances, not hæmatoporphyrin.

We have found the method above described, of repeated extraction with acetic ether, very useful for the separation from each other

of the abnormal pigments, and the earlier extracts so obtained contain much less of the pigments other than hæmatoporphyrin than do similar extracts obtained by shaking the urine with amylic alcohol.

Another point upon which, in our opinion, sufficient stress has not hitherto been laid, is this, viz. that the deep colour of these sulphonal urines is *only in part* due to the hæmatoporphyrin which they contain.

A specimen of urine may show, when examined with the spectroscope in a sufficiently deep layer, the entire spectrum of the so-called alkaline hæmatoporphyrin so distinctly that the bands can be accurately measured, and yet have merely a rich orange colour; nor have we been able, by adding to normal urine isolated urinary hæmatoporphyrin in such quantities that the absorption bands were seen with great intensity, to reproduce at all the colour of the sulphonal specimens.

On the other hand, in the sulphonal urines, the bands of hæmatoporphyrin—although, as far as the general absorption allowed them to be seen, they were quite distinct—did not in any way correspond in definition to what might have been expected if the tint of the liquid had been largely due to that pigment. In some specimens the quantity present was much larger than in others, but those which contained most hæmatoporphyrin were not the darkest in colour.

In some instances there was reason to believe that much of the additional abnormal colouring matter was in the form of derivatives of hæmatoporphyrin, but even this cannot be asserted of all the cases.

In Case 1 there was present, in addition to much ordinary hæmatoporphyrin, a large quantity of a pigment, undoubtedly allied to it, which showed two absorption bands resembling those of hæmoglobin, and in this the specimens agreed with that examined and described by Stockvis, who separated the two-banded pigment from the ordinary hæmatoporphyrin by dialysis. The two-banded pigment under discussion resembled that found by one of us in urate sediments from urines fairly rich in hæmatoporphyrin, and a similar spectrum is yielded by the zinc compound of that pigment.

In all three cases the colour of the urine appeared to be in great part due to a reddish-brown pigment, which showed no bands, but largely absorbed the violet end of the spectrum. It seems highly probable that this was identical with the reddish-brown pigment

found by Hammarsten in three out of the four specimens which he examined, and to which he also attributed an important share in their coloration. This is a point of some importance, since there is a tendency to ascribe to any band-yielding pigment or pigments which they may contain an undue share in the coloration of specimens of urine. We see this well exemplified in the ascription of the colour of normal urine to urobilin, a pigment which, in solutions so dilute as to show a band such as is yielded by normal urines (when, indeed, they yield a band at all), has hardly any appreciable tint. We are also prepared to maintain that the dark colour of the urine in cases of pernicious anæmia is only in small part due to the excess of urobilin which it is wont to contain.

In Case 3, as in Stockvis's case, a considerable quantity of the abnormal pigment was precipitated by the addition of an excess of alcohol, and the precipitate so formed consisted in part of hæmatoporphyrin which was taken up by alcohol acidified with acetic acid, and in part of a brown pigment, readily soluble in alkalies, and which showed a spectrum somewhat resembling that of alkaline hæmatoporphyrin, but which, on the addition of a mineral acid, yielded only a broad and very ill-defined absorption of the blue and green.

It is found that samples of hæmatoporphyrin derived from different urines are apt to exhibit curious differences both from each other, and from specimens prepared from hæmoglobin. Such slight differences as relate merely to displacements of the absorption bands can be explained as the results of differences of solvent, of the degrees of acidity or alkalinity of the solutions, and such like causes; but, as we have seen, there are also observed remarkable differences of solubility, examples of which have been quoted above, and are perhaps more conspicuous in dealing with the pigments from these dark red urines than with those from ordinary morbid specimens.

We may quote the precipitation by alcohol, in which liquid hæmatoporphyrin is usually freely soluble, and the fact that the hæmatoporphyrin present in Cases 1 and 2, unlike any other specimens that we have ever met with, refused entirely to go into chloroform out of an aqueous-alcoholic solution acidified with acetic acid.

Such differences have been observed by all who have made a special study of such urines, and we have yet to learn how far they are due to actual differences in the pigments themselves, and how

far to the disturbing influence of impurities present in the solutions dealt with. *November 5th*, 1895.

---

3. *On the xerosis bacillus.*

By J. Eyre, M.D.

[With Plate XV .]

Recently, whilst investigating a series of cases of follicular conjunctivitis, which differed in some respects from the ordinary form assumed by that affection, a micro-organism was isolated from the conjunctival secretion, so closely resembling the diphtheria bacillus that I at first supposed them to be identical. A careful and comparative study, however, of the two organisms, with regard to their mode of growth upon various media, together with their morphological appearances, convinced me of my error; and it seemed to me, in view of the importance to ophthalmic surgery of lesions associated with, and dependent upon, the Klebs-Löffler bacillus, that an account of the results obtained might be of some interest.

Before proceeding to describe the bacillus—which I now know as the xerosis bacillus of Neisser—a few words are necessary as to the sources from which it was obtained.

Cases.—The form of conjunctivitis in which the organism occurred was characterised clinically by a number of small, irregularly oval-shaped, pinkish, œdematous bodies (resembling somewhat the flabby granulations covering the base of a varicose ulcer), situated in the lower conjunctival fornix, and not encroaching upon the ocular conjunctiva. These were probably due to hypertrophy of the papillæ and subendothelial adenoid tissue. Injection of the conjunctival vessels, lachrymation, photophobia, inability to continue near work, distress at night and when using artificial light, were among the symptoms. Twelve such cases were examined, six males and six females. The micro-organism was isolated from each case. Of the females, two were classmates at school; the remaining four were members of the same family—an interval of about a week being noted between the onset of the attack in the mother and in

the three children. Among the males no such connection could be traced.

In a thirteenth case—one of acute trachoma—a sago granule was opened, with aseptic precautions, and the fluid taken from its interior was found to contain this organism in pure culture.

With two exceptions the organism was obtained from the conjunctival secretion in pure culture. One of these exceptions was a brewer's lad, whose secretion contained also a white torula. The other exception was one of the schoolgirls, the *Staphylococcus pyogenes aureus* being associated with the xerosis bacillus. I have also, up to the present time, examined the conjunctival secretion taken from twenty-five pairs of normal eyes, by means of cover-slip preparations and cultivations, but have not succeeded in detecting this bacillus.

History.—The xerosis bacillus was discovered in large quantities by Kuschbert and Neisser, in a condition known as xerosis conjunctivæ, and their observations have been confirmed by many authors since.

Babes found it in eight cases of trachoma, whilst Deyle isolated it from fifteen cases of chalazion formation, and indeed considered that it was the cause of this disease, as he was able to reproduce such formations in animals by means of inoculations of this organism. It has been isolated also from other situations. For instance, Neisser states that he found it in cases of soft chancre, vaginal discharge, ulcers of the leg, &c. There is some difference of opinion as to its occurrence in the normal conjunctival secretion. On the one hand, Fränkel and Uthoft state that it is frequently present in normal eyes. On the other hand, Franker examined 120 normal conjunctivæ without being able to discover the bacillus.

Biology and morphology of the xerosis bacillus.—The xerosis bacillus is a non-motile, non-liquefying, facultative, anaërobic, non-sporing bacillus. Cover-slip preparations, made directly from the conjunctival secretion, showed a straight or very slightly curved bacillus about 1·75 μ in length by ·5 μ broad, staining irregularly, some portions of the protoplasm, especially at the poles, taking the stain (carbol-methylene-blue) deeply, whilst others were almost colourless, thus giving rise to a beaded appearance.

First cultivations were obtained by streaking the conjunctival secretion upon inspissated blood-serum, as it was found, by means of simultaneous plantings upon other media (agar, glycerine-agar, and gelatine), that it would not grow upon them.

At the end of twenty-four hours no growth was visible to the naked eye, nor could any be made out microscopically. After a period varying from thirty-six to forty-eight hours after inoculation an abundant growth made its appearance. Sub-cultures from this grew readily on all ordinary media in eighteen to twenty-four hours, and it is these early sub-cultures I now propose to describe, giving at the same time, in parallel column, a description of a fairly typical long Klebs-Löffler bacillus when cultivated under similar conditions.

Description of Early Sub-culture of *B. Diphtheriæ* and Xerosis Bacillus.

BLOOD-SERUM (Inspissated).

Klebs-Löffler Bacillus.	*Xerosis Bacillus.*
Macroscopic.	
Similar growths, but moist—not scaly.	Growth visible to the naked eye at the end of 12—18 hours, as small spherical opaque white colonies, having a slightly heaped-up appearance in the centre, and with clearly defined regular margins. The growth is dry and scaly-looking, adhering firmly to the surface of the medium. The water of condensation may also contain a few scaly colonies, which have been washed off the lower part of the surface.
Microscopic, *at* 12, 18, *and* 24 *hours* (see Plate XV fig. 1).	
The majority of the bacilli measure 1·8 μ in length and ·8 μ in breadth, and stain intensely in the centre. Forms are also present about twice this length, and staining segmentally. There are also present long bacilli, slightly curved, and clubbed at either end, and a few small pear-shaped forms.	The bacilli are generally straight, occasionally two elements being joined together, either in the same straight line, or at a slight angle. The bacilli are collected together in small groups of 6, 10, 20, and upwards. There is very little segmentation to be noticed at this stage. Another form also occurs—slightly curved bacilli, usually single or in pairs, exhibiting a fair amount of clubbing. The great majority are distinctly shorter than the Klebs-Löffler bacilli, are more regular in size, and more even in staining.

BLOOD-SERUM (INSPISSATED)—*continued.*

Klebs-Löffler Bacillus.	*Xerosis Bacillus.*
At 48 and 72 hours, 3 and 7 days.	
The greater number of the bacilli appear as darkly staining forms, short pear-shaped, clubbed forms, often transversely segmented, and long curved forms swollen at either end, and marked out with darkly staining segments. A fair proportion are unstained, or but faintly coloured. Metachromatism is common, especially with the clubbed ends of the bacilli.	Resemble the Klebs-Löffler bacilli closely. The individual bacilli are clubbed and segmented, both characteristics frequently being united in one element. Short pear-shaped bodies, transversely striated, are seen. The staining is irregular in depth and character. The grouping of the bacilli into small bunches is still a marked feature; metachromatism is fairly common.

GLYCERINE SERUM (INSPISSATED).

Blood-serum to which about 5 per cent. of sterile glycerine has been added, previous to inspissation, forms an excellent medium.

MACROSCOPIC.

The character of the growth, though rather more luxuriant, is similar to that described under the previous heading (*vide* Blood-serum).

MICROSCOPIC.

The formation of clubbed forms, darkly staining oval or pear-shaped masses of varying size, and long swollen bacilli is very remarkable. Metachromatism is extreme.	Clubbed forms are noted early, and segmentation of the protoplasm shows up well, giving some of the bacilli a beaded appearance. Metachromatism is very pronounced. The arrangement of the bacilli in small groups is well marked. The morphological characters are precisely those met with in the conjunctival secretion.

AGAR-AGAR.

Agar-agar, especially that to which 5—7 per cent. glycerine has been added, forms a very good medium.

AGAR-AGAR—*continued.*

Klebs-Löffler Bacillus.	*Xerosis Bacillus.*
MACROSCOPIC.	
Plates.—The colonies are indistinguishable from those formed by the xerosis bacillus.	*Plates.*—The superficial colonies are whitish in colour by reflected, and yellowish brown or buff, by transmitted light. The outline is irregular and ill defined, and the surface rough and granular, showing a darker and better defined central or sometimes laterally placed vegetation centre. The deeply situated colonies are roughly circular or oval in shape, the outline is fairly sharp and well defined, and the surface appears coarsely granular.
Streak.—The growth is similar to that due to the xerosis bacillus at first, but after 48—60 hours the colonies of the Klebs-Löffler bacillus have increased markedly in size, are confluent and heaped up (may even reach a diameter of ⅛ in.).	*Streak.*—The growth is easily visible to the naked eye at the end of 18—24 hours, and consists of small, discrete, spherical, whitish, semi-transparent colonies, resembling those formed by pyogenic streptococci, rather than those due to the Klebs-Löffler bacillus. In from 3—6 days the individual colonies have perhaps increased slightly in size, but never become confluent or heaped up.
Stab-cultures do not grow so well as those of the xerosis bacillus, especially in the deeper parts of the stab.	*Stab.*—In stab-culture it grows well, and after six hours appears, at the lower end of the needle track, as a chain of distinct spherical colonies. After a time the majority of the colonies coalesce, and the needle track shows up as a distinct line.
MICROSCOPICALLY, *at* 24 *and* 48 *hours* (see Plate XV, fig. 2).	
Similar in morphology to bacilli grown upon blood-serum. The bacilli stain more evenly, and numerous gigantic forms, second in size only to those grown on potato, are present.	The bacilli are distinctly shorter than the Klebs-Löffler bacillus. Segmented rods are fairly common, and there is a certain amount of clubbing to be noticed. The combination of clubbed and segmented forms is rare. The tendency of the bacilli to collect in small clumps is still present. At 4—6 days involution forms are common, and large numbers of unstained bacilli can be detected. Clubbed and segmented forms are common, and the only points of distinction from the Klebs-Löffler bacillus are that it is shorter, and is arranged in small groups.

GELATINE (7—10 PER CENT.).

Klebs-Löffler Bacillus.	*Xerosis Bacillus.*
MACROSCOPIC.	
Growth similar to that of the xerosis bacillus, but decidedly more vigorous. Colonies can be recognised in 12—24 hours.	This material, probably because it is incubated at a low temperature (18°—20° C.), does not form a good medium; no growth is visible to the naked eye under 48 hours. *Streak.*—In streaks the growth is scanty, opalescent, and nearly transparent, forming a thin dryish film, strictly limited to the needle track. Has a pearly lustre by transmitted light.
Stab.—Growth in the depths of the needle track is very scanty.	*Stab.*—In stabs, growth occurs in the depths of the needle track as small isolated spherical colonies, semi-transparent and slightly opalescent. The medium is not liquefied.
MICROSCOPIC, *at* 48 *hours* (see Plate XV, fig. 3).	
The bacilli differ in size from those grown upon serum in being distinctly shorter. The central portion stains well, and there is but little segmentation to be noted, and still less clubbing.	The bacilli are longer than those grown on any other medium. Some are straight, whilst the majority are slightly curved, and collected together in small groups. The staining, though never good, is even throughout, no segmentation or clubbing being observed.

BOUILLON.

MACROSCOPIC.

When cultivated in tubes both organisms grow well, and in about 24 hours give rise to a granular opacity of the medium. After 48—60 hours the broth again becomes clear, owing to the subsidence of the bacilli to the bottom of the tube.

Reaction in Neutral Broth.

When this is used the reaction gradually becomes acid, and is markedly so in 24—30 hours. After this the acidity slowly diminishes, and eventually the broth becomes strongly alkaline.	For the first 48 hours no change is observed in the reaction of the medium. After this time it is found to be faintly alkaline, becoming distinctly so in about 60 hours.

BOUILLON—*continued.*

Klebs-Löffler Bacillus.	*Xerosis Bacillus.*
Reaction in Alkaline Broth.	
When bouillon having a distinctly alkaline reaction is used, the amount of acid produced by the Klebs-Löffler bacillus is not only sufficient to reduce the reaction to neutrality, but also to render it distinctly acid.	Growth takes place rather more rapidly than in neutral broth, and after 36—48 hours the alkalinity is slightly increased.
MICROSCOPIC.	
The prevailing form is a short squat bacillus, about ·75 μ in length. A few elongated forms are seen, but these very rarely exceed 1·8 μ	The rods are short, ·75 μ in length—the breadth apparently varying with the stain—quite straight; no clubbed forms are to be seen; they still retain their tendency to collect in small groups.

MILK.

MACROSCOPIC.

The organisms grow equally well in this medium without producing coagulation.

Reaction.—The observations upon this point, described under the heading of Bouillon, apply to this medium also.

MICROSCOPIC.

The morphological characters of the two organisms grown in milk are similar to those described under bouillon.

POTATO.

MACROSCOPIC.

Usually invisible, or is indicated as a thin dry glaze after several days. In 24 hours, at 37° C., microscopic examination shows an abundant growth.	Usually invisible, or appears as a thin dry glaze at the end of 36—48 hours. On microscopic examination growth is very scanty, and dies in a few days.

POTATO—*continued.*

Klebs-Löffler Bacillus.	*Xerosis Bacillus.*
MICROSCOPIC.	
Enormous clubbed forms are present, and are of larger size and thicker than those formed on any other medium. The common segmented forms are few in number. Irregular shapes are particularly numerous, and small coccus-like bodies are also present.	At 48 hours the bacilli are very short, and there is a marked absence of clubbing. Segmentation is never observed. The organisms are arranged in pairs, end to end, and in groups of two or three such pairs, side by side, approaching in appearance more nearly to the short variety of the diphtheria bacillus. The xerosis bacillus stains badly and slowly, and numerous unstained organisms are noticed. At 60 hours none stain deeply—the majority are unstained.

The foregoing descriptions apply more particularly to the early generations of the xerosis bacillus. After subcultivating on blood-serum through a number of (say ten) generations, the organism becomes distinctly shorter and more slender, and more curved. The protoplasm stains evenly throughout the length of the bacillus, and neither clubbing nor segmentation is observed. Nor is the frequently mentioned characteristic "clumping" so well marked. The peculiarities which render the xerosis bacillus liable to be mistaken for the diphtheria bacillus, and which are lost when the organism is cultivated for many generations *in vitro*, can be restored by cultivating upon glycerine blood-serum (inspissated) for one or two generations.

Stains.—The xerosis bacillus stains well with all the aniline dyes, and is not decolourised by Gram's method. The stains giving, perhaps, the best results are carbol-methylene-blue and aniline gentian-violet. With the former, one frequently gets, especially in old (four to six days) agar cultures, remarkably good examples of metachromatism—portions of the organism being stained a deep blue, whilst others present a magenta tint. With the latter stain the bacillus appears somewhat thicker than when other dyes are used. The same peculiarity may be observed in staining the Klebs-Löffler bacillus with aniline gentian-violet. This may be due to the sheath also taking up the stain.

Temperature.—Undoubtedly the optimum temperature for the

growth of the xerosis bacillus is 37° C. Growth takes place up to 42° C. or 44° C.; beyond that temperature growth is inhibited. The thermal death point is reached at 58° C., an exposure to that temperature for ten to fifteen minutes being sufficient to kill the organism. Growth will also take place at 19° C., but is very feeble and slow. No growth whatever occurs below 15° C.

Vitality.—The length of time the organism will retain its vitality upon artificial media is very variable. The average time is about three to five weeks. I have succeeded in obtaining a growth when inoculating from a blood-serum culture four months old. I have also failed in the case of some cultures only three weeks old.

Inoculation experiments.—Guinea-pigs were inoculated with 48-hour broth cultures of the bacillus derived from each of the thirteen cases; the dose, irrespective of the weight of the animal, being 1 c.c. injected subcutaneously. At the end of the forty-eight hours a varying amount of œdema had appeared at the seat of inoculation. This lasted for two or three days, was then gradually absorbed, and in ten days nothing abnormal could be detected. The animals never refused food, nor seemed in any way inconvenienced by the introduction of the cultures into the subcutaneous tissue.

Animals were killed at intervals of one, two, and three months after inoculation, and beyond a slight cicatricial thickening at the seat of inoculation nothing could be found.

At varying intervals after the œdema had subsided, 48-hour broth-cultures of the Klebs-Löffler bacillus were inoculated subcutaneously. These invariably killed the animals in about three days, and all the characteristic *post-mortem* appearances due to this organism were present, viz.—

At the site of inoculation.—Extensive local œdema, due to a fibrino-purulent exudate (and in which living Klebs-Löffler bacilli may be demonstrated), associated with more or less hyperæmia and ecchymosis.

Serous cavities.—Excessive serous effusion in the peritoneal, pleural, and pericardial cavities.

Liver and kidneys.—These sometimes exhibit fatty degeneration in a most marked manner. (The heart muscle also shows this change, though but rarely.)

Supra-renals.—Enlarged and hæmorrhagic.

Spleen and lymphatic glands.—Swollen, reddened, and sometimes showing hæmorrhagic patches.

With regard to the possible production of a toxine by the xerosis bacillus, the following experiments were performed:

Flasks containing 100 c.c. of neutral bouillon were inoculated with xerosis bacilli from all the cases, and incubated at 37° C. for two months. The broth was then filtered through a Pasteur filter, and 1 c.c. of the clear sterile fluid inoculated snbcutaneously into guinea-pigs, weighing about 250 grms. On the following day some slight œdema was observed at the seat of inoculation. This cleared up in two days, and the animals were not further affected.

Control experiments with diphtheria toxine, prepared under the same conditions, were made with the result that ·5 c.c. killed a guinea-pig of the same weight in three days.

True Conjunctival Diphtheria.

As a contrast to the preceding cases, from which the xerosis bacillus was isolated, I now quote a recent case of true conjunctival diphtheria.

The patient was a boy aged 4 years. Both eyes were affected, the lids being painful red, and swollen, and could only be separated with difficulty owing to the brawny infiltration of the subcutaneous tissue. The ocular conjunctiva was chemosed; the palpebral portion congested and thickened, presenting patches of a pale greyish-yellow membrane, which stripped off easily, leaving a raw bleeding surface below. A thin milky-white discharge, slight in quantity, was also noted. Under treatment the symptoms rapidly subsided, but within a month of the disappearance of the membrane from the conjunctiva the child developed a well-marked and progressive paresis of the extensor muscles of the left forearm and hand

Bacteriological examination.—Cover-slip preparations made direct from the discharge revealed the presence of numerous polynuclear leucocytes and some squamous epithelial cells, whilst the bacteria present consisted of staphylococci and slender bacilli, about 1·75 μ in length, and presenting a beaded appearance when stained with carbol-methylene-blue. None of these bacilli were clubbed, and I was totally unable to decide from this examination whether the organism in question was the Klebs-Löffler bacillus or the xerosis bacillus.

A blood-serum tube was then inoculated with some of the discharge from the lower conjunctival fornix (left eye), and incubated

for sixteen hours at 37° C. At the end of this time a scanty growth was observed, consisting of several small, rounded, raised, opaque white colonies with sharp-cut edges, averaging 1 mm. in diameter, which microscopically consisted of the form of the Klebs-Löffler bacillus known as the long variety. At the end of twenty-four hours colonies of staphylococci were noted, and also an irregular growth of *B. subtilis* along the edges of the nutrient surface.

Inoculation experiment.—From the growth on blood-serum, agar plates were made, and a pure culture of the *B. diphtheriæ* obtained; from this latter a broth tube was inoculated, and after forty-eight hours' incubation at 37° C., 1 c.c. of the resulting growth was inoculated into the subcutaneous tissue of the abdomen of a guinea-pig weighing 258 grms. At the end of sixty hours the animal was dead, and a *post-mortem* examination demonstrated the presence of those pathological conditions associated with death due to the *B. diphtheriæ*.[1]

Differential Summary.

In differentiating the xerosis bacillus from the Klebs-Löffler bacillus we are saved all trouble in the case of first cultures by the fact that the former does not grow on blood-serum at 37° C. under thirty-six to forty-eight hours, whilst the latter makes its appearance in eighteen to twenty-four hours.

At the other extreme, with cultures some fifteen to twenty generations old, there is likewise very little difficulty in distinguishing between these two organisms, as the xerosis bacillus then appears as a much shorter, more slender and more curved bacillus, exhibiting neither segmentation nor clubbing.

But in the case of early sub-cultures from the first culture the circumstances are entirely altered, and we have to deal with an organism closely resembling, in its general characters and mode of growth, the Klebs-Löffler bacillus—an organism, moreover, which has no one single persistent peculiarity which will enable us to say definitely, this is the xerosis bacillus.

We have, therefore, to depend upon the sum-total of the cultural and morphological differences—minute in themselves—picked out

[1] To Dr. Washbourn my best thanks are due for his kindness in performing these inoculation experiments for me, and also for much valuable advice and assistance during the course of these experiments.

during the course of numerous observations. These differences have been indicated in the foregoing parallel descriptions in some detail, but to sum up broadly, the chief points of distinction between the xerosis bacillus and the diphtheria bacillus are as follows:

1. After inoculation from the secretion, upon blood-serum, colonies of the xerosis bacillus do not appear under thirty-six hours —those of *B. diphtheriæ* appear in sixteen to eighteen hours.

2. When grown in neutral bouillon or milk the xerosis bacillus never gives rise to an acid reaction—*B. diphtheriæ* invariably does so.

3. When grown upon potato the xerosis bacillus rapidly degenerates and dies—*B. diphtheriæ* grows with more vigour, and to a greater size than on any other medium.

4. When grown upon 10 per cent. gelatine, colonies of the xerosis bacillus are not visible to the naked eye under forty-eight hours—*B. diphtheriæ* colonies can be recognised in twelve to twenty-four hours.

5. The invariably innocuous nature of the bouillon cultures of the xerosis bacillus when inoculated into the subcutaneous tissues of animals susceptible to the *B. diphtheriæ*.

As to the exact nature of the xerosis bacillus—whether it be a non-virulent and slightly altered species of the *B. diphtheriæ*, or a totally separate and distinct bacillus—it is impossible at present to decide.[1] *December 17th*, 1895.

---

4. *Diphtheria and pseudo-diphtheria bacilli.*

By E. A. Peters, M.D.

In the bacteriological diagnosis of diphtheria certain difficulties are met with in distinguishing the bacillus which is the cause of the disease. Great confusion has been introduced on account of the use of the term pseudo-diphtheria bacillus in different senses by different authors. After the discovery of the Klebs-Löffler bacillus by Klebs and its further establishment by Löffler, Hofmann

[1] The expenses of the foregoing experiments were defrayed in part by a grant from the Scientific Grants Committee of the British Medical Association.

described a short bacillus as occurring in the throat in various conditions. He distinguished this from the Klebs-Löffler bacillus, and gave it the name of "pseudo-diphtheria bacillus." It was non-pathogenic to guinea-pigs.

Martin (1892) described three kinds of diphtheria bacilli:

1. Long, entangled forms.
2. Medium-sized bacilli, arranged parallel-wise.
3. Short, parallel bacilli.

He further remarks that the relative virulence of these forms varies with the length of the bacilli. The long form 1 is most virulent, while 3 is least so, leaving 2 intermediate in virulence.

Roux and Yersin, in their researches on diphtheria, found a large number of varieties of diphtheria bacilli, which differ from one another in virulence when tested by inoculation experiments. Some were non-virulent, and these they described as "pseudo-diphtheritic," but did not consider them to be morphologically distinct from the virulent varieties.

It has been my aim during the past two years to examine bacilli from cases suspected of diphtheria, and to cultivate them in various ways, with a view to determining the following points:—(*a*) Whether several varieties of the diphtheria bacillus exist, and if these show constant morphological differences. (*b*) The comparative virulence of these varieties. (*c*) The relation of Hofmann's to the diphtheria bacillus.

The material has been derived principally from Guy's Hospital, where, even in the out-patient department, suspicious cases are examined bacteriologically. Further, when holding the post of house physician to Dr. Frederick Taylor, I examined throats, normal and diseased. Dr. Washbourn supplied me with much material of importance from the London Fever Hospital. From this large amount of material I have selected any bacilli of apparent interest, and have submitted them to various tests.

The species I have been able to distinguish are—

1. Long pathogenic bacilli (typical Klebs-Löffler).
2. Short pathogenic diphtheria bacilli.
3. Short non-pathogenic bacilli (Hofmann's).
4. Long non-pathogenic bacilli, resembling No. 1 in morphological aspect.

The number of specimens of the above which have been examined all morphologically and some by inoculation, are—

1. Long Klebs-Löffler bacilli . . . over 100 cases.
2. Short diphtheria bacilli . . . . 6 cases.
3. Hofmann's bacilli . . . . over 30 cases.
4. Long non-pathogenic bacilli . . . 1 case.

The virulence of every one of these specimens was not tested, so that inasmuch as No. 4 differs from No. 1 chiefly in virulence, it is quite possible that some of the specimens included in No. 1 really belong to No. 4.

A. Morphology.

1. *Long Klebs-Löffler Bacillus.*

a. Cultivation on Coagulated Blood-serum at 39°. C.—Minute colonies can be recognised in ten to twelve hours; these increase in size, and will, when isolated under favorable conditions, grow to the diameter of $\frac{1}{10}$—$\frac{1}{5}$ inch in twenty to twenty-four hours, reaching the maximum for each colony of $\frac{1}{4}$—$\frac{1}{3}$ inch in three days. The colonies are of a deep opaque white, and are well raised above the surface of the medium; the surface of the colony appears dry and granular.

Microscopical appearances.—The bacilli vary in vegetative character. Thus some of the stocks will exhibit for a longer period the short forms which characterise young growths.

The dates given below are average.

Twelve hours.—The bacilli lie mostly parallel-wise, two, four, or six together. Each bacillus usually shows two aggregations,[1] and appears as if two elementary bacilli were joined end to end, though such segmentation is not to be distinguished. The elementary bacilli without aggregations measure 1·8 μ in length by ·8 μ. The bacillus is composed of a darkly staining unsegmented mass of protoplasm, covered by a well-developed sheath, which is slightly drawn out at one end. A few of the larger forms, which characterise an eighteen hours' growth, are present.

Eighteen hours.—The greater number of the bacilli are long, and stippled with aggregations, into two or many divisions; 4·5 μ is a common length for the bacilli. Many of these are clubbed at one or other end. There are a few squat, pear-shaped bacilli to be recognised, together with bacilli containing as many as twenty aggregations.

[1] In this paper the term "aggregation" is applied to the separation of the protoplasm of a micro-organism into the more darkly staining masses.

Thirty-six hours.—The protoplasm now appears collected into the swollen clubbed ends of the long and pear-shaped bacilli. These develop metachromatism with the aniline dyes to a more marked extent than occurs with the younger bacilli.

Seven days.—The greater number of the bacilli do not stain regularly, but large cocci-like masses stain deeply. These are either set free from the ghost-like unstained body of the old bacillus, or remain as parts of involuted bacilli. The forms are very numerous; they include top-like masses marked out with circularly staining bands, others resemble cocci; while a few huge bacilli still retain protoplasmic segments. The minute bacilli of the first twelve hours have entirely disappeared, and metachromatism is general.

b. Glycerine Agar at 37° C.—The long bacillus grows well on this medium. Its colonies appear in very much the same way, and after the same interval, as on blood-serum. The dead white colour is not, however, characteristic. In a *plate* cultivation the largest colonies are the aërial; those below the surface are lenticular or ovoid, and their size depends on their proximity to the surface.

1. By reflected light the appearances are very similar to those described in Section *a*.

2. By transmitted light under the microscope the colonies are seen to be finely granular and of a light brown colour. The edge is sharp, while the growing centre is darker brown and of some depth.

Microscopical appearances.—The bacilli grown on this medium are slightly different in appearance. The aggregations developed are very numerous, and the bacilli grow to an enormous size.

c. Alkaline Gelatine at 22° C.—A growth of the Klebs-Löffler bacilli appears on this medium in eighteen to twenty hours' time, and becomes considerable later. The bacilli attain to a less size on this medium, but are relatively coarser. The young unsegmented bacilli, however, are longer than the unsegmented forms of other media.

d. Peptone Bouillon at 37° C.—A cloudiness appears in the broth in twelve to eighteen hours, while a rather coarsely granular precipitate usually forms in thirty hours, leaving an upper stratum of nearly clear fluid. The reaction becomes more acid, and reaches its maximum acidity in three days' time, while a return to alkalinity is manifest in about five days' interval from the commencement of the culture.

The above results were obtained from broth prepared from fresh meat, to which peptone and salt were added before alkalisation with soda bicarbonate.

Microscopical appearances.—After exposure to a temperature of 37° C. for forty hours, numerous squat bacilli are formed, with a central dot of protoplasm. These are of nearly the same size as Hofmann's bacillus. A few longer forms (1·8 μ or more in length), however, distinguish the long Klebs-Löffler bacillus under these circumstances.

Three days.—In three days numerous segmented and clubbed forms, 1·8 μ, are developed. The formation of these short bacilli is due to the absence of aërobic conditions, probably to the diminished supply of oxygen, and not to the composition of the medium in question. If the bacilli are allowed to grow on sterile blotting-paper soaked in the medium, the long segmented forms, which are so characteristic of the growth on blood-serum and agar, are present in no small numbers in the scrapings from the blotting-paper.

Glycerine Broth.—*Microscopical appearances.*—Broth containing 5 per cent. of glycerine will produce bacilli of somewhat similar appearance, except that they exhibit increased metachromatism.

Five per Cent. Glycerine Blood-serum.—A culture of Klebs-Löffler bacilli on this medium at 37° C. brings out extremely well the metachromatic character of the protoplasmic masses. Involution forms are extremely well marked, as is also aggregation of protoplasm.

Milk.—Milk is not coagulated by the Klebs-Löffler bacillus, which thrives well in this medium. The bacilli are similar to those grown in glycerine broth.

Potato.—The bacillus grows well on an alkaline potato. The growth is not, however, obvious to the naked eye, except as an increased transparency of the surface. In old preparations it appears as a brownish powder.

Microscopical appearances (twenty-seven hours at 37° C.).—In twenty-seven hours the growth can be readily recognised microscopically as consisting of a few enormous clubs, often 10 μ in length. The clubs are larger than those formed on any other medium in the same time. The bacilli also form numerous cocci-like bodies, while the ordinary forms are few in number.

The comparison of this with Hofmann's bacillus thus grown exhibits striking differences.

ACID MEDIA.—The Klebs-Löffler bacillus does not grow on any acid medium.

ANAËROBIC CULTURE.—*a. Completely anaërobic.*—Durham's apparatus was employed, in which hydrogen is used, while the oxygen present is absorbed by pyrogallic acid and potash. Under these conditions the bacilli did not grow, and, after exposure for two weeks, young cultures have lost their power of growing on removal to the ordinary aërobic conditions.

b. Partially anaërobic.—In a partially anaërobic condition, which exists when agar is superimposed on cultures, or stab-cultures are made, some growth takes place, but this only to a slight extent.

As I mentioned above, growth in broth, which may be considered as partially anaërobic, results in the development of stunted bacilli. Accordingly it appears that the long Klebs-Löffler bacilli cannot grow under completely anaërobic conditions, while under partially anaërobic conditions the growth is diminished and the bacilli are stunted.

STAINING.—The young bacilli stain well with all the usual stains. Carbol methylene-blue is very convenient for the early forms, while it brings out the metachromatism of the older bacilli particularly well. The older forms, which lose their property of staining readily after three days' cultivation, are best treated with aniline gentian-violet. Gram's method stains the young bacilli, while the protoplasmic parts of the older bacilli are well picked out by this stain.

Pathogenesis.—The inoculations were carried out upon guinea-pigs.

All the inoculations, seven in number, in which this Klebs-Löffler bacillus was employed terminated fatally in twenty to forty-eight hours. A forty hours broth-culture was used in all cases, and 1 c.c. injected subcutaneously.

The usual *post-mortem* conditions of œdema, with hæmorrhagic supra-renals, and serous effusions resulted.

In the guinea-pigs which died early, œdema and serous effusion were unusual; these morbid conditions were found in those animals which died after a longer interval. One stock of this species, which had been kept *in vitro* for eighteen months, proved to be slightly more virulent than the primitive stock.

Persistence of the type.—I have been unable to permanently change this type in any way, though it has been grown under various conditions for two years. The short forms which develop on broth will, when transplanted to blood-serum, reproduce the bacilli which characterise an ordinary growth on this medium.

Vitality.—The actual vitality of this bacillus is less for an individual cultivation than in the case of either the short diphtheria, or Hofmann's bacilli. I have transplanted successfully from only one living culture which approached four months in age. In broth cultivations, kept in large flasks at 37° C., no growth results from a streak-culture made after the lapse of three months.

2. *Short diphtheria bacillus (pathogenic).*

The method of growth of this bacillus seems to be almost identical with that of the bacillus first described; and nearly all that has been said concerning the naked-eye appearances of the long Klebs-Löffler colonies will apply also to this bacillus. Frequently, however, the bacillus grows indifferently on gelatine.

Microscopically the two bacilli can always be distinguished if compared under the same conditions.

Microscopical appearances.—The bacillus is stained by Gram's method.

a. Blood-serum Growth at 30° C.—*Twelve to eighteen hours.*—The bacilli are similarly disposed to the Klebs-Löffler bacilli. The individual bacilli are, however, conical, the pointed end consisting of a sheath which does not stain readily, while the protoplasm is represented by a dark mass at the base of the cone. The unsegmented bacilli are 1·8 μ in length.

Eighteen hours.—At this period the largest number of the bacilli are still short and conical, and the numerous elongated forms of the true Klebs-Löffler bacilli are notably absent. There are a few elongated bacilli, and some also are clubbed. The former are usually half the length of the segmented bacilli described under No. 1; the aggregations of protoplasm are not so definite, and these bacilli are straighter than in the case of No. 1. Clubbing takes place, but the clubs are smaller, and a pointed sheath frequently projects at the end of an involution form.

Three days.—The bacilli have not increased in length. Clubbing and metachromatism have taken place, but altogether on a smaller

scale than in No. 1. These differences are noticeable in varying degrees on other media.

Pathogenesis.—The short diphtheria bacillus is undoubtedly pathogenic, but it will readily lose this property.

Inoculations from six different stocks were made in the same way as described under the heading of the long Klebs-Löffler bacillus, *i. e.* 1 c.c. of a forty-hours broth-culture was injected subcutaneously.

Stock 1.—The guinea-pig died in two days.

Post-mortem.—Locally there was found a patch of softened tissue with surrounding œdema. A culture made from this yielded a pure growth of the bacillus. The serous fluids were not increased. The supra-renals proved to be hæmorrhagic.

One year after another guinea-pig was inoculated in a similar way. Slight œdema appeared next day. This soon resolved, and the animal recovered.

The experiment was subsequently repeated with the same result.

Stock 2.—A similar inoculation was made. The guinea-pig died in four days.

Post-mortem.—Local œdema containing bacilli. Pericardial, pleuritic, and peritoneal fluids increased. Enlarged and hæmorrhagic supra-renals.

Stock 3.—After a similar inoculation a guinea-pig died in thirty hours.

Post-mortem.—Local œdema. Pleuritic and peritoneal effusion. Hæmorrhagic supra-renals.

Stock 4.—Another guinea-pig was inoculated in a similar way and died in two days.

Post-mortem.—Marked local œdema extending over the thorax. Pleuritic and pericardial effusion. Hæmorrhagic supra-renals.

Variation of this type.—One stock of this bacillus has been in my possession for two years. It has never changed to the morphologica aspect of No. 1 (long Klebs-Loeffler bacillus), though cultivated through many generations.

The stock, though at first virulent to guinea-pigs, has completely lost this property (see Stock 1).

Lately, this bacillus, which at first showed practically no change in morphology, has become smaller, and, though still differing, bears some resemblance to Hofmann's bacillus; it can still be distinguished from this latter species.

I am pursuing further experiments under this heading.

Vitality.—This bacillus retains its vitality for ordinary cultivations for a longer time than No. 1. Thus cultivations are still found to be living at the end of four months. Broth-cultivations three months old yield sub-cultures.

3. *Hofmann's bacillus, or the short pseudo-diphtheria bacillus (non-pathogenic).*

a. Coagulated Blood-serum at 37° C.—The young colony of this bacillus cannot readily be distinguished by the naked eye from those of Nos. 1 and 2. The limits in size and rate of growth of the colonies follow nearly the same lines.

The old colonies are characterised by a prominent growing centre, while the surface is smooth and white. Besides this, the growth is not so dead white as in Nos. 1 and 2.

Microscopical appearances.—This bacillus differs considerably from the above-described bacilli, both in its shortness and uniformity of size.

Twelve hours.—The bacilli at this period are arranged similarly to Nos. 1 and 2, but there are extremely few long forms present. The elementary unsegmented bacilli are squat and small; a sheath passes all round the bacillus, but it is not prominent at any point. The bacilli measure $\cdot 9\,\mu \times \cdot 4\,\mu$.

Eighteen hours.—The bacilli have altered little, and keep the same disposition for several days. The greater number of the bacilli have two aggregations, and appear as if two elementary bacilli had joined end to end. This appearance is probably due to aggregations of protoplasm in a single bacillus.

Twenty-four hours.—Some of the bacilli become slightly swollen. This enlargement is usually restricted to one aggregation of the doubly segmented bacilli.

A few elongated bacilli with many aggregations and slightly clubbed forms may now be noticed; a very small number were to be seen in still earlier growths. They rarely exceed $3 \cdot 5\,\mu$ in length.

Three days.—In older preparations the small swollen forms are frequent. The extensive clubbing which characterises preparations of this age in Nos. 1 and 2 is almost absent.

These bacilli retain their staining properties for some time longer than Nos. 1 and 2.

Metachromatism is rarely present.

b. GLYCERINE AGAR GROWTH AT 37° C.—The growth cannot be distinguished macroscopically from Nos. 1 and 2. It is usually slightly greater. The bacilli are rather larger than those grown on blood-serum, but the appearances are otherwise similar. Old agar preparations become brown, a point first noticed by Escherich.

c. GELATINE (ALKALINE) AT 22° C.—The growth under these conditions is rather in excess of that of Nos. 1 and 2. The colonies of the three types cannot be distinguished by the naked eye; with the microscope the same relative differences will be found to exist as on the other media. The bacilli are larger and coarser than on other media.

d. ALKALINE PEPTONE BROTH AT 37° C.—The phenomena connected with this growth show three points of difference from No. 1:

(1) The broth does not become so soon cloudy.

(2) The precipitate formed is usually more finely granular.

(3) A slight reaction to the acid side results before the marked alkalinity of the late stage. The acidity mentioned is not so intense as in No. 1.

Forty hours' broth.—The bacilli are similarly arranged, and are also of the same shape and character, but are decidedly smaller than on blood-serum preparations.

Three days.—A few swollen forms and an occasional aggregation bacillus are noticed, but the production of these is small as compared with No. 1.

e. GLYCERINE BOUILLON, 5 PER CENT.—Slight metachromatism is observed with this medium.

f. GLYCERINE SERUM, 5 PER CENT. (COAGULATED).—Colonies grown on this show more aggregation and clubbed forms than on any other medium.

Metachromatism is also present to a slight degree, especially in old specimens.

g. MILK.—Milk is not coagulated by the bacilli, which grow in very much the same form as in glycerine bouillon.

h. POTATO (ALKALINE).—*Twenty-seven hours at* 37° *C.*—The bacilli grow very well, and present the form which obtains on other media. A few aggregation and swollen bacilli are observed, but these are rare, and very small when compared with the gigantic clubs of No. 1. The bacillus is stained by Gram's method.

Pathogenesis.—All the experiments show that Hofmann's bacillus is non-pathogenic.

Thirteen guinea-pigs were inoculated from various stocks. 1 c.c. of forty hours' broth-culture was the dose in every case. Not one died from the inoculation, nor was œdema marked in any case. Further, there is evidence that no toxin is produced.

Seventeen c.c. of filtered broth-culture, which had grown one month at 37° C., were injected subcutaneously into a guinea-pig. The animal was well for one month afterwards.

Persistence of this type.—I have cultivated Hofmann's bacillus for two years, and have found it to alter very little in morphological character. The medium in which it varied most in my hands was glycerine blood-serum. On this medium, forms 3·5 μ in length, with the protoplasm collected into aggregations, became quite numerous with one stock.

This stock is non-pathogenic.

Vitality.—This bacillus retains its vitality, under ordinary conditions of growth, for a longer time than either of the above bacilli.

Fresh cultures can readily be prepared from culture tubes four months old.

4. *Long non-pathogenic bacillus.*

This resembles the long Klebs-Löffler bacillus. Clubbing is, however, not so well marked, nor is the segmentation so definite. It is non-virulent to guinea-pigs in dosage of 1 c.c. of a forty hours' broth-culture, inoculated subcutaneously.

The resemblance of this to the long pathogenic bacillus is extremely close, except in its non-pathogenesis.

The two bacilli show in this respect a marked contrast.

B. Clinical.

1. *The long Klebs-Löffler bacillus* in my experience has been found in all cases of typical diphtheria which I have examined bacteriologically, and also in some cases in which the nature of the lesion and symptoms were not so clear.

2. *The short diphtheria bacillus* in my experience is rare. I have met with it in only six cases.

a. The short diphtheria bacillus was found in the throat of a

nurse in charge of diphtheritic patients. The nurse was enjoying good health, and was in no way inconvenienced by the possession of this bacillus, although 1 c.c. of a broth cultivation was fatal to a guinea-pig in forty-eight hours. This stock is now two years old, and has lost its virulence.

b. The second specimen was procured from a case of mild laryngeal diphtheria which made a good recovery.

c. The third stock came from the throat of a boy which was simply in a catarrhal state. The patient had been indisposed for two weeks. At the time of examination he felt quite well, and was walking about. A few cases of diphtheria had occurred in the school previous to the bacteriological examination, and subsequent to the commencement of his sore throat.

d. Another specimen was derived from a case in which there was membranous exudation on one tonsil, which had commenced to infect the posterior pillar of the fauces on that side.

The case was not a severe one.

Two other stocks were procured, one from a case at the London Fever Hospital, in which a diagnosis of diphtheria was not justified on clinical grounds. The other specimen had been sent for diagnosis, and no details of the case are to hand. Cases *a* and *c* have been described by Drs. Washbourn and Goodall in the 'British Medical Journal.' This bacillus, then, appears to cause mild diphtheria, and is probably infective.

3. *Hofmann's, or the short non-pathogenic bacillus.* *a.* NORMAL THROATS.—Twenty-five throats were examined in the usual way; the resulting cultivations were devoid of Hofmann's bacillus.

b. ANGINA.—It is common to meet with this bacillus in cases of sore throats with enlarged and catarrhal tonsils. Symptoms of laryngitis may also be present. I met with four such cases during six weeks at Guy's Hospital. The following is a typical case:

A. B—, aged 6 years; has been ill three days. The child is pallid; temp. 101° F. Enlarged tonsils and glands.

A bacteriological examination showed only Hofmann's bacillus.

Out-patient treatment was instituted, and resulted in recovery in two days.

c. FOLLICULAR TONSILLITIS.—I have examined eight severe cases

of this disease. In all of these the infection was relegated to the tonsils only. A small slough had usually appeared on one of the affected tonsils. In half the cases staphylococci were found, while an association of Hofmann's bacillus with staphylococci characterised the other four cases. These cases readily recovered with ordinary out-patient treatment. The disease did not spread from any of these cases to my knowledge.

d. MEMBRANOUS PHARYNGITIS.—I have found the bacillus unaccompanied by the Klebs-Löffler bacillus in only one case of this disease.

The membrane was thick and mucoid; it was not detached by coughing. This membrane persisted for three days. Three cultivations were made, and Hofmann's bacillus was present in each culture tube.

The case was mild, and the patient, an adult, made a good recovery.

e. LARYNGITIS.—Two cases in which this lesion was present have come under my notice. From both of these Hofmann's bacillus was procured in large quantities. The cases had both been treated with antitoxin. In one instance mucoid membrane was ejected in considerable amount—a circumstance which suggests ætiology to those who recognise clinically membranous laryngitis.

f. ULCERATIVE STOMATITIS.—Two children, aged respectively four and six years, presented themselves with this complaint on two consecutive days; they lived in the same block of industrial buildings.

Hofmann's bacillus was present, besides many other organisms, in both cases.

g. SCARLET FEVER.—Three undoubted cases of this disease, in which early angina was well marked, yielded profuse growths of Hofmann's bacillus on bacteriological examination of the fauces.

h. RÖTHELN.—Two cases of this disease were examined bacteriologically in Guy's Hospital.

Cultivations from the throat gave almost pure growths of the bacillus.

i. IN DIPHTHERIA, in association with the Klebs-Löffler bacillus.

This association is frequent. In some cases the bacilli apparently grow side by side, while in others one bacillus is relegated to one part of the track only.

Accordingly the two practical points to be observed in making

cultivations are, firstly, to insure that the source from which cultivations are made is either the glottis or larynx, in cases suspected of primary laryngeal disease, where no membrane is obvious; and secondly, to examine a large number of colonies where Hofmann's bacillus alone has been recognised.

The following case illustrates these remarks.

E. D—, Cot 56, Mary Ward. Admitted on the third day of illness for diphtheria with laryngeal obstruction. Temp. 101° F. Enlarged glands, tonsils swollen and red. Albuminuria. Obstructive laryngitis.

TREATMENT.—Tracheotomy and antitoxin.

Cultivations.—(1) From trachea: long Klebs-Löffler and Hofmann's bacilli. (2) From tonsils: Hofmann's bacilli.

Sixth day of illness.—Fever subsided, and tracheotomy tube removed.

Thirteenth day.—Nasal discharge; otherwise well.

Cultivations.—(1) Nasal: Hofmann's bacilli. (2) Tonsillar: Hofmann's bacilli.

Eighteenth day.—Temperature rose to 101° F. Antitoxin rash. Nasal discharge ceased.

Cultivations.—From tonsillar region: long Klebs-Löffler and Hofmann's bacilli.

Twenty-first day.—Child has quite recovered. Neither of the bacilli was found present in subsequent cultivations.

j. CHRONIC CORYZA AFTER DIPHTHERIA.—It is usual to find Hofmann's bacillus in these cases.

A boy aged 5, on whose throat the long Klebs-Löffler bacillus had been found in the acute attack, after subsidence of the symptoms was affected with a chronic catarrh of the fauces and nose. Repeated cultivations were made over a period of two months. Hofmann's bacillus alone was found.

The cases affected with Hofmann's bacillus unassociated with diphtheria bacilli, which have come under my notice, have always recovered. Drs. Washbourn and Goodall assure me that all cases of throat affection in which this bacillus alone is found are always mild.

Hofmann's bacillus does not follow the long Klebs-Löffler bacillus by rote in diphtheria.

Five cases in which the long Klebs-Löffler bacillus had been

found were investigated. Four or more cultivations were made in each case. In not one of these cases were Hofmann's bacilli found. A few observations on throats acutely affected with Hofmann's bacilli show that the disappearance of the bacillus is normally rapid.

The clinical aspect of Hofmann's bacillus is—

(*a*) Wide-spread occurrence in various catarrhal conditions in which the causal relation is unknown.

(*β*) Mild type of affection.

(*γ*) The bacillus, though frequently co-existent with, does not follow the long Klebs-Löffler by rote.

4. *The long non-pathogenic bacillus* closely resembles the long Klebs-Löffler bacillus.

The stock which came into my possession was procured from the throat of a friend who was subject to chronic faucial catarrh.

Conclusions.

a. There are two morphological species of pathogenic diphtheria bacilli:

1. The long Klebs-Löffler bacillus.
2. The short diphtheria bacillus.

The main *points of difference* are—

(*a*) *Morphological.*—The two bacilli can be readily distinguished in spite of certain resemblances. The short bacillus has greater vitality.

(*β*) *Clinical.*—The short diphtheria bacillus is found in mild cases, while No. 1 occurs in typical cases of diphtheria.

(*γ*) *Immutability.*—I have not been able to convert one species into the other. Each individual has kept for two years its special morphological characters, except for some change in the short diphtheria bacillus which had become non-pathogenic. This slight alteration in morphology was directed towards Hofmann's bacillus. (Further experiments on these points are being carried on by means of serum immunisation.) There is also a non-pathogenic bacillus closely resembling No. 1, but rare of occurrence,—No. 4.

b. *Virulence.*—Both species Nos. 1 and 2 are virulent when obtained from the throat. The long Klebs-Löffler bacillus retains its virulence, while the short diphtheria bacillus loses this property.

c. The relation of Hofmann's bacillus to the diphtheria bacillus is clear on certain points.

(*a*) Hofmann's bacilli resemble the diphtheria bacilli especially in mode of growth, and slightly in microscopical characters. (*β*) The cases in which it is found may be mistaken for mild diphtheria. The prognosis in such cases is good. (*γ*) There is no proof forthcoming that this bacillus is an attenuated form of the diphtheria bacillus, though the short diphtheria bacillus, when it becomes non-pathogenic, tends to resemble Hofmann's. The practical application of these details to diagnosis and prognosis are of some importance, and easy to carry out.

The inoculation experiments were conducted by Dr. Washbourn. My best thanks are due to Dr. Goodall and other gentlemen who have so kindly assisted me in this research, and especially to Dr. Washbourn, without whose advice and aid this paper could not have been written.

Drs. Frederick Taylor and Cooper Perry have kindly allowed me to publish details of cases under their care.

December 17th, 1895.

---

5. *Diphtheria bacilli in a cultivation from the throat twenty-two weeks after the primary attack; bacilli markedly virulent.* (*Card specimen.*)

By R. T. Hewlett.

A schoolboy aged 15 was attacked by diphtheria at the beginning of June, 1895, and cultivations showed the presence of the Klebs-Löffler bacillus on June 5th. Convalescence commenced June 9th. Further cultivations on June 19th and June 26th still showed the presence of the bacillus, but on July 17th it was not found. From thence until October no examinations were made, but before readmission to school an examination was requested, and the Klebs-Löffler bacillus was again found on October 10th, and subsequently also on October 16th and 31st and November 11th. On November 18th and 27th and December 13th careful examination failed to reveal the presence of the bacillus.

Three 500 grm. guinea-pigs inoculated on October 25th with 1 c.c.,

0·5 c c., and 0·25 c.c. respectively of a forty-eight hours' broth cultivation of the bacillus isolated from the October 16th specimen died in thirty-six hours with the characteristic lesions. The bacilli were therefore markedly virulent.

Although the Klebs-Löffler bacillus was not found on July 17th there can be little doubt that it was present throughout, for the boy continued in good health after convalescence from the primary attack.

Thus the Klebs-Löffler bacillus was present in this case altogether for a period of over twenty-three weeks, and for about twenty-two weeks after the commencement of convalescence, and at nearly the end of this period it was markedly virulent.

February 4th, 1896.

---

6. *The escape of diphtheria bacilli into the blood and tissues.*

By A. A. Kanthack and J. W. W. Stephens.

While bringing the following observations[1] before the Society, we are conscious that the escape of the diphtheria bacillus into the blood, tissues, and organs more or less distant from the seat of infection, has already been made the subject of careful investigation by others, especially by Continental and American writers. In this country, however, the researches bearing on this question have received but little attention, although it is one both of theoretical and practical importance. We venture, therefore, to give a short review of our own observations. Before doing so we shall briefly consider the work already done.

Wright,[2] of Boston, in a long and exhaustive paper, embodying a large amount of work, states that in fourteen fatal cases he found, by cultivation on blood-serum, diphtheria bacilli—

[1] To make our observations complete, we have incorporated in this paper several cases which have occurred since this communication was made.

[2] 'Boston Med. and Surg. Journ.,' October, 1894.

In the lungs 13 times;
In the cervical or bronchial glands 5 times;
In the liver 3 times;
In the spleen twice;
In the mesenteric glands twice;
In the heart's blood once;
And in the kidney once.

He also notices the escape of the bacillus into the stomach and œsophagus. Since then Wright has published another paper in conjunction with Stokes,[1] from which we gather that in 31 fatal cases of diphtheria, which apparently include the above 14 cases, the Klebs-Löffler bacillus occurred—

In the lungs 30 times;
In the kidney 6 times;
In the lymphatic glands often;
In the liver 9 times (this viscus was examined in 29 cases);
In the spleen 5 times;
In the heart's blood and in other regions occasionally.

Frosch[2] had demonstrated the presence of the diphtheria bacillus by means of cultivation in the internal organs in 10 out of 15 fatal cases, most frequently in the broncho-pneumonic foci, in the spleen, the cervical and bronchial glands. Kolisko and Paltauf[3] found it in the spleen; Schmorl[4] in the cervical glands in 7 cases out of 10; Booker[5] separated it from the spleen, submaxillary gland, lungs, and heart's blood in a single case examined. Johnston[6] examined a single case and found it in the lungs, while Strelitz[7] saw it in the lung in 1 case out of 8, and Flexner[8] in 1 case out of 2. Kutscher[9] was able to demonstrate the diphtheria bacillus microscopically in lung sections, and in part by means of cultivations in 8 cases out of 9 examined, and once also in the kidney and in the liver; and Canon[10] found it repeatedly in cadaveric blood.

[1] 'Boston Med. and Surg. Journ.,' March 21st, 28th, and April 4th, 1895.
[2] 'Ztschr. f. Hyg.,' Leipzig, Bd. xiii, s. 1893.
[3] 'Wien. klin. Wochenschr.,' 1889.
[4] 'Schmidt's Jahrb.,' Leipzig, Bd. ccxxxvii, p. 110.
[5] 'Arch. Pediat.,' New York, 1893, vol. x.
[6] 'Montreal Med. Journ.,' September, 1891.
[7] 'Arch. f. Kinderh.,' Stuttgart, 1891, Bd. xiii.
[8] 'Johns Hopkins Hosp. Bull.,' Baltimore, 1893.
[9] 'Ztschr. f. Hyg.,' Leipzig, Bd. xviii, s. 175.
[10] 'Deutsche med. Wochenschr.,' Leipzig, 1893, s. 1039.

Recently Stokes[1] has examined 9 fatal cases of diphtheria which had been treated with antitoxin, by means of cultures taken on serum from the lung, spleen, kidney, and heart's blood. In all cases the *B. diphtheriæ* was found in the lungs, in 4 cases also in the kidney, in 1 case in the spleen, and in another in the heart's blood. To this last we must add the observations made by Sims Woodhead,[2] to which he alluded in last year's discussion on diphtheria. "So far as he could make out from his notes of about 50 *post-mortem* examinations, in only 5 instances had he been able to find the bacillus in the lung." At the same meeting one of us[3] showed microscopic sections from 2 cases, exhibiting the presence of the Klebs-Löffler bacillus in the smallest bronchioles and in the bronchopneumonic foci.

It is evident, then, that in fatal cases of diphtheria the escape of this bacillus from the seat of infection is by no means uncommon, and that the general statement that "the *Bacillus diphtheriæ* is found in the false membrane and in the membrane alone," and that "it does not enter the lymphatic or blood stream,"[4] is by no means correct.

1. Passing now to our own observations, which were begun in January, 1895, we have found that in the cervical and bronchial lymphatic glands diphtheria bacilli are often found in fatal cases. Unfortunately we kept no regular account of the frequency of the secondary lymphatic infections, and cannot therefore give a figure; but we venture to say that it is of common occurrence.

2. In twenty-six recent fatal cases we carefully examined the lungs for the presence of diphtheria bacilli; of earlier cases no systematic consecutive examination was made, so that these must be disregarded for statistical purposes. Films were always made and stained with aniline-gentian-violet, and cultivations on a special form of serum agar-agar were employed. In all these twenty-six cases diphtheria bacilli were obtained with ease and in large numbers, and in most cases it was not difficult to detect them in the films.

3. In four of these twenty-six fatal cases the spleen had not been examined; in a fifth case the agar-agar had been insufficiently sterilised, but in the remaining twenty-one cases it contained diphtheria bacilli in ten instances. For the purpose of separating the

[1] 'Boston Med. and Surg. Journ.,' December 12th, 1895.

[2] 'Trans. Path. Soc.,' London, 1895, vol. xlvi, p. 311. [3] Ibid., p. 304.

[4] Sidney Martin, 'Rep. Med. Off. Privy Council,' London, 1892–3, p. 425.

bacillus from the spleen the surface of the organ was cauterised with a red-hot glass rod, and with a platinum loop a little pulp was removed, and two to four tubes inoculated therewith.

4. The kidneys were examined for the presence of diphtheria bacilli on three occasions; the bacilli were discovered twice.

The serum agar-agar which we use is prepared with ascitic, pleuritic, or hydrocele fluid, to which we add enough caustic potash to prevent it from coagulating on boiling. We then mix this alkaline fluid with agar-agar (1·5 to 2 per cent.), and boil it up in the ordinary way, and finally after filtration add to the clear agar-agar 5 per cent. glycerine. This is by far the best medium for the separation of the diphtheria bacillus with which we are acquainted. Its mode of preparation has recently been published.[1] We consider that our results are greatly due to the possession of a good selective nutrient medium.

We see, then, from these results that the diphtheria bacillus escapes most readily into the lungs, and is there present in large numbers,—for, contrary to Frosch and Wright, for the purpose of cultivation we used small quantities of material for inoculation; and we cannot follow Stokes in his argument that in these situations the bacilli are only found in small numbers, for if we remember that every platinum-loopful spread on the agar-agar generally gave rise to numerous colonies, it must be evident that the whole organ contained an appallingly large number of diphtheria bacilli. On comparing our figures with those obtained by Kutscher, Wright, and Stokes, we find a pretty close agreement so far as the lungs are concerned, for they obtained bacilli from the lungs in forty-seven out of forty-nine cases, while we obtained them in all our twenty-six cases. It is evident, then, that in fatal cases of diphtheria the specific organism is very frequently indeed found in the lungs; if we add our cases to those described by the Americans, in sixty-five instances out of sixty-six. We should mention, however, that although Wright says in the summary of his first paper that the lungs contained the Klebs-Löffler bacillus in thirteen out of fourteen cases, from his published notes we could only collect twelve cases which showed the diphtheritic infection in the lungs, so that possibly there is an omission somewhere in his notes.

We must now examine the *post-mortem* conditions of the lungs in these cases more closely.

[1] 'Lancet,' London, 1896, vol. i, p. 835.

(*a*) In Wright's thirteen cases of diphtheritic lung infection, described in his first paper, *broncho-pneumonia* existed in ten, in our cases in fifteen; so that we must take exception to the statement frequently made that the broncho-pneumonia in diphtheria is of pyococcal, or more especially of streptococcal origin. In most cases it appears to be a direct diphtheritic complication.

In those cases which macroscopically presented nothing abnormal, possibly subsequent histological investigation would show either the earliest stages of broncho-pneumonia or the changes of so-called capillary bronchitis.

Another point which our observations bring out is the fact that acute broncho-pneumonia complicating diphtheria is not necessarily or even generally a foreign infection. There is a distinct tendency amongst bacteriologists to regard the streptococcus more than any other organism as the cause of such broncho-pneumonia. This view seems to us to be as harmful as it is incorrect.

(*b*) The next point to be considered is the nature and type of the diphtheritic lesion. We find that in Wright's thirteen cases above mentioned it extended into the larynx in nine cases, and in our twenty-six cases twenty-four times. It further appears that broncho-pneumonia is most frequently associated with membrane in the larynx, for in thirteen out of the twenty-four laryngeal cases of ours there was broncho-pneumonia; in the other eleven cases the lung is described in five cases as natural, in five as collapsed, in one as tubercular. In one case there was broncho-pneumonia, but neither during life nor *post mortem* was there membrane either in the fauces or in the larynx, but diphtheria bacilli were readily obtained after death from the mucous membrane of the trachea, so that probably this case also was one of laryngeal diphtheria. Amongst the nine cases of laryngeal diphtheria incorporated in Wright's paper broncho-pneumonia was found after death in six, in the other three cases the lung is described in one case as containing an infarction, in another as ecchymosed, and in the third as congested.

(*c*) Tracheotomy had been performed in eighteen out of our twenty-six cases, in one of these after previous intubation.

In Wright's cases no mention, unfortunately, is made regarding this point. In twelve of our tracheotomy cases there was also broncho-pneumonia, but from the clinical history we cannot possibly accuse the operation of being the cause of the lung affection, because in most cases the tracheotomy was an emergency operation, since the

children were generally admitted in a dying or serious condition. So far as we have been able to obtain detailed notes we find that in most instances tracheotomy was performed on, or soon after, admission, and that the patients rarely survived the operation longer than one to three days.

From our own experience, then, we cannot agree with Sims Woodhead in the assumption that micrococci in the pneumonic patches are most frequently associated with tracheotomy. In all fairness to Dr. Woodhead it should be remarked, however, that he makes this statement with due reservation.

That the broncho-pneumonia is not caused by the tracheotomy is further shown by the fact that in three cases there was broncho-pneumonia without a previous tracheotomy, and in one of these there was membrane in the trachea.

Again, we have six cases of tracheotomy without obvious broncho-pneumonia. Hence, judging from our own observations, we come to the conclusion that the broncho-pneumonia which is so frequently met with in fatal cases of diphtheria is often, if not generally, of diphtheritic nature, and is, as a rule, associated with or preceded by laryngeal diphtheria. We are quite aware of the fact that the Klebs-Löffler bacillus is never found as a pure growth in the lung, and that it is generally accompanied by streptococci and other micrococci. These organisms, however, are also found at the primary seat of infection, and are there only of secondary importance; and there is no reason why in a broncho-pneumonia where the diphtheria bacillus is present in large numbers they should be of greater importance. Moreover it must be kept in mind that staphylococci, pneumococci, and streptococci are normal inhabitants of the bronchi, bronchioles, and alveoli, and therefore on cultivation must of necessity appear on the agar-agar surface. Microscopically the diphtheria bacilli can frequently, if not generally, be seen in the alveolar spaces. Since our own histological investigations are as yet incomplete, we are compelled to speak with some caution.

Wright and Stokes agree with us that the broncho-pneumonia of diphtheria may be due to the diphtheria bacillus, with or without the association of streptococci, staphylococci, and pneumococci. In nineteen cases of broncho-pneumonia complicating diphtheria they found the *B. diphtheriæ* alone in eight; together with the streptococcus in five; together with the streptococcus and the staphylococcus aureus in two; together with the streptococcus, pneumococcus, and

staphylococcus aureus in one; together with the staphylococcus aureus in one; together with the streptococcus and pneumococcus in one; and the streptococcus alone in one case. On the other hand, as we also observed, the *B. diphtheriæ* may be found with or without these micrococci, apparently without there being any broncho-pneumonia.

In our studies a small platinum-loopful is removed from the lungs and smeared over the surface of the agar-agar, and the fact that numerous or even any diphtheria bacilli colonies are obtained must mean that the lungs are crowded with them, and that the amount of toxines produced in them must be enormous. We shall return to this point.

(*d*) *Spleen.*—Wright succeeded in finding bacilli in the spleen in two cases out of fourteen. In five cases the condition of the spleen *post mortem* is described as one of acute congestion, but in the two cases where the bacilli were found no remark is made as to its condition.

In one of these cases bacilli were also present in the lungs, though in the other case the examination of the lungs gave negative results. Wright and Stokes, adding all their cases together, found the diphtheria bacillus in the spleen in six out of forty cases.

In our twenty-six cases bacilli were found in the spleen in ten cases, in four of the remaining sixteen cases no examination was made, and in one the examination was unsuccessful on account of insufficient sterilisation, so that we may say that bacilli were looked for in twenty-one cases and found in ten. (This result, differing from that of Wright and Stokes, we think may be due to chance, or to the use of our particular serum agar-agar.) The condition of the spleen is not noted in fifteen cases, and is of little importance. We find, further, that the presence of bacilli in the spleen is associated in all these cases with the presence of bacilli in the lungs, and that in 70 per cent. there was broncho-pneumonia.

We conclude, therefore, that in fatal cases of diphtheria the Klebs-Löffler bacillus is far more frequently found in the lungs and spleen than is generally supposed; in the lungs, indeed, it is almost always present in large numbers. We do not venture to generalise from these observations, which cannot be considered numerous; but if we add to them those of others, especially those of Wright and Stokes, they gain considerably in importance, and go far towards proving our thesis "that in fatal cases there is an extensive escape of the

diphtheria bacillus into the lungs and other organs," that is, "that in fatal cases the diphtheritic infection readily becomes general."

If we now review all the facts in our possession we find that—

1. The diphtheria bacilli may escape from the original seat of infection by direct transference,—as, for instance, when we have cutaneous diphtheritic sores during the course of diphtheria. We have had two such cases at St. Bartholomew's Hospital, where children admitted for very severe diphtheria also presented several cutaneous membranous sores on the face and on the neck, in which the Klebs-Löffler bacillus was readily found. Wright also describes several such cases.

2. The bacilli may escape along existing passages from the seat of infection—

(*a*) To the nose;
(*b*) To the eyes;
(*c*) To the ears;
(*d*) To the pharynx and œsophagus;
(*e*) To the stomach and intestines;
(*f*) To the trachea, bronchi, bronchioles, and lung alveoli.

3. The bacilli may escape from the seat of infection along the lymphatics—

(*a*) Into the cervical glands;
(*b*) Into the bronchial glands.

4. The bacilli may escape from the primary or secondary seat of infection through the circulation—

(*a*) Into the blood (heart);
(*b*) Into the spleen;
(*c*) Into the liver;
(*d*) Into the kidney.

The occasional presence of the bacilli in the mesenteric glands may be explained in various ways. They may have escaped there either—

(*a*) Through the circulation; or
(*b*) From the stomach or intestines, infected secondarily; or
(*c*) Through the digestive tract, having been swallowed, without leading to a secondary infection.

Wright, Abbott and Ghriskey,[1] and Zarniko[2] have recorded animal experiments which clearly establish the possibility of this

[1] 'Johns Hopkins Hosp. Bull.,' Baltimore, April, 1893.
[2] 'Centralbl. f. Bakteriol. u. Parasitenk.,' Jena, 1889, Bd. vi.

bacterial escape, although, as our experiments also show, it does not seem to be of frequent occurrence.

Thus Wright finds the diphtheria bacillus amongst inoculated animals—

In 155 livers, nineteen times;
In 152 spleens, fifteen times;
In 153 blood examinations, seven times; and
In 151 kidneys, four times.

Abbott and Ghriskey demonstrated that in exceptional instances diphtheria bacilli, when deposited under the skin of smaller animals (guinea-pigs), may be found in the lymphatic apparatus of the omentum, and that when the injections are made into the testicles of these animals they are also found in masses in the omental lymph spaces of three out of four animals inoculated. To these experiments also must be added those of Klein,[1] who has shown that on inoculalating milch cows subcutaneously, diphtheritic lesions may appear in distant areas and diphtheria bacilli may escape with the milk.

Our own experiments on this point are far from complete, and we shall therefore, for the present, abstain from any criticism of these observations of others.

We now pass to the final conclusions, which we venture to draw from these investigations.

1. They have first a direct bearing on the process of intoxication in diphtheria. Sidney Martin [2] explains this process in the following manner. His major premise is that the diphtheria bacillus is not found beyond the membrane or primary seat of infection. Here a ferment or enzyme-like substance is secreted or formed by the bacilli—a substance possessing strong proteolytic action. This body is absorbed into the blood and tissues, and by virtue of its digestive action on the tissue proteids leads to the formation of specific toxic albumoses—the diphtheria albumoses; so that, then, according to him, the primary ferment-like product of the bacteria is not the actual toxine, but the intoxication is brought about by the albumoses and organic acid called into existence by this ferment. This view is based on the observation, that from the blood and organs, and specially from the spleen of children who have succumbed to diphtheria, large quantities of albumoses can be obtained, which, when injected into the rabbits, produce most striking diphtheritic

[1] 'Rep. Med. Off. Privy Council,' London, 1889, p. 167; ibid., 1890, p. 219. Ibid., 1892–93, pp. 427—430.

lesions. From cultures in alkali-albumen solutions, albumoses acting similarly could be obtained. In the membrane, however, albumoses were practically absent.

This view seems to us to be open to some objections—

1. We have no evidence that the ferment-like substance when inoculated into an animal leads to the formation of toxic albumoses.

2. The ferment-like body of the membrane is much more active than the albumoses from the spleen and other organs.

3. Evidence is gradually accumulating that the specific toxines are not albumoses or ordinary proteids, and in the case of the diphtheria bacillus by growing it in asparagin solution, Uschinsky [1] has obtained a toxine which does not react as an albumose or ordinary proteid.

We know that albumoses are formed in the course of many infective processes, but that, as in the case of tetanus, they are apparently mere concomitants or contaminations, which, during the precipitation with alcohol or whatever reagent is used, may be carried down together with the true poison.

We believe that the toxine is a direct product of the diphtheria bacillus, which in the membrane is found in its purest form, and that wherever the diphtheria bacillus occurs there also this toxine exists. Hence, since this bacillus exists in the lungs in large numbers in fatal cases, the toxine also must exist there in great quantity. Therefore, in such cases the amount of poison present at death is very considerable. It is absorbed as such by the blood and tissues, and passes therefore also into the spleen and kidneys. Add to this that we frequently find diphtheria bacilli actually in the spleen, and we can no longer wonder that toxic substances occur in this organ. That in precipitation with alcohol they appear to be albumoses may be accidental, the albumoses coming down together with the true toxine, so that as a matter of fact we have a mixture of albumoses *plus* toxine rather than a toxic albumose, as Duclaux [2] pointed out some few years back.

In his exhaustive chemical researches Martin has not realised, it seems to us, the extensive distribution of the diphtheria bacillus in most, if not all, fatal cases. His own cases are just the kind of cases in which we should have expected to find bacilli in the lungs, for they were generally cases of laryngeal diphtheria (four out of

[1] 'Centralbl. f. Bakteriol. u. Parasitenk.,' Jena, Bd. xiv, p. 316.

[2] 'Ann. de l'Inst. Pasteur,' Paris, 1892, tome vi, p. 369.

six), and in one of these there was also broncho-pneumonia. But the observations of Wright and Stokes and our own show that in fatal cases of diphtheria the lung is almost always infected (namely, in sixty-five out of sixty-six cases).

We think, therefore, that the simplest view to take of the process of diphtheria intoxication is that the bacilli wherever present secrete a toxine—which is not an albumose, but a substance at present chemically undefined—which is directly absorbed, and acts directly as a nerve and general tissue poison; and that the albumoses are only secondary products, poisonous no doubt, but not of specific importance; and that since in fatal cases the bacilli are present in large numbers in the membranes, and are absent or present only in smaller numbers in the spleen, therefore a less active toxine is obtainable from the latter than from the former; and that when bacilli are absent from the spleen the toxine has been absorbed into the spleen from the membranes or lungs. At any rate, it seems to us that the albumose theory in the form proposed by Martin cannot stand, unless the absence of bacilli beyond the membranes is established, and even this would hardly be a convincing argument.

2. Clinically we think our observations are of importance, since they prove the necessity of using the antitoxine energetically in all serious cases of diphtheria, the amount of toxine to be counteracted being always enormous when the bacilli have gained access to the lungs or other organs. The existence or suspicion of broncho-pneumonia should always excite us to action, and the antitoxine should not be spared when this complication arises. We would also suggest that in laryngeal cases prompt and copious injections should be administered in order to circumvent the dangers of a diphtheritic broncho-pneumonia.

January 21*st*, 1896.

We append a table which has been drawn up from all the cases examined by us, setting forth all the various points on which our conclusions have been based.

Sex and age.	General condition on admission.	Days under treatment till death.	Tracheotomy or intubation.	Condition of throat and larynx P.M.	Condition of lungs P.M., with bacteriological investigation.	Condition of spleen P.M., with bacteriological investigation.
M. 5½	In a dying condition; duration on admission =1 week	Died on day of admission	Tracheotomy	Laryngeal diphtheria	Broncho-pneumonia. Bacilli	Bacilli.
M 2	Much distressed	2 days; antitoxine	Tracheotomy	Small bronchi: membrane. Nostrils: membrane. Soft palate: membrane. Larynx: membrane	Bacilli	Bacilli.
M. 2	Chronic peritonitis; noticed nasal discharge, ? 2 days; patch on tonsils	(87 days in hospital); 2 days; 10 c.c. antitoxine	Tracheotomy	Soft palate: membrane. Tonsils: membrane. Larynx: membrane. Epiglottis: membrane	Patches of collapse, miliary tubercle. Bacilli	Spleen 6 oz. Not examined bacteriologically.
F. 5½	No cyanosis; healthy-looking; much recession	1 day	Tracheotomy	Tonsils: membrane. Uvula: membrane. Epiglottis: ulcerated. Trachea: no membrane	Bacilli	Spleen 4 oz. No bacterial examination.
M. 4	Blue; not prostrate	32 days; antitoxine	Tracheotomy	Tonsils: membrane. Soft palate: membrane. Larynx: membrane. Bronchi: membrane	Broncho-pneumonia; collapse. Bacilli	No bacterial examination.
M. 11	Fairly good condition	3 days; antitoxine, 45 c.c.	Tracheotomy	—	Collapse; no pneumonia. Bacilli	Spleen 2½ oz. Bacilli.
M. 1¼	Laryngitis; recession	8 days; no antitoxine	Tracheotomy	Epiglottis: membrane. Larynx: membrane. Trachea: membrane. Bronchi: membrane	Broncho-pneumonia; collapse; subpleural ecchymoses. Bacilli	No bacterial examination.

M. 4	Livid	Died on day of admission	Tracheotomy	Soft palate: membrane. Larynx: membrane. Bronchi: membrane. Tonsil: membrane. Nose: membrane	Broncho-pneumonia; extensive collapse. Bacilli	Spleen [illegible]. Bacilli.
M. 1½	Stridor	8 days; 6 c.c. antitoxine	Intubation on admission; tracheotomy 8 days later; death	Larynx: membrane. Trachea: rough. Tonsils: membrane	Collapse. Bacilli	Bacilli.
M. 1 1/12	Pale; breathing rapidly; inspiratory stridor	3 days; 10 c.c. antitoxine	Tracheotomy	Pharynx: membrane. Larynx: membrane. Trachea: membrane. Bronchi: membrane	Broncho-pneumonia; pleuritic hæmorrhages. Bacilli	Bacilli.
F. 2	Inspiratory dyspnœa; marked recession	1 day; 13 c.c. antitoxine	Tracheotomy	No membrane	Broncho-pneumonia; collapse. Bacilli	—
F. 3/12	Much collapse	1 day; no antitoxine	—	Epiglottis: membrane. Trachea: membrane	Broncho-pneumonia. Collapse. Bacilli	Bacilli.
M. 5	Moribund	2 days; 19 c.c. antitoxine	Tracheotomy on admission	Pharynx: membrane. Tonsil: membrane. Larynx: membrane	Lungs natural. Bacilli	Spleen natural. Bacilli.
M. 1⅓	Livid	4 days; 26 c.c. antitoxine	Tracheotomy 1 day after admission	Tonsils: membrane. Larynx: membrane. Bronchi: membrane	Broncho-pneumonia; pleurisy; collapse. Bacilli	Bacilli.
F. ?	Tuberculous meningitis	4 days	—	Tonsils were inflamed; pus	Broncho-pneumonia; tubercle in lung. Bacilli	—
M. 2	Cyanosed; recession	2 days; 40 c.c. antitoxine	Tracheotomy on admission	Tracheitis	Broncho-pneumonia. Bacilli	Bacilli.
M. 4/12	Much recession	1 day	Tracheotomy	Tracheitis; bronchitis	Broncho-pneumonia. Bacilli	—

Sex and age.	General condition on admission.	Days under treatment till death.	Tracheotomy or intubation.	Condition of throat and larynx P.M.	Condition of lungs P.M., with bacteriological investigation.	Condition of spleen P.M., with bacteriological investigation.
M. $\frac{3}{12}$	Livid; much stridor; recession	3 days; 75 c.c. antitoxine	Tracheotomy on admission	Larynx: membrane. Bronchi: membrane	No pneumonia. Bacilli	Spleen: streptococci. Heart: streptococci.
M. $2\frac{1}{2}$	Meningitis; retraction of head	4 days; 5 c.c. antitoxine	—	Trachea: bacilli	Bacilli	Purulent meningitis: diplococcus; pneumonia. Spleen: nil.
M. $4\frac{1}{2}$	Livid; dyspnœa; recession	14 days; 16 c.c. antitoxine	Tracheotomy on admission	Trachea: membrane. Bronchi: ulcerated	Broncho-pneumonia. Bacilli	Spleen normal.
M. 1	Pale; slight recession	1 day; 26 c.c. antitoxine	Tracheotomy	Pharynx: membrane. Larynx: membrane. Bronchi: membrane. Bacilli	Broncho-pneumonia. Bacilli	Spleen: nil. Kidneys: bacilli. Excoriation behind ear: bacilli. Ulcer on neck: bacilli.
F. $2\frac{1}{2}$	Marked cyanosis; stridor; recession	22 days; 65 c.c. antitoxine	Tracheotomy	No membrane in larynx or trachea. Larynx: bacilli. Trachea: bacilli	Broncho-pneumonia. Bacilli	Spleen normal.
—	Not prostrate	13 days; no antitoxine	—	Trachea: erosions. Larynx and epiglottis ulcerated. Membrane in larynx; bacilli	Lungs: collapse in part. Lungs: bacilli. Epiglottis: bacilli	Spleen: typhoid bacilli. No diphtheria.
—	Broncho-pneumonia; no stridor	5 days	—	Larynx: diphtheritic bacilli. Vocal cords rough. No membrane	Lung: bacilli in numbers	Spleen: streptococci No diphtheritic bacilli.
F. $\frac{1}{12}$	No recession	2 days; no antitoxine	—	Larynx: bacilli	Lung: bacilli	Spleen, liver, kidney: streptococci; kidney: also bacilli. Intestine: *Bac. coli.*
F. 30	Livid	2 days; 40 c.c. antitoxine	—	Tonsils, larynx, bronchioles: membrane, bacilli	Lungs: collapse	Spleen and kidney: nil. Bronchial glands: bacilli.

Addendum.—Since the above communication was made, a paper has appeared by J. Nowak[1] which confirms and strengthens the position taken by Wright and ourselves. This writer examined the blood and spleen in 22 fatal cases of diphtheria—all children, and found in 9 cases the Klebs-Löffler bacillus associated in each instance with the *Streptococcus pyogenes* (in a tenth case a bacillus resembling the diphtheria organism, but not pathogenic to guinea-pigs). Nowak apparently is not familiar with the publication of Wright and Stokes, for he covers the same ground without a single allusion to their works, although Wright's paper had been fully abstracted in the 'Centralblatt für Bakteriologie.' Our figures closely agree with Nowak's, for we found diphtheria bacilli in the spleen in 10 out of 21 cases. We must also allude to the observations of S. Belfonti,[2] as epitomised in the 'Centralblatt für Bakteriologie,' the original communication having been inaccessible to us. He examined 26 cases of broncho-pneumonia appearing in the course of diphtheria, and found the Klebs-Löffler organism in 21 instances, 4 times alone and 17 times associated with pyogenic germs. He therefore believes, as we do, that there is a true diphtheritic broncho-pneumonia. He also, it appears, is not familiar with the American literature.

Since March we have had the opportunity of examining six more fatal cases. In all six diphtheria bacilli were found in the lungs, in two in the spleen, and in one in the kidney as well. Hence, taking all our 32 cases, the bacilli occurred in the lungs in all instances; in the spleen, on the other hand, they were found 12 times in 27 examinations.

---

7. *Cultural variation in* Streptococcus pyogenes bovis.

By Samuel G. Shattock.

[With Plate XII.]

For a considerable time I have observed in this micro-organism a cultural variation which has arisen during the course of a series of sub-cultures, carried on from an original isolated by Professor Crookshank from the suppurating peritoneal cavity of a Jersey cow.

[1] 'Centralbl. f. Bakteriol. u. Parasitenk.,' Jena, Bd. xix, pp. 982—991.

[2] 'Ibid., p. 618.

Professor Crookshank holds that *Streptococcus pyogenes bovis* and *Streptococcus pyogenes hominis* are distinct varieties, since when grown under exactly identical conditions there is "more difference in cultural characters between them than between *Streptococcus pyogenes hominis* and *Streptococcus erysipelatosus*." Minute differences in macroscopic cultural characters, however, as experience has proved, can no longer be safely relied upon as indicative of true, *i. e.* stable differences between closely related bacteria. Of more importance is the marked difference between the two microbes in question in regard to their hardiness of growth. No organism grows more readily and certainly than *Streptococcus pyogenes bovis*, and this after an unlimited number of sub-cultures; on the contrary, the *Streptococcus pyogenes hominis* it is very difficult to subcultivate on ordinary solid media: one might compare them in this respect with the pneumococcus of Friedländer and that of Fränkel.

The variation is now almost constant in this particular strain, and as it has not yet been noticed I venture to describe it in detail. For some while I assumed the appearance in question to have arisen from a contamination, and took it almost for granted that two different organisms were growing symbiotically. A careful investigation proved that this was not the case. The variation arises in cultures started from plate colonies made from the normal or more commonly constituted parts of the culture. I have, moreover, several times obtained the same result by sowing jelly tubes from the lowest end of a stab culture where the growth has presented the ordinary well-known characters; this may be carried out by breaking off the bottom of the test-tube, and shaving away the jelly with a sterilised knife until the lowest end of the culture is almost reached: the colonies can then be transfixed with the platinum wire, and stab cultures made in the usual manner.

The variation under consideration consists in the outgrowth of mossy tufts from certain of the colonies which develop along the line of a stab culture. The outgrowths affect certain only of these colonies, and are at first quite minute and sessile. They are especially marked in the uppermost part of the jelly, growing from the lower aspect of the small superficial extension at the entrance site of the puncture (nail-head).

With a pocket lens these tufts can be resolved into tortuous rows of minute points; they present not a hairy, but what is best described as a mossy character. The growth is very like that which

at times occurs in stab cultures of *Bacillus coli communis*, of which a typical illustration is given by Sternberg in his 'Manual of Bacteriology.' Sternberg's cultures were carried on in a 25 per cent. jelly. The likeness is the closer as *Bacillus coli communis* in a stab culture presents the same primary method of growth, viz. a line of discrete grains or miliary colonies, commonly flattened where apposed, and altogether remarkably like a highly magnified streptococcus. For the sake of precision I may cite a typical observation.

March 19th, 1895.—I made a stab culture in gelatine from a recent broth cultivation of the streptococcus. It grew in every way typically, but by March 30th there was a distinct outgrowth from near the lower extremity of the line. As studied with a lens the excrescences were somewhat compact, had a slightly frayed edge, and could be resolved into closely entangled filaments, which were themselves branched and subdivided, the whole appearance being most aptly described as moss-like. From the whole of the lower side of the small flat superficial growth in the immediate neighbourhood of the puncture (nail-head) there was a similar downgrowth into the substance of the medium; the culture was otherwise typical, and consisted of discrete spheroidal colonies.

April 20.—The projection near the lower end of the culture was no longer mossy, but cauliflower-like, and so was that in the under surface of the jelly. This change in character had arisen from an increase in size of the minute colonies forming the outgrowths.

27th.—From the cauliflower-like growths a beautiful mossy extension had occurred. There were then five or six minute mossy outgrowths from other colonies of the line.

May 7th.—About nine colonies had now so grown out. In the Plate (Plate XII, fig. E) this culture is shown as it appeared towards the latter end of May. I have seen exactly the same mode of growth in the colonies of plate cultures (Plate XII, fig. B).

Professor Klein tells me that he is acquainted with a similar variation in old stab cultures of *Streptococcus pyogenes hominis*. That the organism in question is a true streptococcus, and not a variety of the pleomorphic *Bacillus coli communis*, is proved by the constancy of its microscopic characters. In both jelly and broth cultures, however, the cocci are at times much flattened and very closely set in short chains, suggestive at first of rods, but the regularly serrated edge which such invariably present reveals their true composite nature.

Saccharomyces albicans.—Amongst pathogenic organisms, not liquefying nutrient gelatine, there are very few which grow in the manner just described. Besides *Bacillus coli communis* and *Streptococcus pyogenes bovis*, I have often observed it in stab cultures of *Saccharomyces albicans* obtained from an ordinary case of thrush. The culture at first affects the form of discrete spherical or oval colonies, but from many of these there grow out with a general horizontal direction brushes of filaments which eventually attain considerable length, and recall the dendritic character of an anthrax culture. There is no marked direction either downwards (positive) or upwards (negative geotropism). In the well-known streak cultures on gelatine of *Bacterium Zopfii* or *Bacillus figurans* (Crookshank) the lateral processes of growth proceed bipinnately from the line of inoculation with a marked upward direction which Rubert Boyce and Ernest Evans ('Proc. Royal Soc.,' vol. liii, February 7th, 1893) have shown to be due to negative geotropism, *i. e.* to an upward tendency of growth of the same kind as that of the stem and branches of higher plants in contradistinction to the earthward direction of the root.

The appearances described in *Saccharomyces albicans* may be well pronounced within a fortnight of inoculation, and as it has not been figured I venture to do so from a photograph kindly taken by Professor Crookshank from one of my preparations. In roll cultures (10 per cent. gelatine) the organism is still more beautiful. The colonies within a week show a remarkably regular radiate structure of filaments accurately diverging from a centre. Others remain for a while as milky-white circular plaques, and subsequently may only radiate in an irregular and abortive manner. As time goes on the radiating character becomes highly pronounced, as shown in fig. D, Plate XII; the rays are somewhat coarse, and lie on the surface of the medium. In stab cultures in gelatine, in the same manner, one may observe similar coarse, flat processes radiating on the surface from the margin of the "nail-head," whilst those growing from the colonies in the depth of the jelly have the delicate character of a common mycelium. These coarser threads on the surface consist almost solely of yeast forms with few or no filaments, and in this they differ from the fine hairy processes which invade the jelly from the deeper part of a stab culture. Baumgarten ('Lehrbuch,' Bd. ii, p. 915), in his account of the organism, recites in the main that given by Grawitz ('Virchow's Archiv,' Bde. lxx, lxxiii, ciii).

DESCRIPTION OF PLATE XII.

Illustrating Dr. H. D. Rolleston's paper on "An Anomalous Tumour of Sebaceous Glands" (page 242); and Mr. Shattock's paper on "Cultural Variation in *Streptococcus pyogenes bovis*." (Page 375.)

FIG. A shows the tumour to be situated *on* the skin, and that there is no infiltration of the dermis. (× 3.)

FIG. B.—A colony of *Streptococcus pyogenes bovis* (culture of about three weeks in a Soyka bottle), showing the outgrowths into the medium (10 per cent. gelatine). (Enlarged 10 times.)

From a photograph by Mr. C. G. SELIGMANN.

FIG. C.—Stab culture of *Saccharomyces albicans* (10 per cent. gelatine), showing fine dendritic outgrowths from the colonies. The outgrowths are usually finer and more densely set.

FIG. D.—Colony of *Saccharomyces albicans*. Roll culture, showing the regularly radiate arrangement of coarse outgrowing processes on the surface of the jelly from a central plaque. The smaller colonies are *Streptococcus pyogenes bovis*, the two micro-organisms having been intentionally mixed before making the culture.

Photographed by Mr. C. G. SELIGMANN.

FIG. E.—Stab culture of *Streptococcus pyogenes bovis* of about two months' age, showing the mossy outgrowths from many of the spheroidal colonies (10 per cent. nutrient gelatine). (Slightly enlarged.)

Photographed by Prof. CROOKSHANK.

In process of time the outgrowths arise along the whole track and extend more deeply.

PLATE XII.

Fig. A.

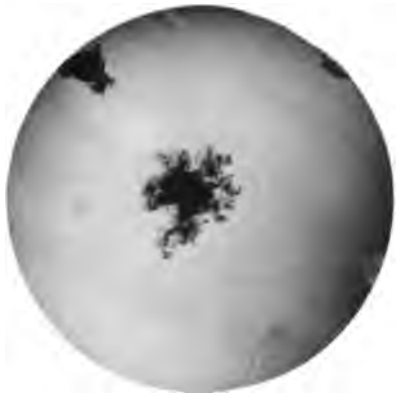

Fig. B.

Fig. C.

Fig. D.

Fig. E.

According to Grawitz, in dilute nutrient solutions, especially poor in sugar, the mycelial form is chiefly observed; under contrary conditions the yeast; on apple discs, potato, bread, the latter form is alone met with. In stab cultures in gelatine both filaments and yeast forms arise, the first farther from the surface, the second nearer to it. He describes the nail-head of the culture, and the radiation of filaments from the central line of growth into the substance of the medium. In his later paper Grawitz repeats the view set forth in his earlier, viz. that the organism of thrush is closely allied to, if not identical with, *Mycoderma vini*. Plaut, on the contrary, identifies it with *Monilia candida*, a widely spread form of the Torulaceæ belonging to the lower order of mould fungi.

May 19th, 1896.

---

8. *Microscopic preparations of* Streptothrix Maduræ.

By C. G. Seligmann (per S. G. Shattock).

This microbe was isolated by Vincent ('Ann. de l'Institut Pasteur,' 1894), who points out the following facts in regard to it. Madura foot has hitherto been fairly considered an exclusively Indian disease. It has, however, been seen in Italy and America, while his own case occurred in a native Morocco labourer who lived and had developed the disease in Tunis. The disease began as a diffuse swelling of the integuments of the foot; from the small tumours subsequently formed, pus containing yellowish rounded bodies the size of grains of semolina was discharged. These bodies, which are insoluble in caustic potash and acetic acid, consist microscopically of a fine, densely interlacing mycelium; peripherally the filaments, which are 1 to 1·5 μ thick, give off lateral offshoots. The radiating arrangement of the fibres recalls Actinomyces, but is unlike the latter in that no clubs are produced. Some filaments, probably involution forms, are bent, and present irregular thickenings and lacunæ in the protoplasm.

Cultivations on hay or potato infusion at 37° C. give the best result; it develops but slightly in bouillon, and then slowly forms greyish, flocculent zooglœa masses, which may stick to the glass

Similar masses appear in hay infusion about the fourth or fifth day; in about three weeks they are as large as a pea, and may have a brownish centre. The infusion becomes slowly alkaline, and colonies near the surface may in a month or two become pink or red. Often the free surface of the liquid is covered with a mass of whitish spores. In gelatine thrust cultures sparse colonies are formed round the needle track. On gelatine prepared with glucose and glycerine, abundant convex yellowish colonies are formed, the surface of which appears glazed. Later on these may become dark red; then the centre, which remains white, becomes depressed, and the whole eventually somewhat resembles a smallpox pustule. Old cultures bleach to a dull white. Very similar but more irregular colonies are formed on potato. The zooglœa masses grown on solid media form hollow spheres. The spores stain well with aniline dyes. The parasite is aërobic.

Inoculation experiments on rabbits, guinea-pigs, cats, and mice have uniformly failed.

Finally, the pathological anatomy of the diseased tissues is discussed in the paper referred to, and a table of differences between Actinomyces and *S. Maduræ* is given:

Culture or Inoculation.	Actinomyces.	S. Maduræ.
Peptonised bouillon	Growth abundant	Growth sparse.
Hay infusion	Nil	Best culture medium.
Ordinary peptonised gelatine	Liquefies	Does not liquefy.
Hay infusion gelatine	Sparse whitish growth	Rapid growth, colony becomes superficially red.
Gelatine with glycerine and glucose	Colonies at first white, then greyish; surface wrinkled	Colonies at first white, then red; surface umbilicated.
Potato	Thick growth, whitish or yellow; potato darkens	Red or dark red growth; substratum does not darken.
Cabbage, carrot, turnip	Nil	Growth.
Serum	Growth	Nil.
Egg	Growth	Nil.
In vacuo	Facultative anaërobe	Nil.
Inoculation	Inoculable on rabbits, calves, and guinea-pigs	Uniformly fails.

Since writing the above, Dr. Vincent has informed me that he has again met with the white form of the disease in a native of Algeria, and that he has isolated the same micro-organism from this case.

Note by Mr. Shattock.—In this country Kanthack ('Lancet,' January 23rd, 1892) was the first to demonstrate the close microscopic likeness between the white variety of Madura disease and actinomycosis, though the general resemblance had struck all of those conversant with specimens of the two diseases; they are, indeed, too obvious for it to be otherwise. Hewlett, a few months later ('Lancet,' July 2nd, 1892), confirmed Kanthack's observation, whilst Rubert Boyce and Surveyor arrived at the same conclusions shortly afterwards ('Proc. Royal Soc.,' February, 1893). No opportunity, however, had offered itself here of attempting the cultivation of the micro-organism. This was successfully carried out by Vincent from the case cited in the paper referred to by Mr. Seligmann. Vincent in his remarks mentions that the micro-organism, as examined in the natural condition, wants the clubs, and so differs from Actinomyces. This statement, it need hardly be said, requires modification; in man the clubs are frequently absent from Actinomyces, and absent in exceptional cases even in bovines; yet, as is well known from the results of experimental inoculation, the organism is identical, for its forms are interchangeable: moreover the clubs are not invariably absent from the Madura streptothrix in its natural condition; they are figured by Kanthack ("Madura Disease," 'Journal of Pathology,' October, 1892), and by Hewlett in the 'Transactions' of the Pathological Society, vol. xliv, 1893.

Amongst the differential characters given by Vincent is the umbilicated conformation of the colonies of *Streptothrix Maduræ* on glycerine-glucose gelatine, whilst Actinomyces liquefies gelatine and grows with a wrinkled surface. I have often seen beautifully marked umbilication of the hemispherical colonies of Actinomyces when grown on grape-sugar agar.

Vincent's description of the growth of Actinomyces on glycerine-glucose gelatine does not hold for the growth on ordinary nutrient gelatine. When Actinomyces is sown on a jelly slant, the small discoid whitish colonies that grow soon liquefy the medium, and subside in the clear fluid as spheroidal grains which retain the same white colour. The extremely close resemblance between *S. Maduræ* and Actinomyces is very evident, and is such as to render it not improbable that the primary source of the micro-organisms will prove to be identical; the variations are hardly greater than those, *e.g.*, presented by the cholera spirillum.

May 19th, 1896.

9. *Extensive hæmorrhage associated with the presence of pyogenic micro-organisms.*

By Raymond Johnson, M.B.

The clinical features of the case may be narrated shortly as follows. James W—, aged 15 years, was admitted into University College Hospital on August 14th, 1895. His illness began three weeks previously with pains in the left knee, which became swollen, and obliged him to take to his bed. A week later swelling appeared in the region of the right hip, and shortly afterwards in the right shoulder. On August 11th the swelling about the left knee was incised, and pus evacuated. When admitted the boy looked very ill, and his temperature was 100° F. The left knee-joint was distended with fluid, and over the upper end of the tibia was a short incision exposing bare bone, and discharging a few drops of pus. There was marked swelling of the outer half of the right buttock, and notwithstanding the extreme tenderness, fluctuation was obvious. Lastly, there were swelling, redness of the skin, and tenderness over the outer third of the right clavicle.

The diagnosis was made of multiple acute necrosis affecting the upper end of the left tibia, with extension of suppuration into the knee-joint, the upper end of the right femur, and the outer third of the right clavicle. The possibility of all the three foci being secondary to some other source of infection—such, for instance, as suppuration in the middle ear—was taken into consideration, but no evidence of this could be found. It was therefore assumed that the primary condition was acute suppuration, commencing in the upper epiphysial line of the left tibia. An anæsthetic was administered, and an incision made into the supposed abscess in the right buttock. After the division of the gluteus maximus about ten or twelve ounces of dark blood, partly fluid and partly clotted, escaped, and the finger entered a large smooth-walled cavity beneath the muscle.

This cavity extended to the back of the femur, and near the small trochanter the bone was bare over an area which could just be covered with the tip of the index finger. After applying firm pressure for a few minutes, and being satisfied that no hæmorrhage was

going on, the incision was loosely plugged with strips of gauze, and a dressing of gauze and wool was firmly applied.

This unexpected state of things suggested the possibility that the case was of an altogether different nature from that originally entertained—one, indeed, of hæmorrhagic purpura; that the swelling which had been opened over the left tibia was an extravasation of blood, and not an abscess; that the knee was distended with blood, and not inflammatory effusion; and that a subperiosteal hæmorrhage was the cause of the painful swelling of the clavicle. The only further symptom in any way supporting this view was the occurrence of several slight attacks of epistaxis during the few days which preceded the patient's admission to the hospital. The original diagnosis still seemed to me the more probable—viz. that the case was essentially one of multiple infective inflammations of bone, to which in some way the hæmorrhage was secondary. This was sufficiently proved by the fact that the knee was found to be distended with turbid fluid such as is commonly met with in pyæmia, presenting none of the appearances of altered blood. The joint was saved after free drainage by lateral incisions. An extensive sequestrum was subsequently removed from the tibia. The inflammation of the clavicle subsided without suppuration. The cavity from which the blood was evacuated in the right buttock rapidly closed without suppuration, and at the present time—six months after the onset—there is a considerable mass of new bone formation about the upper end of the femur.

Bacteriological examination showed that the fluid in the left knee was rich in the *Staphylococcus pyogenes aureus*, and further that the organism was also abundant in the blood effused about the right femur. This was proved both by the examination of cover-glass preparations and by cultures on nutrient gelatine.

The obvious question arises, was the hæmorrhage caused by the pyogenic organisms, or were the latter merely present in the blood which was effused as the result of some other cause? The absence of any history of injury or other likely cause of extravasation of blood, and the fact that a small patch of the femur was stripped of its periosteum, seem to me to point strongly to the staphylococcus as the actual cause of the hæmorrhage. I believe that an infective periostitis of the femur with suppuration was at first present, and that before the abscess had reached any appreciable size extensive

hæmorrhage occurred into it, so that all traces of the nature of the original lesion were masked.

The presence of the other foci of infective bone inflammation served to indicate the true nature of the case; but I submit that had these not been present the condition would have presented itself clinically as one of spontaneous hæmorrhage, and not of acute suppuration, and that the part played by the pyogenic organisms in its production might easily have been overlooked.

I may remind the Society that in the 'Transactions' of 1884 will be found a communication by Mr. Watson Cheyne on "Two cases of purpura hæmorrhagica in which micro-organisms were present." Both cases ended fatally, and in both superficial and visceral hæmorrhages were present. In one case colonies of bacilli and a few isolated organisms were found both in the effused blood and in the surrounding capillaries. In the second case, in which the first symptom was the appearance of a boil on the neck, plugs of streptococci were found in the capillaries around one of the hæmorrhages in the lung. Mr. Cheyne suggested that in both these cases capillary embolism by colonies of the organism was the cause of the hæmorrhages.

I have ventured to bring my case forward as a further inducement to the bacteriological investigation of cases of spontaneous hæmorrhage. *January* 21*st*, 1896.

---

10. *An undescribed form of hæmatozoon.*

By Norman Moore, M.D.

[With Plate I, fig. A.]

The hæmatozoon, which resembles *Hæmamœba præcox*, occupies a red blood-corpuscle. It is ovoid with a curved axis, and contains in the middle some pigment granules. From its greater curve project two small processes. In this circumstance it differs from any of Laveran's figures, as well as from those of Marchiafava and Bignami.

Projections from the surface of the corpuscle are shown in one of Laveran's figures, but they are the pointed ends of the crescent-shaped organism. The projections in this specimen do not appear

1896.

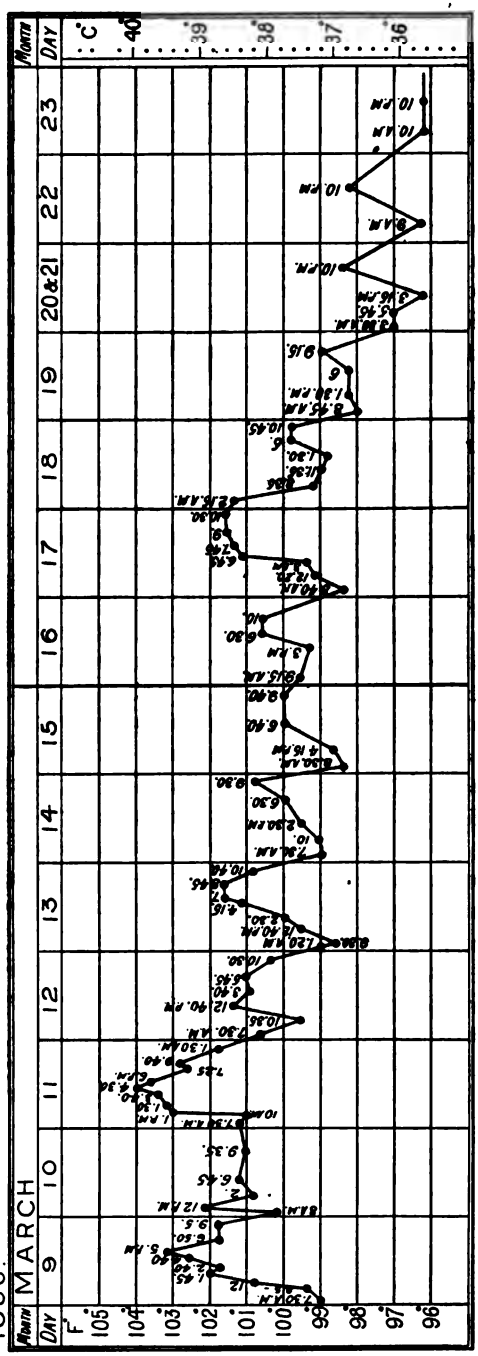

to be flagella, but rather resemble the pseudopodia of some Protozoa.

The blood was taken from the finger of the patient after proper cleaning, and the specimen was at once exposed to osmic acid, and afterwards stained with eosin and methyl-blue. The hæmatozoa were not numerous. The blood-corpuscles generally seemed natural. A specimen examined two days before this showed only a very few spherical bodies with pigment.

The patient was an officer who served in the recent expedition. He felt quite well on the way up to Kumasi, but on the way back was conscious of a slight degree of weakness and fever. After embarkation he rapidly became ill, and at Las Palmas on the voyage home had a daily temperature of 104° and a continued fever. This diminished before his arrival at Plymouth, and he was able to do duty on landing in the Thames. A week later he was obliged to go to bed, and from March 8th to March 19th suffered from daily fever with an intermission of about four hours, accompanied by well-marked enlargement of the spleen and liver, much vomiting, and inability to take food. His other organs seemed normal. Some years before he had had acute endocarditis, and had a febrile attack which did not recur, and was probably not malarial, at Wady Halfa. His highest temperature each day, as shown in the accompanying chart, was about 102·5°, but sometimes reached 104°. The fever ceased on March 20th, and he had no relapse. The specimen was taken about three hours before the normal hour of highest temperature, and up to that time he had had no quinine for a fortnight. It seems worth while to note the peculiarity of form in the hæmatozoon, even if it is a circumstance in its phases of development, and not a character indicating species. Two examples with similar processes were found in another specimen by my clinical clerk, Mr. Hussey. For purposes of identification it seems worth while to give the hæmatozoon which is described in this paper the provisional name of *Hæmamœba cumasiensis*, from the locality in which it was acquired.

May 5th, 1896.

11. *The healing of incisions in vegetable tissues.*

By SAMUEL G. SHATTOCK.

[With Plates XIII, XIV.]

SYNOPSIS OF COMMUNICATION.

The five methods of wound-healing in man.
The repair of incisions in plants.
(1) *Immediate union* not observed.
(2) *Primary adhesion.*—Methods of experiment.
Healing (A) without separation of surfaces:
(*a*) without sclerosis of scar-tissue.
(*b*) with sclerosis of scar-tissue.
The healing of the gaping edges of incisions and formation of sclerenchyma.
Fate of starch shed into an incision.
Removal of starch in branchlets of *Aucuba Japonica* shed after experiment.
Healing (B) of gaping parts of incisions without cork-formation.
Effects of tension:
(*a*) Healing in *Faba vulgaris*, without sclerosis of scar-tissue.
(*b*) Healing in *Ficus carica*, with sclerosis of scar-tissue.
(3) *Healing by secondary adhesion*, or where the surfaces are first healed by cork.
Effusion of latex in petiole of Rheum.
Union by disruption of cork, *e.g.* in Echinocactus and in exogenous shrubs and trees.
Comparison between the repair in plants and in animal tissues.

IN the 'Linnean Society's Journal' (vol. xix), in a paper on the reparative processes which occur in vegetable tissues, I discussed the results that ensue after amputation, as observed independently by myself, and referred to the work of Frank ('Die Krankheiten der Pflanzen') published a few months previously. I did not then describe the process by which the surfaces of exposed wood in exogenous shrubs and trees are covered; the macroscopic appearances of the growth of callus from the cambium beneath the dead edge of the bark around such surfaces are well known, and I have nothing to add to the histology of the process as it is detailed by Frank (loc. cit.), and later by R. Hartig ('Lehrbuch der Baumkrankheiten'). In the communication referred to I proposed to consider plant repair as it takes place after amputation, after incision, and in the artificial union of parts in grafting and budding. In the present communication the healing of incisions is fully dealt with, and has not been so treated systematically before. The

questions of grafting and budding are referred to very briefly, and only as related to the other subject, especially as they do not present any minute features peculiar to themselves.

It may be advantageous for the sake of clearness to refer shortly to the different modes, or more correctly to the different manifestations of the single mode, whereby incisions are healed in the tissues of man (or the higher animals), before entering upon what occurs in plants, in order that the methods in the two cases may be compared and contrasted.

There are generally reckoned five ways in which wounds may be healed in man. The names adopted for these by Sir James Paget ('Surgical Pathology,' 2nd edit.) are—

(1) Immediate union.
(2) Primary adhesion.
(3) Granulation.
(4) Secondary adhesion.
(5) Beneath a scab.

In the first mode, that by *Immediate union*, the severed parts are believed to unite immediately, without the intervention of any new material, and at once in respect of time, the parts of the individual cell or of the individual fibre being at once united, so as to immediately re-establish the perfect form and function of the several elements.

In the second mode, *Primary adhesion*, the divided structures are conjoined by the formation of a small-celled or embryonic tissue between them, the exterior of the connecting material being later on covered by the spread of epithelium from that which invests the parts around, and the embryonic tissue itself being developed into fibrous tissue.

In the case of bones fractured without external wound, the embryonic or granulation tissue formed between and around the fractured ends develops into osseous substance.

Granulation.—There is no proper healing of an *incision* in this mode of repair, the term being limited to the healing of open wounds. A small-celled embryonic or granulation tissue is formed on the wounded surfaces, and by the contraction of this during the healing process the deeper parts of the wound are raised, and the superficial depressed, until the injury no longer partakes of the nature of an incision, and heals finally by the spread of epithelium over its surface from the general epithelium around.

The fourth mode of healing enumerated, that by *Secondary adhesion*, is the union which occurs between two healthy granulating surfaces when these are brought together. The fifth and last mode by which wounds may heal is beneath a dry crust or *Scab* of blood or pus. Here, again, it is open wounds only that so heal. The repair is effected by the formation of granulation tissue beneath such a scab, and over the former epithelium extends from that around, the granulation tissue subsequently developing into the fibrous tissue of the cicatrix, as in healing by "granulation."

In plants, therefore, the healing of incisions is to be studied in the three methods of immediate union, primary adhesion, and secondary adhesion.

Of any kind of wound infection in plants I have never seen an instance, and what follows relates only to the normal healing of incisions.

Immediate union.—It is conceivable that incisions in plants might heal, firstly, by immediate union. This perfect mode of repair I have never observed, although selecting rapidly growing tissues, and taking every care to facilitate the reunion of the parts. Thus I have many times incised longitudinally, with a sharp thin-bladed lancet, the plumule in *Faba vulgaris* as near the punctum vegetationis as practicable, but not including it, and on withdrawing the lancet tied a noose of fine silk around the middle of the incision without exerting more than the gentlest pressure, the experiments being conducted and the plants afterwards kept in the warm, moist atmosphere of a hothouse.[1]

But although the blade of the lancet was entered and withdrawn with all possible exactness, and the parts not further touched throughout the operation than by the hand in steadying them for the incision, I have never observed immediate union in any part of the injury, either in the ground tissue or meristem. The results of such incisions, as studied by microscopic sections of hardened specimens twenty-four, forty-eight hours and onwards after experiment, show in all cases that the process of union is that to be next described, viz. primary adhesion. With the same object of endeavouring to obtain immediate union I made the following experiment in growing branches of the Weeping ash. A small square flap of the bark was

[1] Nearly all the experiments recorded in the paper were carried out in the gardens of the Royal Botanical Society, London, and to the Council of this Society I have much pleasure in acknowledging my obligation.

cut but left connected by one of its sides; this flap was next gently raised off the subjacent wood, and then allowed to return to its position; a piece of gutta-percha tissue or goldbeaters' skin was wrapped around the parts, and over this a layer of cotton wool was lightly spliced with a few turns of worsted. The raising of the bark is attended with rupture of the cambium cells and cells of the medullary rays,—the cell walls are not split so as to leave the cells entire. That this is so is proved by removing portions of the bark from pieces of the young growing branch whilst immersed in Kleinenberg's picric acid solution, and cutting transverse sections of the wood after preparation in the solution named, and subsequently in alcohol, or still better by tearing the bark from the wood in thin horizontal sections of the fresh branch whilst examined in water beneath the microscope.

After carrying out the experiment first referred to on several young actively growing branches, and examining the results by horizontal sections made after proper hardening, it is clear that no "immediate" union of the cambium takes place, *i. e.* no repair of the cells actually ruptured in the raising of the bark.

Although never observed, however, immediate union offers no difficulty of conception. The protoplasm of the divided cells might become confluent on the withdrawal of the lancet from an incision through meristem tissue, and the segments of the divided cell wall might contract an immediate cohesion, the natural rigidity of the parts sufficing in a vegetable tissue for the maintenance of the exact apposition which such a process would demand. Indeed, there is a natural phenomenon in which some such series of events actually occurs. In the Zygnemeæ conjugation is effected by the formation, from the cells of the two filaments concerned, of a lateral bud-like process, the processes ultimately cohering, whilst the intervening septum of cellulose existing at the point of contact disappears, and the contents of the filaments mingle to produce a spore. In this conjugation the processes of cellulose from the two cells temporarily unite, so as to preserve entire the common space which holds the protoplasm.

Nevertheless, with every theoretical admission of this kind, "immediate union" is not only highly improbable, but direct observation, so far as it can bear upon the question, is against it. If it would take place under any circumstances it might be in such a mobile mass of protoplasm as a leucocyte. And yet actual observation shows that in the amœba traumatic division is not followed by reunion

but by immediate closure of the cut surfaces and the formation of two individuals, of which that wanting the nucleus soon perishes (Bruno Hofer, "Experimentelle Untersuchungen über d. Einfluss des Kerns auf das Proplasma," 'Jenaische Zeitschrift für Naturwissenschaft,' vol. xxiv, 1889, p. 109, cited by Metschnikoff, 'La Pathologie comparée de l'Inflammation,' Paris, 1892). And this being so, it is incredible that after an incision in an animal tissue, however cleanly cut, union of the divided cells ever takes place.

Primary adhesion.—The cells divided in an incision, so far as I have observed, invariably fail of individual repair, and the union of the parts under the most favorable circumstances is effected by a process analogous to that which constitutes in animals primary adhesion as before defined.

All growing parenchyma readily heals after incision, and so completely that in many cases no trace of the injury remains discernible to the eye save at the very surface, where a shallow furrow often persists. The manner of experimenting has been in most cases to transfix the tissue longitudinally with a thin-bladed lancet, or in the case of large parts to use a long-bladed narrow knife. To cite one of the most striking examples out of a great number, I completely transfixed a Kohl-rabi with a long knife and made a free vertical incision. No protection was afforded beyond carefully replacing the soil around. At the cessation of growth the incision had healed for the whole of its extent, its course being traceable by the eye, however,

FIG. 20.

in transverse section by a narrow, pale brown, almost straight, but interrupted line[1] (Fig. 20).

[1] One of these specimens is in the pathological collection of the museum of the Royal College of Surgeons (No. 55A), where also almost all that can be shown to

Similar perforating incisions made in the young stems of Opuntia, Cereus, *Hyacinthus orientalis*, and, indeed, in any herbaceous or young woody stem, in the leaves of Agave, Aloë, &c., heal completely by such primary adhesion. No repair, however, takes place where the incision passes through woody prosenchyma. I have in almost all cases immediately after the injury applied gutta-percha tissue or goldbeaters' skin, and spliced cotton wool round the injured part, by which means drying is prevented, and the gaping that often results from tension is reduced, whilst the compressibility of the wool allows of subsequent growth.

The minute details of the process differ slightly in those parts of the incision where the surfaces remain in apposition, and those where they are separated by tension.

Healing without separation of the faces of the incision may be observed in parts of most such injuries; in some cases it obtains throughout. To take this, the simplest process of all first. The clean-cut longitudinal incision appears at first in horizontal sections as a direct line, dividing the injured cells into segments of different sizes, according as it traverses them diametrically or at varying

FIG. 21.

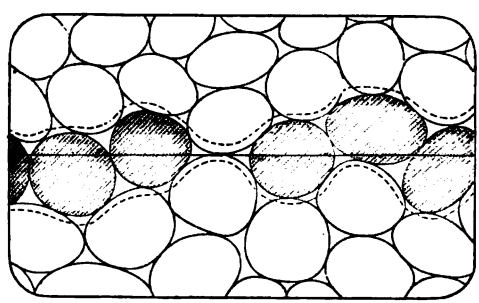

Showing the manner in which the cells are divided in an incision. The cells laid open are shaded. The dotted line on either side marks the walls of the intact cells bordering the injury.

distances from their centres (Fig. 21). The line next becomes uneven, zigzag, or undulatory, for this reason, that the remains of the divided cells are pressed together from each side of the incision as a result of the divisions of their neighbours; the contents of the cells

the naked eye in regard to plant repair is illustrated by a series of preparations presented by me a few years ago.

escape into the intercellular spaces or externally by the wound, but the compressed and flattened remnants of the protoplasmic sacs[1] pertaining to the opened cells retain their position, and serve as a sure means of tracing the line of repair. In some plants, *e. g.* the petioles of *Rheum rhaponticum*, a coagulable latex is shed into the surrounding intercellular spaces and into the incision. The walls of the intact cells bounding the incision and those remains of the walls of the cells laid open which are folded and pressed together in it, undergo no chemical change; no transformation of the cellulose into cork takes place, as is proved by treating sections with strong hydric sulphate, when the parts mentioned swell up and disappear like the cellulose walls of the surrounding parenchyma: the colour test with iodine solution and hydric sulphate discloses the same fact.[2]

Under either of these tests the compressed relics of the protoplasmic sacs within the incision remain unaffected, in this resembling the protoplasm in the surrounding cells; and by means of these the course of the incision remains traceable even when all the cell walls have been destroyed by hydric sulphate.

The living cells along either side of the line subdivide in planes more or less parallel with that of the injury. The new-formed tissue, however, is chemically like the rest of the parenchyma, *i. e.* it is not suberous. In the next stage the line of adpressed remnants of the walls and protoplasm of the opened cells becomes interrupted by the interpolation of cells between those bounding it, the newly formed cells so interpolated becoming conjoined from the opposite sides of the incision in the intervals of the broken line, and as this process proceeds the remains of the original line of protoplasmic sacs become at length so widely and irregularly disparted as to render the original course of the incision untraceable in the scar-tissue.

[1] There is no special term to obviate this cumbrous expression. I use it to signify the thin sac of protoplasm lining the cellulose wall and holding the cell sap. H. von Mohl's designation of utricle is obsolete.

[2] The best method of performing the first test is to examine the section in water without a cover-glass, then to drain off the excess of water and add a drop of pure hydric sulphate from one side whilst the specimen is still under observation; by this means the uniform and full action of the acid is ensured. The iodine and hydric sulphate test is best performed in a similar manner, by allowing the iodine solution to act first, draining off the fluid, and then running a 75 per cent. solution of hydric sulphate down to the section, whilst it is watched beneath the microscope without the use of a cover-glass.

In fig. B, Plate XIV, is represented a far advanced stage in the process described, as seen in the healing of a closed longitudinal incision carried through the cortical parenchyma and deeper parts in the young internodes of *Aucuba japonica*. This interruption of what appears in a horizontal section as the line of incision takes place in all directions of growth, *i.e.* it occurs vertically as well as transversely; this may be recognised in horizontal sections by the fact that in the spots where the cells are continuous in the intervals of the broken line of incision, a change of focus may bring into view other segments of adpressed elements. That the absence of cork-formation is not due to any inability on the part of the tissue to produce it is proved in several ways. The cortical parenchyma of Aucuba, like that of all exogenous shrubs and trees, heals most readily in open or gaping wounds by an elaborate formation of cork-tissue; in closed incisions cell-division occurs without it. But not only do shrubs and perennials, but all annuals possess the power of producing cork-tissue from their parenchyma in the repair of open wounds. In the Kohl-rabi, in which a closed incision will heal without the intervention of cork, if the incision gape widely throughout, each of its faces heals as in an open wound, viz. by the formation of cork-tissue. In such annuals, for example, as Phaseolus, Tropæolum, Reseda, well-pronounced cork-formation obtains in open injuries; the observation is most conveniently made by slicing away a young leaf and axillary bud close to or flush with the parent stem, and examining the amputated surface by longitudinal section after the termination of growth.

The cell-division along the sides of the incision is much more regular or systematic in some instances than in others. Sometimes the cells divide regularly in planes parallel with the face of the incision, and form tiers of muriform elements on either side of the wound; the best example I have seen of this is in the Kohl-rabi; and in less marked manner it occurs in the medulla of the young branches of *Aucuba japonica*. In certain plants the scar-tissue in this method of healing undergoes sclerosis. The formation of sclerenchyma in the repair of open wounds I will notice presently, but it is rarely that it occurs in the healing of closed incisions.

In Kohl-rabi, for instance, the new-formed flattened cells bounding the line of a closed incision often undergo thickening, and this, it may be, for a depth of many layers. This sclerosis affects only the innermost of the flattened cells noticed, and not those that break

the line as the growth of tissue proceeds (fig. B, Plate XIII, and fig. A, Plate XIV).

In the young internodes of weeping ash (*Fraxinus pendula*) still more marked sclerosis of the subdividing medullary cells takes place on either side of the line of a protected longitudinal incision. I have not seen actual union ensue in the medulla, though in the cambium and cortical parenchyma it may be complete, but the scar-tissue in the latter situations presents no sclerosis; it is noteworthy that the normal medullary cells, although thin-walled, are to a slight degree pitted from secondary thickening.

The most superficial parts of a longitudinal incision often heal like the surfaces of open wounds in the same plants, viz. by cork-formation, since they often gape and undergo drying even when protected in the manner described in the earlier part of this paper. In the young branches of *Aucuba japonica* the gaping margins of the superficial portion of the cortical parenchyma heal by regularly disposed layers of cork-cells produced in tiers by division of the original parenchymatous cells, which form a secondary meristem or cork cambium, and in the cork itself will be found a line of not very regularly arranged sclerenchymatous cells.

In the gaping edges of perforating incisions in some Cactaceæ (Cereus, Echinocactus, Opuntia) a line of sclerenchymatous cells is sometimes met with in the substance of the reparative cork, with the tabular cells of which they correspond in form, and between which they lie. Such thickened cells are differentiated from those of the cork cambium. This may be traced in sections made at a suitable stage, when no cork-cells lie beneath them; as the further formation of cork proceeds from the cambium, the sclerenchyma is cut off from the latter, and comes to lie in the midst of the suberous tissue.

In these cases the original walls of the thickened cells will be found to have undergone a chemical change, and to remain uncoloured blue by the iodine and hydric sulphate test, as well as unaffected by pure hydric sulphate. As the section exposes the original wall to the action of the reagents, it cannot be that the absence of ensuing change results from any protection afforded to the cell wall by the secondary thickening. In those instances, however, in which sclerenchyma is formed in the process of repair, it is formed in the same plants under more natural though allied conditions. In the older parts of the stems of the species of Cactaceæ first named, for instance, the surface is constituted by layers of flattened cork-

cells in place of, or rather beneath the original epidermis, and in the deeper part of this cork there lies a single or double line of sclerenchymatous cells of similarly flattened tabular form. After experimental amputation of parts of these plants, also, the divided surface heals in the same manner beneath a scab or crust of withered cells. A formation of sclerenchyma obtains also in the stratified covering of cork which heals the gaping edges of perforating incisions in the aërial roots of Philodendron; and a similar mode of repair is of regular occurrence in the same roots after amputation, as well as beneath the dead ends or parts of such, separating the necrosed tissue from the living. Sclerenchyma is to be found, in fact, in the cork covering the older roots independently of injury, and where the surface is smooth and otherwise natural.

Amongst exogenous shrubs and trees I have seen such a formation of sclerenchyma in connection with cork only in *Aucuba japonica*; here, again, it is of common occurrence, and may be observed in old leaf-scars, and beneath the rough raised blackish areas frequent on the branches and due to injury, as well as in the reparative cork formed when a young internode has been shed after being killed experimentally by amputating close below a pair of axillary buds.

In the last-mentioned experiment, the internode slowly dies, and is cleanly disarticulated immediately above the buds next below it, one of which has in the meantime grown out into a branch (Fig. 22).

The surface left after such a disarticulation will exhibit in vertical section the following structure:—a zone of cells three deep or so of tabular or muriform cork, a line of sclerosed cells continuous though somewhat irregular in their course, and beneath this a tabular phellogen and phelloderma passing into the general ground tissue of the medulla and cortical parenchyma; the thickening affects chiefly or only that wall of the cell which is farthest from the free surface. Why more cells than those actually laid open in exposed wounds die is not clear; possibly the free exposure of the intercellular system of spaces leads to rapid drying in the unopened cells for a short distance below the surface, and so to their death; for not only is the exposure so resulting far greater than that which occurs through stomata, but there exists no means by which transpiration may be regulated.

The starch granules escaping into an incision from the divided cells remain unchanged. If an incision be made into the cotyledons

of *Faba vulgaris* when germination has commenced, and the cotyledons be examined by sections after they have begun to waste, it will be found that whilst all the starch of the cells has been used up during germination, starch granules exist abundantly in the course of the incision in the remains of the cells laid open; the starch is here beyond the range of the living cell processes concerned in metabolism, and remains undissolved and unchanged. Repair in the cotyledons is of the smallest kind; here and there an enlarged cell projects into the incision, but the cell walls along its sides undergo no suberous change.

FIG. 22.

Aucuba Japonica, after amputation of a young internode a short distance below a pair of axillary buds, showing the stump remaining after the shedding of the internode; to its left is a dormant axillary bud, to its right a branchlet which has grown from the opposite bud after the pruning referred to.

After longitudinal incision in the growing branches of *Aucuba japonica* I have seen starch lying in the line of injury forty-eight days after the experiment, at which date healing had taken place by the union of the cells formed on the opposite faces of the incision. In the branches of Pelargonium, after amputation, it may also be observed that the starch granules remain in the ground-tissue close beneath the cut surface, the cells of which rapidly die, whilst there is none in the stratified cork and cork cambium, which have been produced from cells in which starch was previously stored. When

tissue death is slow, starch is removed from intact cells. If the end of a growing branchlet in *Aucuba japonica* is cut away in the spring at a spot close below a pair of leaves and their axillary buds, the internode which now terminates the branchlet dies for its whole length, and is cleanly shed close above the pair of buds below, one of which grows out to reproduce what is lost (Fig. 22).

The internode becomes slightly wrinkled, loses somewhat its green colour, and in this condition, like that of the petiole of many deciduous leaves, it is cleanly shed, the microscopic details of the process being essentially the same as those which accompany the ordinary fall of a leaf. Before the internode is detached all the starch is removed from the medullary and cortical ground-tissues, as may be proved by slicing away portions from it at different periods during the time occupied in its separation. This removal corresponds with that of the starch in foliage leaves; whilst active the starch is periodically removed and renewed for the further use of the plant, but production at length ceases, and at the time of fall none is formed to replace what is consumed. This removal of starch takes place on a still more extensive scale in dead wood. In the dead portion of a branch no starch will be found, although it may be present in abundance in the living part below the limit of the dead, in the cells of the medullary rays and woody parenchyma as well as in the medulla and cortical ground-tissue.

To return to healing by primary adhesion. Besides the case described in which healing occurs without any separation of the divided surfaces, it often happens that separation results from the tension of the divided tissues. The effects of tension as witnessed on longitudinally bisecting, &c., a growing exogenous stem or young branch are well known; as far as they concern the faces of a longitudinal incision they may be readily observed in the growing internodes of *Faba vulgaris* or *Helianthus annuus*. If a longitudinal diametrical incision be made in an internode, but not so as to perforate it completely, it gapes for its whole depth; and the same happens if the incision be extended so as to traverse the entire thickness of the internode. The degree varies in different plants; longitudinal incisions in the young internodes of *Aucuba japonica* exhibit very little.

In the medulla itself there exist unequal tensions, the longitudinal tension being greater centrally than peripherally. If the medulla of Helianthus be completely isolated, and then split longitudinally, the

halves curve away from each other, as do the halves of the stem itself when similarly bisected; if in an isolated portion of medulla a vertical incision be made into the horizontal face of one end, so as to leave part of the periphery entire, the divided surfaces recede from one another, becoming concave; the same ensues if a moderately thin horizontal slice is completely divided diametrically: if in an internode longitudinally bisected, the medulla be incised longitudinally, the faces of the incision recede from one another; if the incision be horizontal its faces remain in apposition.

The healing by primary adhesion which occurs when the deeper parts of a longitudinal incision are separated by tension may be followed in the young stem of *Faba vulgaris* by starting several experiments together and examining the daily stages. Immediately after incision, which was made with a lancet, goldbeaters' skin was wrapped round the part, and a noose of silk lightly tied over the centre of the wound.

The tissues were hardened, as in other cases, in Kleinenberg's picric acid solution, and afterwards in three changes of alcohol of increasing strength. After *twenty-four hours* horizontal sections of the young stem show gaping of the surfaces of the medulla, and it may be of the deeper part of the cortical parenchyma; the amount of apposition in the cortex is variable, doubtless from slight differences in the tightness of the dressing. The line of incision on either side of the gap is sharply defined, and has a look at first suggesting suberisation of the walls of the intact cells bounding the incision.

Careful testing of sections with pure hydric sulphate shows, however, that no suberisation occurs, and that the sharpness of the line is due to the collapsed segments of the protoplasmic sacs which remain closely adherent to the walls of the opened cells; under the action of the reagent mentioned the cellulose wall swells up beneath the unaffected protoplasm. In those parts where the faces of the incision are in strict apposition the remains of the protoplasm are compressed between the walls of the cells bounding the injury, the line of which is thus constituted by a double wall of cellulose, including between its layers the thin compressed segments of the opened protoplasmic sacs.

Cell division may in some cases be observed in the ground-tissue at this period; the cells which bound the incision may be here and there once divided in a plane parallel with it, and similar division may have proceeded in the cells more immediately subjacent. In

the interfascicular cambium, if crossed by the incision, cell multiplication is more rapid; small clavate or hemispherical cells may project out from the cambium and nearly fill any interval between the divided parts in this situation. Should the edges of the incision through the interfascicular cambium be in apposition, as sometimes happens, the line of adpressed walls pertaining to the opened cells of the cambium may be broken through by the new-formed cells, which thus effect a rapid but not an "immediate" union in this situation. After *two days* the cell division of the ground-tissue and interfascicular cambium has proceeded to a greater degree, the line of incision being interrupted by projecting cells; in the gaping medulla the incision is on either of its sides rendered irregular at spots by large clavate cells, without the space being as yet bridged across. After *three days* some of the projecting cells of the callus in the medulla may be five times in length what they are in breadth, protruding far into the interval left between the receding edges of the incision; these enlarged cells themselves also undergo subdivision.

The cortical ground-tissue in some cases heals without separation of its surfaces; should its deeper part gape, the interval may be loosely filled with elongated cells growing out from the faces of the incision. In the cambium complete union has occurred. After *five days* healing is completed except in the centre of the medulla, where the interval is greatest, most of the space being filled with large loosely applied cells. The original thin line of the remains of the opened protoplasmic sacs is recognisable in small fragments lying scattered about the outskirts of the new tissue, the extent of which is recognisable by the large size and grotesque forms of its cells. The action of pure hydric sulphate shows that the cells of the reparative tissue have ordinary walls of cellulose.

The absence of cork formation arises from the protection afforded.

That the parenchyma in *Faba vulgaris* is capable of producing cork is readily proved by stripping off pieces of the epidermis, by amputating the young stem, or half dividing it horizontally, when the wound gapes so widely that no union subsequently occurs.

Under these various circumstances the injuries heal like open wounds in general, viz. by cork formation from the ground tissue, and from the cambium if the latter is involved. In Faba, however, amongst annuals, the formation of cork tissue (as I have noticed in the 'Linn. Soc. Journ.,' vol. xix) is not very pronounced. The cells divide only to the second or third degree, there is no orderly zone of cork cambium, and the lower limit of the cork is not straight but

DESCRIPTION OF PLATE XIII.

Illustrating Mr. S. G. Shattock's paper on "Healing of Incisions in Vegetable Tissues." (Page 387.)

From drawings by the author.

FIG. A.—Philodendron; aërial root. (× 100.) Horizontal section showing the union proceeding in the outer gaping part of the cortical ground tissue after longitudinal incision. [Secondary adhesion, or third intention.] The two faces of the wound are bounded by tiers of flattened cork cells; the innermost are of large size, irregular in form, and unite the deeper part of the incision.

FIG. B.—The left-hand segment of Fig. A, Plate XIV, more highly magnified (q. v.). (× 100.)

FIG. C.—*Ficus carica.* (× 100.) Medulla of a young internode. Horizontal section showing the healing of a longitudinal incision attended with separation of the faces of the wound, but carefully protected.

The interval is filled with large callus cells in process of sclerosis; beneath these is a smaller-celled scar tissue, the part of which nearest the wound is also sclerosed. No cork has been produced. [Primary adhesion, or first intention.]



Fig. A.

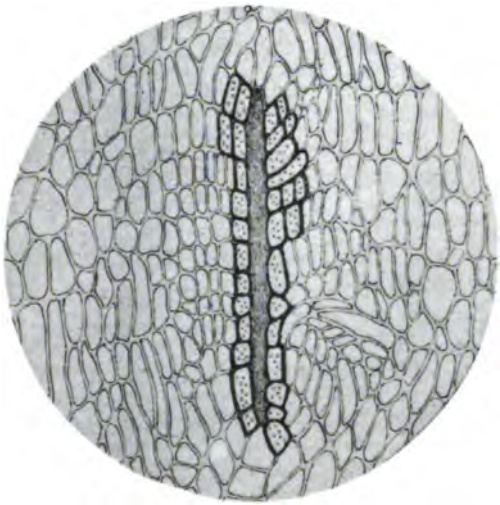

Fig. B.





Fig. A.

Fig. B.



DESCRIPTION OF PLATE XIV.

Illustrating Mr. S. G. Shattock's paper on "Healing of Incisions in Vegetable Tissues." (Page 387.)

From drawings by the author.

FIG. A.—Kohl-rabi. Horizontal section of a healed longitudinal incision. (× 50.)

The cells on either side of the incision have undergone subdivision; those bounding it are sclerosed. The line of incision has been broken into segments by the intrusion of the growing ground-tissue. Two such segments are shown in the figure.

The narrow interval between the lines of sclerosed cells is occupied by the remains of the cells opened by the lancet, and the cell contents.

FIG. B.—*Aucuba japonica*, young branchlet. Horizontal section showing the completed healing of a longitudinal incision by primary adhesion or first intention. The surface has slightly gaped, and the tissue is here covered with a stratified layer of thin-walled cork cells in place of the normal epidermis. In the deeper part of the cortical parenchyma the incision is traceable by means of the compressed remnants of certain of the cells originally opened by the lancet. The parenchyma from the cork to the cambium is of smaller and less regularly formed cells along the site of the injury—scar tissue.

No trace of the injury is detectable in the cambium or most newly produced wood, although the incision reached the medulla. (× 100.)

FIG. C.—Horse-chestnut, showing union of the cork-covered callus over a denuded surface of wood. [Third intention.] The latter is represented in longitudinal section at the south of the figure. The cork which originally covered each process of callus has been broken through by the growing cortical parenchyma or ground-tissue of the callus; a portion of the cork remains on the deep aspect of the callus, the rest covers its outer free surface. The wood of the callus has not yet advanced into the continuous parenchyma.



Fig. A.

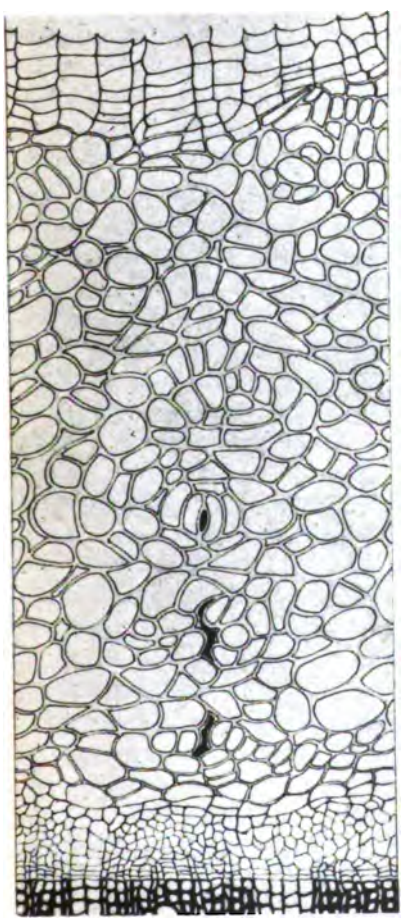

Fig. B.

Fig. C.

irregular. The callus is formed in chief amount from the cambium, after hemisection or amputation of the young stem, its more superficial cells becoming suberous if the plant is grown under ordinary conditions; but no extension of this callus follows over the exposed medulla in Faba or any other annual, nor does it form an observable macroscopic feature as in exogenous shrubs and trees.

That the incentive to suberisation of the cell wall is the drying due to exposure appears also from the fact that no cork is found bounding the medulla in plants where the latter is normally ruptured during growth, as in Taraxacum, Dahlia, Helianthus, Faba. Not only is there no reparative formation of cork in these circumstances, but no chemical change takes place in the wall of the entire cells bounding the cavity. In the stem of *Carduus eriophorus* I met with an interesting illustration of the influence exposure has in determining the formation of cork. The stem is naturally hollow with horizontal dissepiments. After amputation of the growing apex the surface healed as usual by means of a production of cork tissue, but the central space below the first dissepiment presented an exactly similar lining of cork; and on looking carefully I discovered a small circular aperture in the partition which closed it above: the lower spaces in the stem, which were securely shut off, presented no cork formation whatever.

In the petiole of *Rheum rhaponticum* the union of longitudinal incisions is hindered by a coagulable effusion which escapes, also, externally like the blood from a wound in animal tissues. This effusion solidifies quite apart from drying, and is obvious to the naked eye in a freshly cut horizontal section of the healing petiole. It is probably of the same nature as that which exudes from the cut surface of the fruit of *Cucumis sativus*, or the stems and petioles of *Ecballium officinale*, where it is shed from laticiferous vessels. The nature of this coagulation is a subject needing physiological investigation; and it is surely interesting to note that John Hunter, in his museum, had placed preparations of coagulated vegetable fluids by the side of coagula of blood.

The immediate result of longitudinal incision in the young petiole is separation of the whole of the surfaces from tension; at the fibro-vascular bundles the separation is least, and where such are divided longitudinally they project from the faces of the wound. Horizontal sections after the completion of growth show to the naked eye in the line of injury, a series of narrow elliptical areas of

transparent coagulum, in the intervals between some of which, and at the more superficial parts, the tissues are continuous (Fig. 23). The coagulum holds the parts together nearly as firmly as the new tissue itself. The entire mode of repair resembles that already described in the young stem of *Faba vulgaris*. In Rheum union occurs chiefly where the incision has traversed a vascular bundle; for here not only is the separation of surfaces least, but the callus produced by the soft bast or cambiform tissue of the bundle is more

FIG. 23.

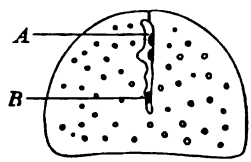

Rheum rhaponticum. Petiole after longitudinal incision. Horizontal section. Except at the surface the faces of the wound are separated by coagulated latex, A. At B, all union has taken place in the situation of a divided fibro-vascular bundle. (Natural size.)

exuberant than by the general ground tissue: sometimes union takes place between the large-celled callus of the latter, and the smaller celled derived from a bundle just exposed on the opposite face of the incision. The individual cells may be of great length, and project far into the coagulum. The process observed in the petioles of *Rheum rhaponticum* bears a comparison with that in which blood is effused into an incision in animal tissues. The blood delays union since it is itself incapable of further development, and in the repair the clot is removed by the granulation tissue which extends into and consumes it. this tissue undergoing subsequent development into the fibrous tissue of the cicatrix. In open wounds, also, there is at times an equally close resemblance between animal and vegetable tissues. For example, after pruning away the young leaves in *Ecballium officinale* close to the growing stem, the latex effused over the cut surface coagulates, and then dries into a glassy film, beneath which the ground tissue subdivides to produce a cork cambium and cork, the process being much like that in which an open wound in man heals beneath a dry scab of blood or of lymph effused over and coagulated upon its surface.

In repair without separation of surfaces the innermost of the new cells in exceptional instances undergo sclerosis; this I have already

described in the Kohl-rabi. The same holds true where a projecting formation of new tissue, or callus, fills the gaping parts of a protected incision. This sclerosis of the callus cells invariably occurs in the medulla of the young internodes of *Ficus carica* (fig. c, Plate XIII).

The cells along the sides of the gaping cleft divide more or less regularly in planes corresponding with that of the incision.

Before repair commences, the remains of the cells opened by the lancet are easily recognisable bounding the living ground tissue, none of the elements of which die other than those actually cut open.

In the first stage, certain of the intact cells along the incision undergo remarkable overgrowth, becoming clubbed or pyriform, with their larger ends projecting into the space; these meeting with similar cells from the opposite side, the interval comes to be filled with a delicate parenchyma of large cells separated by wide intercellular passages, which disappear as the cells become more compactly pressed together. Cell division takes place also beneath the divided surfaces, as in cases where there is no interspace to be filled. In Ficus both the callus cells and the smaller celled tissue beneath undergo sclerosis.

When in the branch of an exogenous shrub or tree, a longitudinal incision traverses the cortex and fully formed xylem, no repair of the latter ensues; nor does any, of course, take place in the medulla if its tissue is dead at the time of the experiment. But in the case of incisions made into young internodes, healing of the cortical parenchyma, cambium, and bast may occur by the method of primary adhesion described; this only happens when careful protection is afforded so as to prevent drying and shrinkage; I have followed it in *Aucuba japonica, Prunus lauro-cerasus, Fraxinus pendula.* In the young internodes of Aucuba, after complete perforation with a narrow-bladed lancet and careful subsequent protection, the incision in the medulla will heal, with or without separation, by the methods already described, and without cell sclerosis, except in the immediate neighbourhood of the xylem; in the cortical parenchyma it will be just traceable by a few disparted fragments of adpressed protoplasmic sacs and remains of divided cell walls; at the very surface the edges gape, and are healed by cork and sclerenchyma. But neither in the cambium nor in the wood, after the completion of the season's growth, will there be any trace of the

incision. Such a perfect result happens only when the youngest internodes are used, and at a period when microscopic examination shows that no woody prosenchyma has yet been differentiated from the cambium. In the young branches of *Fraxinus pendula* I have observed similar perfect repair, except in the wood already formed prior to the experiment:—in the cortical parenchyma and bast parenchyma, disparted segments of cell-remains, on the sides of which are groups of flattened cells; in the cambium and chief part of the xylem no trace of the injury; the deepest part of the xylem unhealed and in apposition. Fully formed woody tissue is incapable of repair, but the healing of the cambium being readily effected, the wood subsequently produced is formed in continuity.

Union of the medulla, if the faces of the incision remain together, can only take place when the xylem is at an early stage of development, seeing that this involves a disruption of the line by the intercalation of new cells; if the woody tube is completed, this is impossible. Hence, in the above-cited experiment on Fraxinus, the incision in the medulla is not repaired; the first row or two of entire cells bounding it undergo division, and in addition subsequent sclerosis, but the line is not broken through.

Healing of Incisions by Secondary Adhesion.

This term is applied in animal pathology to signify the healing that ensues upon the bringing together of two open granulating surfaces. The process that may be compared with this in plant repair is that in which two free surfaces, after healing has advanced to a certain degree, come to meet one another and unite.

In plants the process differs from that which I have compared with primary adhesion in that the surfaces, being freely exposed before they meet, are healed by cork tissue; in primary adhesion no cork is formed. Union by secondary adhesion presents two varieties; in one it takes place between the cork which covers the two faces of the incision, in the other by means of its disruption. The first is possible only when the cork tissue forms the actual surface, and is not produced at a depth beneath a crust of dead cells; the cork cells, too, must be living. The apposed cells simply cohere, in the same way that those with walls of cellulose do in primary adhesion; there is no indication of the production of an intercellular connecting substance.

I have observed direct union of cork tissue in the aërial roots of Philodendron. If a longitudinal incision perforating the entire thickness of the aërial root is allowed to gape, this method of repair may be found. To cite the notes of an examination: Cortical parenchyma, no union of the more superficial part of the incision; repaired by tiers of cork cells of flattened brick-like form, but the most superficial cells of each tier are of large size, hemispherical or pyriform; in the deeper part of the cortical parenchyma the interval is filled and healing completed by the union of the large irregular cells of cork noticed. Pure hydric sulphate proves the uniting cells and subjacent tiers to be chemically perfect cork (fig. A, Plate XIII).

In places, however, in the cortex, the cork after having met and united is broken through by the growing ground tissue, as described later on under the second variety of healing. The incision in the woody core heals in the same way, but the elements of the reparative tissue are smaller, since the parenchymatous cells producing them, and among which the vascular bundles lie, are smaller than those of the cortical ground-tissue beyond the pericambium.

In other specimens of incised Philodendron root I have seen healing without cork formation, the cortical parenchyma uniting by a large-celled callus, and pure hydric sulphate shows this to be cellulose throughout; the parenchymatous tissue of the woody core healing by the same method. The differences in the repair of the same tissues depend doubtless upon differences in exposure, open wounds of the roots, such as those of amputation, readily healing by the development of cork.

In the second variety of healing by second intention, no union happens between the cork which invests the two surfaces.

One of the best instances of this which I have observed was in the case of longitudinal incisions carried completely through the stem of Echinocactus, and when from wide gaping of the wound the faces of the injury had dried. Each surface heals as in an open wound by the development of flat-celled phellogen and cork beneath a crust of withered cells. But as growth proceeds, the faces of such an incision sometimes come to meet, and after this no further growth of cork takes place, for this tissue being essentially protective, no further physiological demand for it arises. At one stage the course of the injury is to be traced with the unaided eye by the thin brown line of withered cells pressed together from the sides of the incision, and on either side of this by an uncoloured semi-transparent zone,—

the area in which cell division is proceeding, and the macroscopic characters of which arise from the new tissue being devoid of chlorophyll and starch, and containing no intercellular spaces.

At a later stage the double zone of muriform cork tissue becomes disrupted, or broken into segments as growth proceeds, by the intrusion of cells from the surrounding ground-tissue. The cork is segmented in both vertical and transverse directions, *i.e.* in a centrifugal manner in the plane of section, but without its apposed surfaces in the different segments being themselves separated (Fig. 24).

FIG. 24.

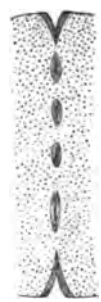

Echinocactus. Horizontal section, illustrating the mode in which the cork covering two surfaces of a gaping unprotected incision is subsequently broken through by the growing ground tissue. "Secondary adhesion." (Semi-diagrammatic.)

The same process ensues in the completion of the healing which obtains in exogenous shrubs or trees after open wounds attended with loss of bark, whether due to pruning, ringing, or other injury. Under all these circumstances it is a matter of common observation that there occurs a growth of reparative tissue or callus from the cambium. The divided edge of the bark dies, together with a certain depth of the exposed wood, and over the dead surface of the wood the callus advances from beneath the dead edge of the bark.

In a vertical section the callus is seen to be constructed of a deeper woody portion covered exteriorly with a cortical system, these being continuous, the first with the new wood formed during the same period beneath the general bark, the second with the deepest layer of the newly formed phloem. No adhesion takes place between the callus and the dead wood over which it is advancing, though they are most accurately and closely applied, the new tissue filling

in its advance every inequality of the dead wood, its individual cells adapting themselves to the microscopic irregularities of the surface. Passing over the detailed histology of the callus and the mode of its first formation from the divided cambium, it is enough to observe in connection with the present subject that the callus itself is covered with well-formed cork similar to that of the general bark. Each year the callus advances and grows in thickness, until at length the whole of the bare wood is covered, the new tissue meeting at or near the centre of the denuded area; after "ringing," as is generally known, the growth of callus on the distal aspect is more exuberant than on the proximal, or the side towards the root. The parts which first come into contact are the advancing edges, and

FIG. 25.

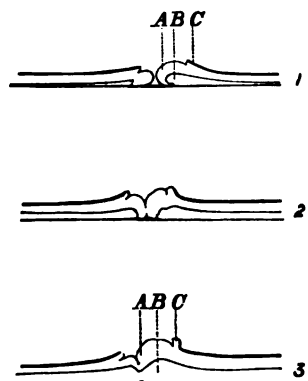

Fraxinus pendula. Longitudinal sections, showing the union of the callus advancing over the denuded wood after "ringing."

1. The two processes of callus nearly in apposition, the larger from the distal side of the branch.
   (*A*) Cortex of the callus covered with cork.
   (*B*) Wood of the callus continuous with that formed during the same period around the branch.
   (*C*) Divided edge of the original bark from beneath which the callus has developed from the cambium.
2. A later stage. The cortex of the two processes has become continuous after rupture of the investing cork; the wood of the callus is as yet discontinuous.
3 The completed stage, showing the continuity of the new wood. (Natural size.)

over these the cork, though fully developed, is not accumulated as upon the older portions of the callus on which a yearly increment

has occurred. Now the interesting point is that after this contact the cortical ground-tissue of the callus becomes continuous. This result is brought about as described in Echinocactus. Cork tissue ceases to be produced at the site of contact, and as growth proceeds the double zone of cork is here broken through by the subjacent parenchyma (Fig. 25).

A microscopic section made at this stage will show a portion of the cork lying between the deepest aspect of the callus and what was once the exposed surface of the wood; but the cork here is no longer continuous with that investing the superficial part of the callus; the continuity is destroyed by an isthmus of cortical parenchyma (Plate XIV, fig. c).

After this fusion of the ground tissue the wood and phloem are formed in continuity, and from the surface of the wood once exposed may then be raised a continuous cap of tissue passing peripherally into the deeper part of the general cortex and the more superficial layers of the general wood. The continuity of the cambium in the coalesced callus is brought about by the formation of secondary meristem in the intervening part of the cortical ground-tissue.

After portions of the bark have been removed from the trunk of an exogenous tree, the covering of the bare dead wood is occasionally expedited by a growth of callus from the medullary rays, even if the dead surface is of considerable extent, as I have observed in the Elm and Plane. From the situations of the medullary rays there arise by narrow bases of attachment hemispherical or oval outgrowths arranged in longitudinal and parallel lines. These, as microscopic sections show, result from proliferation of the cells of the medullary rays; and though at first only parenchymatous there is differentiated later, as in the callus formed after "ringing," &c., most deeply a woody parenchyma, and upon this prosenchyma and vessels, to which succeed a cambium and cortical system covered with cork tissue. Such outgrowths of cork-covered callus as they extend in area come to coalesce with one another, and with that which arises from the cambium beneath the edge of the dead bark, the coalescence being by the method of secondary adhesion which I have described.

In the operation of "budding" this production of callus from the medullary rays of the stock is of regular occurrence, the callus so formed uniting with that from the under side of the "bud."

Union by secondary adhesion plays an important part in grafting. In the commonly adopted method, where the stock and scion are

cut obliquely and bound together under a composition to restrain drying, my own observations made on specimens at different stages show that cork-covered callus is produced from the cambium beneath the bark, and none from the divided wood itself, between which there is often a narrow interval into which the callus insinuates itself and which it fills.

The callus of stock and scion unite as I have described after ringing, the wood subsequently formed coming to be continuous as in the latter case. The thin layer of parenchymatous callus between the original wood does not undergo subsequent differentiation, so that no woody union takes place between the surfaces of stock and scion originally divided.

The process of secondary adhesion, accompanied with disruption, depends essentially upon the fact that the cork which heals the exposed surfaces has formed beneath a crust of withered cells, and no union can take place between two dead surfaces; or that from lapse of time the more superficial cells of the cork investing the callus have died and become filled with air.

Brief comparison between the repair in plants and in animal tissues.

The methods of repair of incisions are comparable to those named primary and secondary adhesion in man and the higher animals. The analogy with that of secondary adhesion is not, however, an exact one, for this reason, that the two surfaces concerned in animal repair do not strictly heal before they are brought in apposition, but remain "granulating," whereas the exposure of the surfaces in plants is accompanied with a repair by cork before the subsequent fusion takes place. There is, in fact, nothing in the repair of animal textures exactly resembling this process in plants.

In the case of plant repair, the new tissue is derived solely from that bordering the wound.

In animal tissues the repair is complicated by the part played by the blood-vessels, for every injury is attended with what is histologically an initial inflammation, and this involves the migration of leucocytes from the vessels into the faces of the incision.

In plants the proof is direct that the whole of the repair is effected by the original cells of the part injured; there is obviously nothing resembling a migration of cells from any circulatory system.

Observation has shown that in animal textures the repair of nerve and muscle is accomplished by the elements of the original structures. The connective tissue offers the most difficult field for this determination; until recently no direct observations were forthcoming to show whether the connective-tissue corpuscles by their subdivision produce the proper reparative tissue, viz. that from which the fibres of the scar are developed, or whether the migrated leucocytes take part in its production. The evidence at present tends to show that the leucocytes take no permanent part in repair, *i. e.* that the scar-tissue properly so called is produced from the connective-tissue corpuscles,—a conclusion I surmised would prove true some years ago from investigations into the repair of vegetable tissues. In this result the reparative process in animals corresponds with that in plants, viz. that it proceeds not from any extraneous elements, but from the cells proper to the damaged tissue itself.

May 5th, 1896.

DESCRIPTION OF PLATE XV.

Illustrating Dr. Eyre's paper on "The Xerosis Bacillus." (Page 334.)

FIG. A.—Cover-slip preparation from culture of xerosis bacillus upon blood-serum (24 hours).

FIG. B.—Cover-slip preparation from culture of xerosis bacillus upon glycerine agar-agar (24 hours). Clubbing and segmentation of the individual bacilli are represented.

FIG. C.—Cover-slip preparation from culture of xerosis bacillus upon gelatine (10 per cent.) (48 hours).

All the above figures show the characteristic "clumps." The stain employed was aniline gentian-violet.



Fig. A.



Fig. B.

Fig. C.

INDEX.

PAGE

ABDOMINAL MUSCLES, congenital deficiency of (L. Guthrie) . . 139

ABSENCE of abdominal muscles (L. Guthrie) . . . 139

ACCESSORY THYROID BODY (Cyril Ogle) 224
„ cystic (W. Edmunds) 223
„ recurrent carcinoma of (A. E. Barker) 225

ADENOMA, exogenous, of thyroid body (S. G. Shattock) . . 231
„ of thyroid body, transformation into cysts (J. Berry) . . 234
„ of sebaceous glands (?) (H. D. Rolleston) . . . 242

ADRENAL TUMOURS OF KIDNEY (J. H. Targett) . . . 122

ANDERSON (WILLIAM), introduction to discussion on non-suppurative ankylosis of joints 193

ANEURYSM of axilla (J. Jackson Clarke) 24
„ of external iliac artery, cured (Douglas Drew) . . . 32
„ of heart (Cyril Ogle) 22, 23
„ — (J. Jackson Clarke) 24
„ of inferior thyroid artery (J. R. Lunn) 30
„ multiple embolic (J. Jackson Clarke) 24

ANKYLOSIS OF JOINTS, non-suppurative, discussion on . . 193

AORTA, abdominal, rupture of inner coat of (A. F. Voelcker) . . 33
„ syphilitic disease of valves of (P. H. Pye-Smith) . . . 26

APPENDICITIS, ulcerative, three cases of (W. Hunter) . . 49

APPENDIX CÆCI, containing a concretion (W. J. Tyson) . . 51

ARKLE (C. J.) and HINDS (F.), pneumonomycosis . . . 8

ARTERY, coronary, embolism of (Cyril Ogle) . . . 29
„ — occlusion of (F. Parkes Weber) 16
„ — stenosis of (F. Parkes Weber) 18
„ — thrombosis of (F. Parkes Weber) 14
„ external iliac, cured aneurysm of (Douglas Drew) . . . 32
„ inferior thyroid, aneurysm of (J. R. Lunn) . . . 30
„ pulmonary, atresia of (Cyril Ogle) 28

ATRESIA of pulmonary artery (Cyril Ogle) 28

ATROPHY of kidney from stricture of ureter (G. N. Pitt) . . 113

AXILLA, aneurysm of (J. Jackson Clarke) 24

PAGE

BACILLUS DIPHTHERIÆ and *pseudo*-diphtheria (E. A. Peters) . 345
„ cultivation from throat twenty-two weeks after primary attack (R. T. Hewlett) 360
„ escape of, into the blood and tissues (A. A. Kanthack and J. W. Stephens) 361

BACILLUS OF XEROSIS CONJUNCTIVÆ (J. Eyre) . . . 334

BANDS, rare method of formation of intra-abdominal (J. Hutchinson, jun.) 100

BARKER (A. E.), recurrent growth of cystic accessory thyroid body . 225
„ *Report* of the Morbid Growths Committee on the above (J. Berry, A. A. Bowlby, and S. G. Shattock) 229

BEADLES (CECIL F.), carcinomatous cysts of the breast . . 278
„ relation of biliary calculi to malignant disease of liver and gall-bladder 69
„ syphilitic gummata of the brain 1

BERRY (JAMES), results of radical cure of hernia . . . 56
„ transformation of solid adenomata of thyroid body into cysts . 234
„ *Report* on Mr. Barker's recurrent growth in accessory thyroid body . 229

BILIARY CALCULUS impacted in small intestine (J. Hutchinson, jun.) . 94
„ relation of, to malignant disease of liver and gall-bladder (C. F. Beadles) 69

BLADDER, colloid carcinoma of (H. C. Sharp) . . . 168
„ dilatation of, from absence of abdominal muscles (L. Guthrie) . 139
„ diverticula of, associated with growths (J. H. Targett) . . 155
„ growths of, in diverticula of (J. H. Targett) . . . 155
„ sarcomata of, and their classification (J. H. Targett) . . 291

BLOOD, presence of an undescribed form of hæmatozoon in (Norman Moore) 384

BOWLBY (A. A.), *Report* on Dr. Cyril Ogle's polypoid growth of trachea . 7
„ — on Mr. Barker's recurrent growth of accessory thyroid body . 229

BRAIN, gummata of (C. F. Beadles) 1
„ syphilitic disease of (C. F. Beadles) 1

BREAST, carcinoma of, associated with large cyst (H. D. Rolleston) . 284
„ carcinomatous cyst of, three cases (C. J. Symonds) . . 273
„ — (W. S. Sprent) 277
„ — (C. F. Beadles) 278
„ cystic disease of, with carcinoma (H. B. Robinson) . . 285
„ fatty concretions in, with chronic mastitis (W. Watkins-Pitchford) . 249
„ hæmorrhagic duct-cancer of (R. Morison) . . . 288
„ saponifying necrosis in lipoma of (J. H. Targett) . . . 248
„ sarcoma of, containing multinuclear giant-cells (H. D. Rolleston) . 267
„ — (metastatic) of, containing multinuclear giant-cells (E. L. Fox) . 269
„ — — of (H. D. Rolleston) 272

BRONCHUS, rupture of (H. W. Mackenzie) 5

BROWNE (LENNOX), malignant disease (epithelioma) of tonsil . . 34

BURSA, subdeltoid, loose bodies from (Jackson Clarke) . . 257

BUTLIN (H. T.), results of radical cure of hernia . . . 54

CÆCUM, caseous mass attached to (Hugh Walsham) . . . 48

CALCIUM OXALATE CALCULI from cyst of pancreas (S. G. Shattock) . 101

CALCULI. See *Biliary calculus.*
„ of calcium oxalate from cyst of pancreas (S. G. Shattock) . . 101
„ uric acid, spontaneous fracture of (C. B. Plowright) . . 132

PAGE

CARCINOMA, colloid, of bladder (H. C. Sharp) . . . 168
„ cystic, of the breast, three cases of (C. J. Symonds) . . 273
„ — of the breast (W. S. Sprent) 277
„ — — (C. F. Beadles) 278
„ with large cyst of the breast (H. D. Rolleston) . . . 284
„ and cystic disease of breast (H. B. Robinson) . . . 285
„ hæmorrhagic duct-cancer of breast (R. Morison) . . . 288
„ of colon, passage of mucous casts (P. H. Pye-Smith) . . 52
„ of ischio-rectal region of a fox terrier (C. S. Wallace) . . 290
„ of prostate (R. G. Hebb) 154
„ of spermatic cord (J. H. Morgan) 150
„ recurrent, of cystic accessory thyroid body (A. E. Barker) . . 225
„ simultaneous squamous-celled (H. D. Rolleston) . . . 241

CARDIAC ANEURYSM. See *Heart.*

CASTRATION for enlarged prostate (N. Davies-Colley) . . 152

CIRCULATION, organs of, diseases, &c., of 14

CLARKE (J. JACKSON), dermoid tumour of testis . . . 148
„ embolic aneurysms of heart, buttock, and axilla . . . 24
„ loose bodies from a subdeltoid bursa 257
„ remarks in discussion on non-suppurative ankylosis of joints . . 215
„ syphilitic lesions of lymphatic glands 257

CLASSIFICATION of sarcomata of bladder (J. H. Targett) . . 291

COLLIER (W.), multiple polypi of stomach and intestine . . 46

COLON, carcinoma of (P. H. Pye-Smith) 52
„ mucous casts of (P. H. Pye-Smith) 52
„ ulceration of, in enteric fever (A. F. Voelcker) . . . 54

COMMITTEE ON MORBID GROWTHS, *Reports* of, on Dr. Cyril Ogle's specimen of polypoid growth of the trachea (A. A. Bowlby and R. G. Hebb) 7
„ — — on Dr. Cyril Ogle's specimen of sarcoma of the œsophagus (W. G. Spencer and J. H. Targett) 41
„ — — on Mr. Morgan's specimen of malignant tumour of the spermatic cord (W. G. Spencer and J. H. Targett) . . . 152
„ — — on Mr. Barker's specimen of recurrent growth of cystic accessory thyroid body (J. Berry, A. A. Bowlby, and S. G. Shattock) . 229

CONCRETIONS, fatty, in breast (W. Watkins-Pitchford) . . 249

CONJUNCTIVITIS (xerosis), bacillus of (J. Eyre) . . . 334

CORD, spermatic. See *Spermatic cord.*

CRATERIFORM ULCER of face (H. D. Rolleston) . . . 240

CULTURAL VARIATION in *Streptococcus pyogenes bovis* (S. G. Shattock) 375

CYSTIC DISEASE of both breasts, with carcinoma in the right breast (H. B. Robinson) 285

CYSTS, carcinomatous, of the breast, three cases of (C. J. Symonds) . 273
„ — — (W. S. Sprent) 277
„ — — (C. F. Beadles) 278
„ with carcinoma of the breast (H. D. Rolleston) . . . 284
„ pendent within hernial sac (C. B. Lockwood) . . . 61

DAVIES-COLLEY (J. N. C.), glandular enlargement of prostate; castration 152
„ remarks in discussion on non-suppurative ankylosis of joints . 207

DERMOID TUMOUR of testis (J. J. Clarke) 148

PAGE

DIASTASIS of great trochanter (J. Hutchinson, jun.) . . . 174
DIGESTION, ORGANS OF, diseases, &c., of 34
DILATATION of the œsophagus (H. D. Rolleston) . . . 37
„ of the stomach (R. G. Hebb) 45
DIPHTHERIA of the œsophagus (E. W. Goodall) . . . 39
„ and pseudo-diphtheria bacilli (E. A. Peters) . . . 345
„ bacilli in cultivation from the throat twenty-two weeks after the primary attack (R. T. Hewlett) 360
„ escape of bacilli into blood and tissues (A. A. Kanthack and J. W. Stephens) 361
DISCUSSION on non-suppurative ankylosis of joints . . . 193
DISEASES, &c., of the ductless glands 223
„ — of the genito-urinary organs 113
„ — of the nervous system 1
„ — of the organs of circulation 14
„ — of the organs of digestion 34
„ — of the organs of locomotion 174
„ — of the organs of respiration 5
„ — of the skin 240
DIVERTICULUM of bladder associated with growth (J. H. Targett) . 155
„ of ileum of unusual length and position (Bilton Pollard) . . 47
„ — attached to mesentery (Hugh Walsham) . . . 48
Drew (Douglas), cured aneurysm of external iliac artery . . 32
DUCT-CANCER. See *Breast.*
DUCTLESS GLANDS, diseases, &c., of 223
DURA MATER, psammoma of (J. H. Targett) . . . 3

Edmunds (Walter), cystic accessory thyroid body . . . 223
„ observations and experiments on pathology of Graves's disease . 235
EMBOLISM of coronary artery (Cyril Ogle) 29
ENLARGED PROSTATE, castration for (N. Davies-Colley) . . 152
ENTERIC FEVER, ulceration of colon in (A. F. Voelcker) . . 54
EPIPHYSIS of great trochanter, separation of (J. Hutchinson, jun.) . 174
EPITHELIOMA, cystic, of liver (A. F. Voelcker) . . . 43
„ of the œsophagus (J. H. Targett) 41
„ — (A. F. Voelcker) 43
„ of an œsophageal pouch (G. N. Pitt) 44
„ of tonsil (Lennox Browne) 34
„ of ureter causing hydronephrosis (H. Rundle) . . . 128
Eyre (J.), on the xerosis bacillus 334

FACE, crateriform ulcer of (H. D. Rolleston) . . . 240
FAT-NECROSIS in hæmorrhage near pancreas (Cyril Ogle) . . 98
FATTY CONCRETIONS in breast with chronic mastitis (W. Watkins-Pitchford) 249
FATTY PATCHES in liver (F. P. Weber) 65
Fielder (F. J.) (per J. H. Targett), osteitis deformans . . 190

PAGE

FISHER (THEODORE) (per J. H. TARGETT), large white kidneys with thrombosis of renal veins and inferior vena cava . . . 113
„ bilateral sarcoma of hilum of kidney 115

FOX (E. L.) (per J. H. TARGETT), metastatic (?) sarcoma of both breasts, containing multinuclear giant-cells 269

FRACTURE of humerus followed by chondrifying sarcoma (S. G. Shattock) 261
„ spontaneous, of uric acid calculi (C. B. Plowright) . . 132

GALL-BLADDER, relation of biliary calculi to malignant disease of liver and (C. F. Beadles) 69

GALL-STONE. See *Biliary calculus*.

GARROD (A. E.) and HOPKINS (F. G.), the occurrence of large quantities of hæmatoporphyrin in the urine of patients taking sulphonal . 316

GIANT-CELLS in sarcoma of mamma (H. D. Rolleston) . . 267
„ — — (E. L. Fox) 269

GLANDS, lymphatic. See *Lymphatic glands*.
„ sebaceous, adenoma (?) of (H. D. Rolleston) . . . 242

GOLDING-BIRD (C. H.), case of infantile hernia in which radical cure was performed 56

GOODALL (E. W.), diphtheria of the œsophagus . . . 39

GRAVES'S DISEASE, pathology of (W. Edmunds) . . . 235

GREAT TROCHANTER, separation of epiphysis of (J. Hutchinson, jun.) . 174

GRIFFITHS (JOSEPH), remarks in discussion on non-suppurative ankylosis of joints 209

GUMMA of brain (C. F. Beadles) 1
„ of heart (Cyril Ogle) 23

GUTHRIE (LEONARD), deficiency of abdominal muscles; dilatation of bladder 139

HÆMATOPORPHYRIN, excessive quantities of, in the urine of patients taking sulphonal (A. E. Garrod and F. G. Hopkins) . . 316

HÆMATOZOON, undescribed form of (Norman Moore) . . 384

HÆMORRHAGE near pancreas, with fat necrosis (Cyril Ogle) . . 98
„ due to pyogenic micro-organisms (Raymond Johnson) . . 382

HEALING OF INCISIONS in vegetable tissues (S. G. Shattock) . . 387

HEART, aneurysm of (Cyril Ogle) 22, 23
„ — (J. Jackson Clarke) 24
„ from a case of angina pectoris (F. Parkes Weber) . . 14, 18
„ gumma of (Cyril Ogle) 23
„ occlusion of coronary artery (F. Parkes Weber) . . . 16
„ stenosis of coronary artery (F. Parkes Weber) . . . 18
„ — of pulmonary orifice (Hugh Walsham) . . . 25
„ thrombosis of coronary artery (F. Parkes Weber) . . . 14

HEBB (R. G.), carcinoma of prostate 154
„ dilatation of the stomach 45
„ *Report* on Dr. Cyril Ogle's polypoid growth of trachea . . 7

PAGE

HERNIA, femoral, hour-glass constriction of sac of (M. Laurie) . 59
„ infantile (C. H. Golding-Bird) 56
„ pedunculated cysts in sac of (C. B. Lockwood) . . . 61
„ results of radical cure (H. T. Butlin) 54
„ — — — (J. Berry) 56
„ — — — (C. H. Golding-Bird) 56

HEWLETT (R. T.), diphtheria bacilli in cultivation from the throat twenty-two weeks after the primary attack . . . 360

HINDS (F.) and ARKLE (C. J.), pneumonomycosis . . . 8

HOPKINS (F. G.) and GARROD (A. E.), the occurrence of large quantities of hæmatoporphyrin in the urine of patients taking sulphonal . 316

HUMERUS, fracture of, followed by chondrifying sarcoma (S. G. Shattock) 261
„ old injury of, from an Egyptian mummy (J. H. Targett) . . 174
„ chondrifying sarcoma of, following upon a fracture (S. G. Shattock) 261

HUMPHRY (Sir GEORGE), remarks in discussion on non-suppurative ankylosis of joints 201

HUNTER (W.), three cases of ulcerative appendicitis . . . 49

HUTCHINSON (J., jun.), gall-stone impacted in small intestine . . 94
„ rare method of formation of intra-abdominal bands . . 100
„ separation of epiphysis of great trochanter . . . 174

HYDRONEPHROSIS from epithelioma of ureter (H. Rundle) . . 128

HYPERTROPHIC PULMONARY OSTEO-ARTHROPATHY, pathology of (W. Thorburn and F. H. Westmacott) 177

ILEUM, diverticulum of (Bilton Pollard) . . . 47
„ — attached to mesentery (Hugh Walsham) . . . 48
„ tuberculous ulceration of, with perforation (Hugh Walsham) . 47

INCISIONS, healing of, in vegetable tissues (S. G. Shattock) . . 387

INTESTINE, biliary calculus impacted in (J. Hutchinson, jun.) . 94
„ polypus of (W. Collier) 46

INTRA-ABDOMINAL BANDS, rare method of formation of (J. Hutchinson, jun.) 100

ISCHIO-RECTAL FOSSA, malignant growth of, in a fox terrier (C. S. Wallace) 290

JOHNSON (RAYMOND), extensive hæmorrhages associated with the presence of pyogenic micro-organisms 382

JOINTS, NON-SUPPURATIVE ANKYLOSIS OF, DISCUSSION ON . 193
„ — introductory remarks by William Anderson . . . 193
„ — remarks by Sir George M. Humphry 201
„ — — Howard Marsh 203
„ — — Davies-Colley 207
„ — — Joseph Griffiths 209
„ — — D'Arcy Power 211
„ — — Charles A. Morton 213
„ — — Jackson Clarke 215
„ — — James H. Targett 216

JONES (ROBERT) (per D'Arcy Power), macrodactyly due to diffuse lipoma 252

JONES (SYDNEY), osteomata of scalp 255

PAGE

KANTHACK (A. A.) and STEPHENS (J. W.), the escape of diphtheria bacilli into the blood and tissues 361

KIDNEY, acute nephritis due to oxalic acid poisoning (Hale White) . 312
„ adrenal tumours of (J. H. Targett) 122
„ atrophy of, from stricture of ureter (G. N. Pitt) . . . 113
„ hydronephrosis from epithelioma of ureter (H. Rundle) . . 128
„ large white, with thrombosis of renal veins, &c. (T. Fisher) . . 113
„ lympho-sarcoma of (F. P. Weber) 117
„ misplaced, with uterus unicornis (A. F. Voelcker) . . . 173
„ sarcoma of hilum of (T. Fisher) 115
„ sarcoma of (J. D. Malcolm) 119

LAURIE (MACPHERSON) (per J. H. TARGETT), hour-glass constriction of sac of femoral hernia 59

LIPOMA of breast, saponifying necrosis in (J. H. Targett) . . 248
„ of thigh, saponifying necrosis in (S. G. Shattock) . . . 246
„ diffuse, producing macrodactyly (R. Jones) . . . 252

LIVER, cystic epithelioma of (A. F. Voelcker) . . . 43
„ fatty patches in (F. P. Weber) 65
„ loose body on surface of (H. D. Rolleston) . . . 68
„ perihepatitis with thrombosis (F. Willcocks) . . . 67
„ relation of biliary calculi to malignant disease of (C. F. Beadles) . 69
„ tuberculous, with lardaceous disease (Hugh Walsham) . . 65

LOCKWOOD (C. B.), pedunculated cysts within hernial sac . . 61

LOOSE BODIES from a subdeltoid bursa (Jackson Clarke) . . 257
— in depression on convex surface of liver (H. D. Rolleston) . . 68

LUNN (J. R.), aneurysm of inferior thyroid artery . . . 30

LYMPH-SCROTUM (Johnson Smith) 145

LYMPHANGIOMA CAVERNOSUM of parotid region (H. B. Robinson) . 255

LYMPHATIC GLANDS, syphilitic lesions of (Jackson Clarke) . . 257

LYMPHO-SARCOMA. See *Sarcoma.*

MACKENZIE (H. W.), rupture of bronchus 5

MACRODACTYLY due to diffuse lipoma (R. Jones) . . . 252

MADURA DISEASE, streptothrix from (C. G. Seligmann) . . 379

MALCOLM (J. D.), sarcoma of kidney 119

MALFORMATION of œsophagus (Bilton Pollard) . . . 36

MALIGNANT GROWTH from ischio-rectal region of a fox terrier (C. S. Wallace) 290
„ of tonsil (Lennox Browne) 34

MAMMARY GLAND. See *Breast.*

MARRIOTT (C. H.) (per J. H. TARGETT), acute tuberculosis of spleen; splenectomy 96

MARSH (HOWARD), remarks in discussion on non-suppurative ankylosis of joints 203

MASTITIS, chronic, with fatty concretions in breast (W. Watkins-Pitchford) 249

MICRO-ORGANISMS. See *Bacilli, Streptococcus pyogenes bovis, Streptothrix Maduræ, Pyogenic organisms, Hæmatozoon.*

MISCELLANEOUS COMMUNICATIONS 312

PAGE

MOORE (NORMAN), an undescribed form of hæmatozoon . . 384
MORBID GROWTHS 246
MORGAN (J. H.), carcinoma (?) of spermatic cord . . . 150
„ *Report* of Morbid Growths Committee on the above (W. G. Spencer and J. H. Targett) 152
MORISON (RUTHERFORD) (per J. H. TARGETT), duct-cancer of the breast . 288
MORTON (CHARLES A.), remarks in discussion on non-suppurative ankylosis of joints 213
MUCOUS CASTS of colon (P. H. Pye-Smith) . . . 52
MUSCLES, abdominal, congenital deficiency of (L. Guthrie) . . 139

NECROSIS, saponifying, in lipoma of breast (J. H. Targett) . . 248
„ — — of thigh (S. G. Shattock) 246
NEPHRITIS. See *Kidney*.
NERVOUS SYSTEM, diseases, &c., of 1

OBLITERATION of coronary artery (F. Parkes Weber) . . 16
OCCLUSION of œsophagus (Bilton Pollard) 36
ŒSOPHAGUS, dilatation of (H. D. Rolleston) . . . 37
„ diphtheria of (E. W. Goodall) 39
„ epithelioma of (J. H. Targett) 41
„ — (A. F. Voelcker) 43
„ — in pouch of (G. N. Pitt) 44
„ occlusion of (Bilton Pollard) 36
„ sarcoma of (Cyril Ogle) 40
„ *Report* of Morbid Growths Committee on above (W. G. Spencer and J. H. Targett) 41
OGLE (Cyril), accessory thyroid body 224
„ aneurysm or gumma of heart 23
„ atresia of pulmonary artery 28
„ cardiac aneurysm 22
„ embolism of coronary artery 29
„ hæmorrhage near pancreas with fat necrosis . . . 98
„ polypoid growth of the trachea 6
„ *Report* of Morbid Growths Committee on the above (A. A. Bowlby and R. G. Hebb) 7
„ sarcoma of œsophagus 40
„ *Report* of Morbid Growths Committee on the above (W. G. Spencer and J. H. Targett) 41
OLD INJURY of humerus from Egyptian mummy (J. H. Targett) . 174
ORCHITIS, diffuse syphilitic (H. B. Robinson) . . . 146
ORD (W. W.). See *Plowright* (C. B.) (spontaneous fracture of calculi) . 132
ORGANS, genito-urinary, diseases, &c., of 113
„ of circulation 14
„ of digestion 34
„ of locomotion, diseases, &c., of 174
„ of respiration 5
OSTEITIS DEFORMANS (F. J. Fielder) 190
OSTEO-ARTHROPATHY, hypertrophic pulmonary, pathology of (W. Thorburn and F. H. Westmacott) 177

PAGE

OSTEOMATA of scalp (Sydney Jones) 255
OXALIC ACID, acute nephritis from poisoning by (Hale White) . 312

PANCREAS, hæmorrhage near, with fat necrosis (Cyril Ogle) . . 98
„ oxalate calculi from cyst of (S. G. Shattock) . . . 101
PAROTID REGION, lymphangioma cavernosum of (H. B. Robinson) . 255
PERFORATION of ileum from tuberculous ulceration (Hugh Walsham) . 47
PERIHEPATITIS and thrombosis of inferior vena cava (F. Willcocks) . 67
PETERS (E. A.), diphtheria and pseudo-diphtheria bacilli . . 345
PITT (G. NEWTON), atrophy of kidney from stricture of ureter . . 113
„ epithelioma in an œsophageal pouch 44
PLOWRIGHT (C. B.) (per W. M. ORD), spontaneous fracture of uric acid calculi 132
PNEUMONOMYCOSIS (C. J. Arkle and F. Hinds) . . . 8
POISONING by oxalic acid, acute nephritis from (Hale White) . . 312
„ by sulphonal, excess of hæmatoporphyrin in the urine from (A. E. Garrod and F. G. Hopkins) 316
POLLARD (BILTON), congenital occlusion of the œsophagus . . 36
„ diverticulum ilei of unusual length and position . . . 47
POLYPUS, multiple, of stomach and intestines (W. Collier) . . 46
„ of the trachea (Cyril Ogle) 6
POWER (D'ARCY), remarks in discussion on non-suppurative ankylosis of joints 211
„ sarcoma of vagina in child 169
„ See *Jones* (R.) (macrodactyly) 252
PROSTATE, carcinoma of (R. G. Hebb) 154
„ glandular enlargement of; castration for (N. Davies-Colley) . 152
PSAMMOMA of the dura mater (J. H. Targett) . . . 3
PYE-SMITH (P. H.), mucous casts and carcinoma of colon . . 52
„ syphilitic disease of ascending aorta and valves . . . 26
PYOGENIC MICRO-ORGANISMS causing extensive hæmorrhages (Raymond Johnson) 382

RADICAL CURE OF HERNIA, results of (J. Berry) . . 56
„ — (H. T. Butlin) 54
„ — (C. H. Golding-Bird) 56
RESPIRATION, organs of, diseases, &c. of 5
ROBINSON (H. B.), cystic disease of both breasts with carcinoma in right breast 285
„ diffuse syphilitic orchitis 146
„ lymphangioma cavernosum of parotid region . . . 255
RODENT ULCER or adenoma of sebaceous glands (H. D. Rolleston) . 242
ROLLESTON (H. D.), adenoma (?) of sebaceous glands . . 242
„ carcinoma of the mamma associated with a large cyst . . 284
„ crateriform ulcer of face 240
„ loose body in depression on convex surface of liver . . 68
„ sarcoma of mamma containing multinuclear giant-cells . . 267
„ secondary sarcomatous growth in the mamma . . . 272

ROLLESTON (H. D.) (*continued*)— PAGE
„ simple dilatation of the œsophagus 37
„ simultaneous squamous-celled carcinomata . . . 241

RUNDLE (H.) (per J. H. TARGETT), epithelioma of ureter causing hydronephrosis 128

RUPTURE of inner coat of abdominal aorta (A. F. Voelcker) . . 33
„ of bronchus (H. W. Mackenzie) 5

SAPONIFYING NECROSIS in lipoma of breast (J. H. Targett) . 248
„ — of thigh (S. G. Shattock) 246

SARCOMA, round-celled, its non-existence as a distinct class of new growths (Herbert Snow) 259
„ of the bladder (J. H. Targett) 291
„ of breast containing multinuclear giant-cells (H. D. Rolleston) . 267
„ metastatic (?), of both breasts, containing multinuclear giant-cells (E. L. Fox) 269
„ metastatic or secondary, of breast (H. D. Rolleston) . . 272
„ chondrifying, of the humerus following upon a fracture (S. G. Shattock) 261
„ of hilum of kidney, bilateral (T. Fisher) . . . 115
„ of kidney (F. P. Weber) 117
„ — (J. D. Malcolm) 119
„ of the œsophagus (Cyril Ogle) 40
„ *Report* of Morbid Growths Committee on above (W. G. Spencer and J. H. Targett) 41
„ of vagina in child (D'Arcy Power) 169

SCALP, osteomata of (Sydney Jones) 255

SCROTUM, case of lymph-scrotum (Johnson Smith) . . . 145

SEBACEOUS GLANDS, adenoma (?) of (H. D. Rolleston) . . 242

SELIGMANN (C. G.) (per S. G. SHATTOCK), the Streptothrix Madurse . 379

SEPARATION OF EPIPHYSIS of great trochanter (J. Hutchinson, jun.) 174

SHARP (H. C.) (per J. H. TARGETT), primary colloid carcinoma of bladder 168

SHATTOCK (S. G.), calculi of calcium oxalate from cyst of pancreas . 101
„ chondrifying sarcoma of the humerus following upon a fracture . 261
„ cultural variation in Streptococcus pyogenes bovis . . . 375
„ healing of incisions in vegetable tissues 387
„ multiple exogenous adenomata of thyroid body . . . 231
„ saponifying necrosis in lipoma of thigh 246
„ *Report* on Mr. Barker's recurrent growth of accessory thyroid body . 229
„ See *Seligmann* (C. G.) (streptothrix Madurse) . . . 379
„ See *Watkins-Pitchford* (W.) (fatty concretions in chronic mastitis) . 249

SIMULTANEOUS SQUAMOUS-CELLED CARCINOMATA (H. D. Rolleston) 241

SKIN, diseases, &c., of 240

SMITH (JOHNSON), lymph-scrotum 145

SNOW (HERBERT), the non-existence of round-celled sarcoma as a distinct class of new growths 259

SPENCER (W. G.), *Report* on Dr. Cyril Ogle's sarcoma of œsophagus . 41
„ — on Mr. Morgan's malignant tumour of spermatic cord . . 152

SPERMATIC CORD, carcinoma (?) of (J. H. Morgan) . . . 150
„ *Report* of Morbid Growths Committee on above (W. G. Spencer and J. H. Targett) 152

PAGE

SPLEEN, acute tuberculosis of; splenectomy (C. H. Marriott) . . 96

SPLENECTOMY for acute tuberculosis of spleen (C. H. Marriott) . 96

SPRENT (W. S.) (per J. H. TARGETT), carcinomatous cyst of the breast . 277

STENOSIS of coronary artery (F. Parkes Weber) . . . 18
„ of pulmonary orifice of heart (Hugh Walsham) . . . 25

STEPHENS (J. W.) and KANTHACK (A. A.), the escape of diphtheria bacilli into the blood and tissues 361

STOMACH, dilatation of (R. G. Hebb) 45
„ polypus of (W. Collier) 46

STREPTOCOCCUS PYOGENES BOVIS, cultural variation in (S. G. Shattock) 375

STREPTOTHRIX MADURÆ (C. G. Seligmann) . . . 379

STRICTURE of ureter, atrophy of kidney from (G. N. Pitt) . . 113

SULPHONAL, excess of hæmatoporphyrin in the urine from taking (A. G. Garrod and F. G. Hopkins) 316

SUPRA-RENAL. See *Adrenal.*

SYMONDS (CHARTERS J.), three cases of carcinomatous cyst of the breast . 273

SYPHILIS of ascending aorta (P. H. Pye-Smith) . . . 26
„ of the brain (C. F. Beadles) 1
„ of lymphatic glands (Jackson Clarke) 257
„ diffuse interstitial orchitis (H. B. Robinson) . . . 146

TARGETT (J. H.), adrenal tumours of kidney . . . 122
„ diverticula of bladder associated with vesical growths . . 155
„ malignant ulceration (epitheliomatous) of the œsophagus . . 41
„ old injury of humerus from Egyptian mummy . . . 174
„ psammoma of dura mater 3
„ remarks in discussion on non-suppurative ankylosis of joints . . 216
„ saponifying necrosis in lipoma of breast 248
„ sarcomata of the bladder and their classification . . . 291
„ *Report* on Dr. Cyril Ogle's sarcoma of œsophagus . . 41
„ — on Mr. Morgan's malignant tumour of the spermatic cord . 152
„ See *Laurie* (M.) (hour-glass constriction of sac of femoral hernia) . 59
„ — *Marriott* (C. H.) (acute tuberculosis of spleen) . . 96
„ — *Fisher* (T.) (thrombosis of renal veins in nephritis) . . 113
„ — — (bilateral sarcoma of kidney) 115
„ — *Rundle* (H.) (epithelioma of ureter) 128
„ — *Sharp* (H. C.) (colloid carcinoma of bladder) . . . 168
„ — *Fielder* (F. J.) (osteitis deformans) 190
„ — *Fox* (E. L.) (metastatic sarcomata of breasts) . . . 269
„ — *Sprent* (W. S.) (carcinomatous cyst of breast) . . . 277
„ — *Morison* (R.) (hæmorrhagic duct-cancer of breast) . . 288

TESTIS, dermoid tumour of (J. J. Clarke) 148
„ diffuse syphilitic orchitis (H. B. Robinson) . . . 146

THIGH, saponifying necrosis in lipoma of (S. G. Shattock) . . 246

THORBURN (W.) and WESTMACOTT (F. H.), pathology of hypertrophic pulmonary osteo-arthropathy 177

THROMBOSIS of coronary artery (F. Parkes Weber) . . 14
„ of inferior vena cava with peribepatitis (F. Willcocks) . . 67
„ of renal veins and inferior vena cava in nephritis (T. Fisher) . 113

PAGE

THYROID BODY, accessory (Cyril Ogle) 224
„ — cystic (W. Edmunds) 223
„ — recurrent growth of (A. E. Barker) 225
„ — *Report* on above by Morbid Growths Committee (J. Berry, A. A. Bowlby, and S. G. Shattock) 229
„ multiple exogeneus adenomata of (S. G. Shattock) . . . 231
„ observations on pathology of Graves's disease (W. Edmunds) . 235
„ transformation of solid adenomata into cysts (J. Berry) . . 234

TONSIL, epithelioma of (Lennox Browne) 34

TRACHEA invaded by epithelioma of œsophagus (A. F. Voelcker) . 43
„ polypus of (Cyril Ogle) 6
„ *Report* of Morbid Growths Committee on above (A. A. Bowlby and R. G. Hebb) 7

TROCHANTER. See *Great trochanter.*

TUBERCULOSIS [and TUBERCLE], acute, of spleen; splenectomy (C. H. Marriott) 96
„ caseous mass attached to cæcum (Hugh Walsham) . . . 48
„ of liver with lardaceous disease (Hugh Walsham) . . . 65
„ ulceration of ileum with perforation (Hugh Walsham) . . 47

TYSON (W. J.), vermiform appendix containing a concretion . . 51

ULCERATION of colon in enteric fever (A. F. Voelcker) . . 54
„ crateriform, of face (H. D. Rolleston) 240
„ malignant, of the œsophagus (J. H. Targett) . . . 41
„ tuberculous, of ileum with perforation (Hugh Walsham) . . 47

ULCERATIVE APPENDICITIS, three cases of (W. Hunter) . . 49

URETER, epithelioma of (H. Rundle) 128
„ stricture of, causing atrophy of kidney (G. N. Pitt) . . 113

URIC ACID CALCULI, spontaneous fracture of (C. B. Plowright) . 132

URINE, excess of hæmatoporphyrin in, from taking sulphonal (A. E. Garrod and F. G. Hopkins) 316

UTERUS UNICORNIS with misplaced kidney (A. F. Voelcker) . 173

VAGINA, sarcoma of, in a child (D'Arcy Power) . . . 169

VARIATION in culture of *Streptococcus pyogenes bovis* (S. G. Shattock) . 375

VEGETABLE TISSUES, healing of incisions in (S. G. Shattock) . 387

VEINS, renal, thrombosis of, in nephritis (T. Fisher) . . . 113

VENA CAVA, inferior, thrombosis of (F. Willcocks) . . . 67
„ — thrombosis of, in nephritis (T. Fisher) . . . 113

VERMIFORM APPENDIX. See *Appendix cæci.*

VESICAL GROWTHS. See *Bladder.*

VOELCKER (A. F.), epithelioma of œsophagus invading trachea . . 43
„ rupture of inner coat of abdominal aorta . . . 33
„ ulceration of colon in enteric fever 54
„ uterus unicornis with misplaced kidney 173

WALLACE (C. S.), malignant tumour from ischio-rectal region of a fox terrier 290

WALSHAM (HUGH), caseous mass attached to cæcum . . . 48
„ diverticulum ilei attached to mesentery . . . 48
„ stenosis of pulmonary orifice of heart 25
„ tuberculous ulceration of ileum with perforation . . . 47
„ — liver with lardaceous disease 65

PAGE

WATKINS-PITCHFORD (W.) (per S. G. SHATTOCK), fatty concretions in breast affected with chronic mastitis 249

WEBER (F. PARKES), circumscribed fatty patches in liver . . 65
„ lympho-sarcoma of kidney of child 117
„ obliteration of coronary artery of heart 16
„ stenosis of coronary artery; angina pectoris . . . 18
„ thrombosis of coronary artery; angina pectoris . . . 14

WESTMACOTT (F. H.) and THORBURN (W.), pathology of hypertrophic pulmonary osteo-arthropathy 177

WHITE (W. HALE), acute nephritis due to oxalic acid poisoning . . 312

WILLCOCKS (F.), perihepatitis with thrombosis of inferior vena cava . 67

XEROSIS CONJUNCTIVÆ, bacillus of (J. Eyre) . . . 334

PRINTED BY ADLARD AND SON, BARTHOLOMEW CLOSE, LONDON, E.C.